

How to Cite:

Pal, B., Goyal, P., & Bajwa, A. (2021). Prosthodontic rehabilitation using broadrick flag: A case report. *International Journal of Health Sciences*, 5(S2), 205–213.
<https://doi.org/10.53730/ijhs.v5nS2.5634>

Prosthodontic rehabilitation using broadrick flag: A case report

Bhupinder Pal

Reader, Dept of Prosthodontics, Desh Bhagat Dental College & Hospital, Gobindgarh

Priyanka Goyal

Senior lecturer, Dept of Pedodontics, Desh Bhagat Dental College & Hospital, Gobindgarh

Avrinder Bajwa

Lecturer, Dept. of Prosthodontics and Crown & Bridge, Desh Bhagat Dental College and Hospital, Mandi Gobindgarh

Abstract---In procedures involving fixed prosthodontics, when it has been established that restoration of some or all of the posterior teeth is necessary, the use of the Broadrick occlusal plane analyzer has proven to be an easy, predictable and practical method to determine an occlusal plane that will fulfill functional and esthetic occlusal requirements. Unfortunately, most semi adjustable articulator manufacturers do not offer any such occlusal plane analyzers which could be used with these instruments. This article is an attempt to highlight the use of a customized Broadrick Occlusal Plane Analyzer using the Hanau H2 semi adjustable articulator to establish and determine the correct Curve of Spee for the given occlusal plane.

Keywords---curve of spee, occlusal plane, broadrick occlusal plane analyzer.

Introduction

To define occlusal plane, it is the average plane established by the incisal and occlusal surfaces of the teeth. Generally, it is not a plane but represents the planar mean of the curvature of these surfaces¹. The curve of Spee refers to the anatomic curve established by the occlusal alignment of the teeth, as projected onto the median plane, beginning with the cusp tip of the mandibular canine and following the buccal cusp tips of the premolar and molar teeth, continuing through the anterior border of the mandibular ramus, ending with the anterior

most portion of the mandibular condyle¹. Originally described by Ferdinand Graf Spee in 1890. The curve of Spee is designed to permit protrusive disocclusion of the posterior teeth by the combination of anterior guidance and condylar guidance. As the angle of condylar guidance is greater than the curve of Spee, posterior disocclusion is achieved². Posterior disocclusion during protrusion results in more efficient incisive function as the anterior teeth slide past each other to the overlapped relationship that makes a shearing action possible². To reduce excess stress on to the anterior teeth, correct occlusal plane is advocated, if not, abnormal activity in mandibular elevator muscles, especially the masseter and temporalis muscles³ and real possibility of eventual damage to the teeth, the joints, and the periodontal structure.

The 3 most commonly used methods for establishing an acceptable plane of occlusion are direct analysis on natural teeth through selective grinding, indirect analysis of face bow mounted casts with properly set condylar paths, and indirect analysis using the Pankey- Mann-Schuyler (PMS) method with the Broadrick occlusal plane analyzer (BOPA)². An occlusal plane analyzer has long been used to assist the operator in the development of an initial mandibular occlusal plane in diagnostic contour casts and later as an integral part of both the contours of the definitive restorations and the guidelines for the actual tooth preparations⁴. The BOPA can be adapted to only a few articulator systems, such as the Denar Anamark Fossae (Teledyne Waterpik, Ft Collins, Colo) and all models of Hanau articulators (Teledyne Waterpik)^{5, 6}.

Clinical report

A 45-year-old female reported to the Department of Prosthodontics, Krishnadevaraya College of Dental Sciences, Bangalore, Karnataka, India with a chief complaint of inability to chew food due to multiple missing teeth in the oral cavity. Detailed case history was recorded and no significant medical concerns were observed. Radiographic examination of the patient using Orthopantogram revealed poor quality of the bone in the posterior region bilaterally both in the maxilla and in the mandible (Fig. 1).

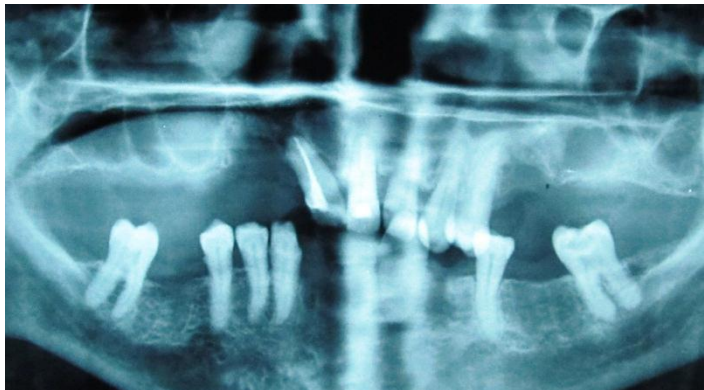


Fig 1. Orthopantogram

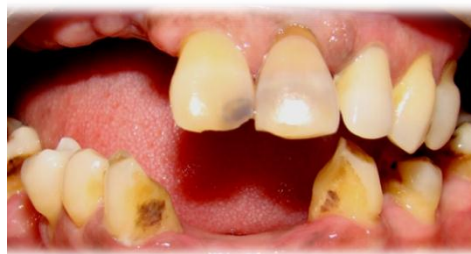Diagnostic impressions of maxillary and mandible teeth were made using irreversible hydrocolloid impression material (Tropicalgin) and casts were poured

in type III dental stone (Kalstone; Kalabhai Karson Pvt Ltd, Mumbai, India). These diagnostic casts were then mounted on a semi adjustable articulator (Hanau H2) using face bow transfer records.

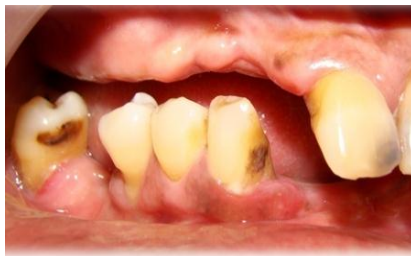Intra oral clinical examination (Fig.2 A,B,C) and diagnostic mounting (Fig.3A,B) confirmed occlusal plane correction is needed on both right and left side of oral cavity. On right side, in maxillary arch 12,13,14,15,16,17,18 and in the mandibular arch 41,42,46,48 were missing (Fig.3A). On the left side, in maxillary arch 25,26,27,28 and in mandibular arch 31, 32,34,36,38 (Fig. 3 B).Marked discrepancy of the occlusal plane was noted bilaterally in the mandibular arch and therefore the need to establish a new plane of occlusion was indicated with conventional fixed restorations. Implant option was ruled out bilaterally in the posterior region both in the maxillary and mandible arches due to poor quality of available bone as seen on the Orthopantomogram (Fig.1) and patient refusal to undergo extensive surgery like bone grafting.

It was noted that the remaining natural teeth in the maxilla were proclined excessively and discolored. Keeping the esthetics in mind, it was decided to do root canal treatment and restore them with fixed restorations with precision attachments to the distal most abutments so as to be used for the removable cast partial denture for the present Kennedy's class I condition.

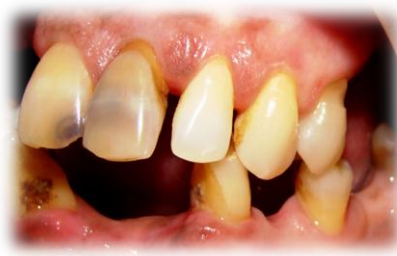In the mandible quality of the bone segment in the anterior region was found to be good and following discussion with the patient it was decided to restore the anterior edentulous area with implant supported fixed prosthesis.



A) Frontal view

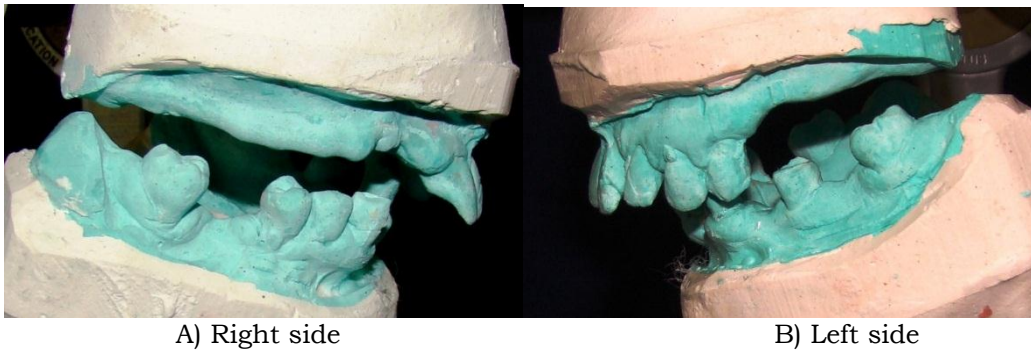


B) Right lateral view



C) Left lateral view

Fig 2. Intra-oral clinical images



A) Right side
B) Left side
Fig 3. Mounted diagnostic casts. Marked discrepancy was evident in level of occlusal plane

It was decided to use the Broadrick occlusal plane analyzer to establish a new occlusal plane. Since no such flag/analyzer was supplied by the manufacturer, a custom-made flag/BOPA was fabricated using a 3-mm-thick acrylic resin sheet (4 inch x 4 inch), which fit into a slot of the same dimensions in a acrylic resin base, attached to the upper member of the articulator. A sheet of plain white paper was attached to both sides of the flag to receive the markings. The maxillary cast was removed from the articulator, and the flag was attached on top of the upper member of the articulator.

The anterior survey point (ASP) was chosen on the midpoint of the disto-incisal edge of the mandibular right canine from which a long arc with a 4-inch radius was drawn on the flag with a compass⁸. As the position of the distal most mandibular molar was judged to be acceptable, the posterior survey point (PSP) was located on the distobuccal cusp of the mandibular right second molar (Fig.4 A) and a short arc of 4-inch radius was drawn on the flag to intersect the long arc at the center of the anteroposterior curve⁷. The point of intersection is called Occlusal Plane Survey Centre (OPSC) (Fig.5A). The point of the compass was placed at the OPSC, and a 4-inch radius was drawn through the buccal surfaces of the mandibular teeth to establish the anteroposterior curve (Fig.5B). The mandibular right canine, first & second premolar and second molar were slightly extruded (Fig.6A). The same procedure was followed on the left side (Fig.4B). The mandibular left canine and disto-buccal cusp of the mandibular second molar was extruded. The second premolar was below the level of the curve (Fig.6B).

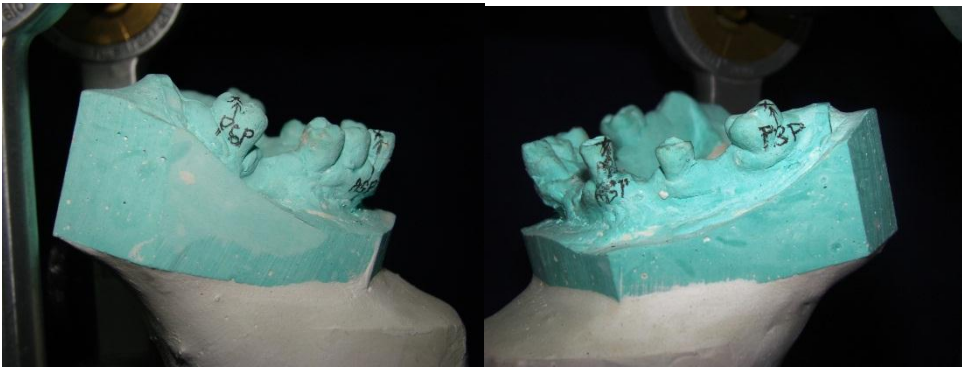


Fig. 4 A, On right side, the anterior survey point (ASP) was chosen on the midpoint of the disto-incisal edge of the mandibular right canine and the posterior survey point (PSP) was located on the distobuccal cusp of the second molar tooth. B, On left side, the anterior survey point (ASP) was chosen on the midpoint of the disto-incisal edge of the mandibular left canine and the posterior survey point (PSP) was located on the distobuccal cusp of the second molar tooth.




Fig. 5 A Short arc of 4-inch radius was drawn from PSP on flag to intersect long arc at centre of curve of Spee. B, Point of compass was placed at centre of flag, and 4-inch radius was drawn through buccal surfaces of mandibular teeth

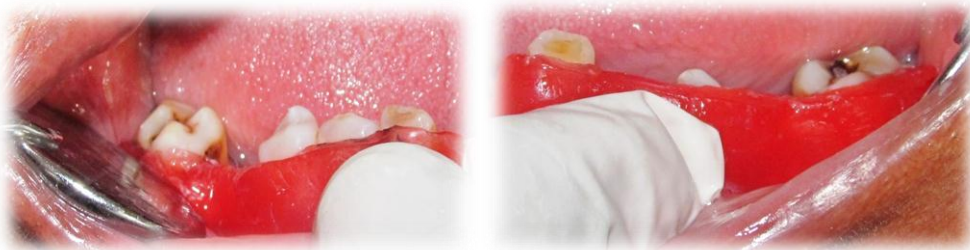

Fig.6A. The mandibular right canine, first & second premolar and second molar were slightly extruded B The mandibular left canine and disto-buccal cusp of the mandibular second molar was extruded. The second premolar was below the level of the curve

Another line, termed the “preparation line”, was scribed by opening the compass by an amount equal to the desired occlusal thickness of the proposed restoration. A softened modelling wax sheet (Modelling wax; Deepti Dental Products of India Pvt Ltd, Ratnagiri, Maharashtra, India) was adapted to the buccal surfaces of the mandibular cast (Fig.7). The wax was cut carefully back to this line and trimmed along the mucobuccal fold so that the wax could be fitted accurately against the teeth intraorally, and this was termed the “occlusal plane cutting guide” (Fig.8A,B)



Fig 7. Occlusal Plane Cutting Guide



A) Right side

B) Left side

Fig 8. Occlusal Plane Cutting Guide

The decision was made to restore the entire mandibular arch and maxillary arch with fixed restorations except for the maxillary left and right posterior region, for which a removable cast partial denture was planned along with precision attachment. The occlusal scheme was planned as a group function occlusion. All pre restorative treatment was completed. When preparing the mandible posterior teeth, the cutting guide was placed snugly against the buccal surfaces of the dried teeth, and the entire occlusal surface of each tooth was reduced to the preparation line (Fig.8 A, B). Preparations were located sufficiently more apically on the lingual surfaces than on the buccal to accommodate for the mediolateral curve. Following occlusal reduction, the teeth were prepared according to the predetermined treatment plan. Impressions were made and final restorations were fabricated in the traditional manner. The same procedure that was used for determining the occlusal plane was used effectively to establish the correct occlusal plane on the final restoration (Fig.9A,B). The bisque try in was done on the patient and premature contacts and excursive interferences were assessed clinically and the same were eliminated. All this was done after cementation of the fixed upper restoration and with the removable cast partial denture in position. This was sent back to the laboratory for final finishing and glazing procedure. The finished fixed prosthesis was then cemented and the patient expressed satisfaction with the end result (Fig10A,B,C). Thus, through use of BOPA and a semiadjustable articulator, it was possible to create an esthetic and functionally correct occlusal plane.

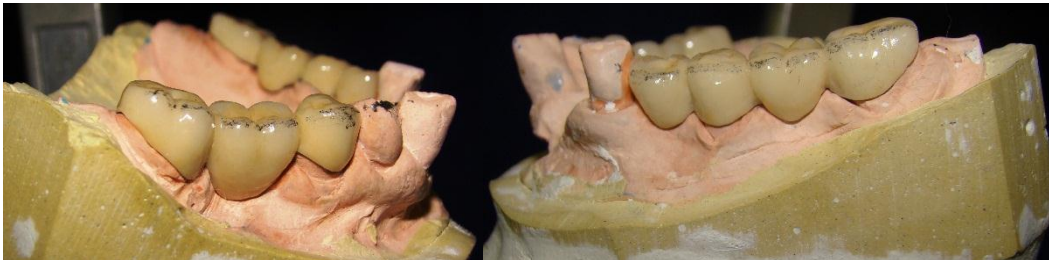
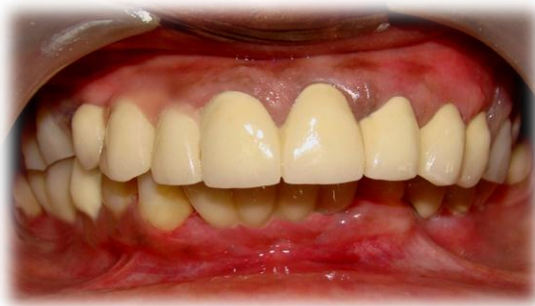
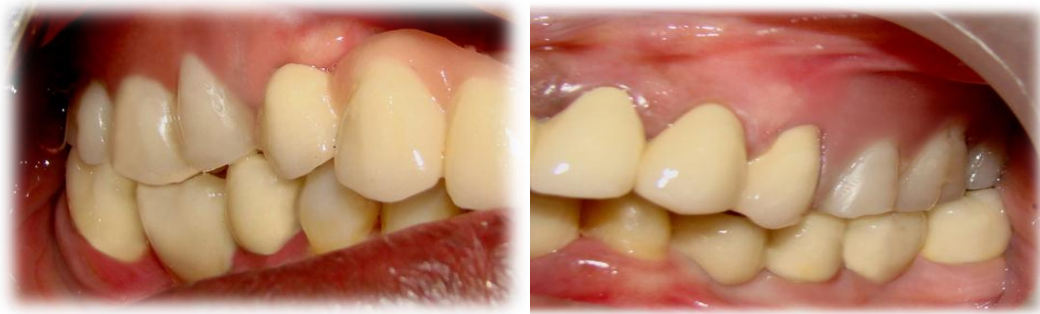Fig 9. Occlusal plane analysis on final restoration. A, On Right side. B, On Left side .



A) Frontal view



B) Right lateral view

C) Left lateral view

Fig 10. Definitive restorations

Discussion

It is not usually noted that while Spee described a curve of approximately 2.5-inch radius, Monson⁹ proposed the now widely accepted curve of 4-inch radius. Spee noted that it would be possible to locate the centre of the curvature “by reconstruction and measurement with the compass.” Esthetics and functional occlusal plane can be achieved by altering the length of the radius of the curve. A 3.75-inch radius may be indicated for a class II skeletal relationship, while a 5-inch radius may be indicated for a class III skeletal relationship⁸. The centre of the curve may also be moved in an anterior or posterior direction from the intersection of the arcs, but should always lie along the arc drawn from the anterior survey point (ASP). To ensure posterior disocclusion on mandibular protrusion, the curve should extend through the condyle. When the posterior survey point (PSP) on the distal molar tooth is not suitable, anterior border of the condyle, represented by the most anterior point on the condylar element on the articulator represents the PSP⁸. Care should be taken to ensure that the angle of the condylar guidance is not less than the curve of Spee, as this would introduce posterior protrusive interferences. Careful restoration design to ensure proper anterior guidance will prevent the introduction of Hyperactivity in the temporalis and masseter muscles, wear, fracture of restorations, and temporomandibular joint dysfunction.

Conclusion

As Broadrick flag locates the center of the curve of Spee, extensive restorations can be designed to permit mandibular excursions free from posterior interferences. Proper planning, diagnostic wax-up and the waxup duplicated provisional restorations enhance the predictability of a successful result. High-quality restorations in harmony with the anterior and condylar guidance create an esthetic and functionally correct occlusal plane.

References

1. The glossary of prosthodontic terms. 8th ed. J Prosthet Dent 2005; 94:10-92.
2. Dawson PE. Evaluation, diagnosis and treatment of occlusal problems. 2nd ed. St Louis: Elsevier; 1989. p. 85, 373-81.

3. Williamson EH, Lundquist DO. Anterior guidance: its effect on electromyographic activity of the temporal and masseter muscles. *J Prosthet Dent* 1983; 49:816-23.
4. Becker CM, Kaiser DA. Evolution of occlusion and occlusal instruments. *J Prosthodont* 1993; 2:33-43.
5. Toothaker RW, Graves AR. Custom adaptation of an occlusal plane analyzer to a semi-adjustable articulator. *J Prosthet Dent* 1999; 81:240-2.
6. Small BW. Occlusal plane analysis using the Broadrick flag. *Gen Dent* 2005; 53:250-2.
7. Bowley JF, Stockstill JW, Attanasio R. A preliminary diagnostic and treatment protocol. *Dent Clin North Am* 1992; 36:551-68.
8. Lynch CD, McConnell RJ. Prosthodontic management of the curve of Spee: Use of the Broadrick flag. *J Prosthet Dent* 2002; 87:593-7.
9. Spee FG, Biedenbach MA, Hotz M, Hitchcock HP. The gliding path of the mandible along the skull. *J Am Dent Assoc* 1980; 100:670-5.