

**How to Cite:**

Jain, N., & Soni, S. (2021). An overview of class II division 2 malocclusion. *International Journal of Health Sciences*, 5(S2), 214–221. <https://doi.org/10.53730/ijhs.v5nS2.5635>

# An overview of class II division 2 malocclusion

**Navisha Jain**

PG Student (1<sup>st</sup> year), Department of Department of orthodontics & dentofacial Orthopaedics, Desh Bhagat Dental College & Hospital, Mandi Gobindgarh

**Sanjeev Soni**

Professor & Head, Department of Department of orthodontics & dentofacial Orthopaedics, Desh Bhagat Dental College & Hospital, Mandi Gobindgarh

**Abstract**---Class II malocclusion is the condition in which the mandibular first molars occlude distal to the normal relationship with the maxillary first molar. The etiology of class II malocclusion varied between skeletal, soft tissues, dental factors and habits. Skeletal class II could be because of protrusion of maxilla, retrusion of mandible and combination of both. The treatment modalities of any skeletal problem include growth modification, dental camouflage and orthognathic surgery. This article elaborates the etiology, clinical features, treatment objectives, orthodontic corrections, retention for class II division 2 malocclusion.

**Keywords**---retention, skeletal malocclusion, retroclination, etiology.

**Introduction**

In 1899, angle<sup>1</sup> defined class II division 2 malocclusion as the presence of a class II molar. Relationship and retroclined maxillary central incisors. The maxillary lateral incisors may be either proclined or normally inclined. Years later, van der linden<sup>2</sup> further classified the class II division 2 malocclusion into the following three types:

- Type A, in which the maxillary central and lateral incisors are retroclined but the retroclination is not severe
- Type B, in which maxillary lateral incisors overlap with the retroclined maxillary central incisors
- Type C, in which the maxillary central and lateral incisors are retroclined and overlap with the maxillary canines.

Appliance selection for treatment of class II cases includes orthodontic camouflage, removable or fixed functional appliances according to the existing

anteroposterior discrepancy, cooperation and growth period of the patient and surgical treatment in severe discrepancy cases. Nongrowing patients with class II mandibular retrusion are mostly treated with fixed functional appliances which do not require the patient's collaboration.<sup>3,4,5</sup>

### **Etiology**

Although the etiology of class II division 2 malocclusion remains unclear, many theories have been proposed. Some authors suggested that this type of malocclusion results from a lack of mandibular development or distal positioning of the mandible in relation to the cranial base. Others believed that the main cause is dentoalveolar rather than skeletal origin. In Pancherz et al.,<sup>6</sup> a cephalometric radiographic study in children revealed that dentoskeletal morphology did not significantly differ between class II division 2 malocclusions and class II division 1 malocclusions. Some clinicians had suggested that the lips act as a local genetic factor in class II division 2 malocclusion and that maxillary incisor retroclination results from excessive non-physiological pressure between the lip and teeth. Fletcher<sup>7</sup> found that the lower lip guided the maxillary incisors into a retroclined position if the maxillary incisors were not obstructed by the digits, tongue or the other teeth in either arch. In the study of Lapatki et al.,<sup>8</sup> the activity shown in perioral electromyography indicated that the local epigenetic factors had an important role in the development of imbalanced vertical relationship between the lips and the maxillary anterior dentoalveolar structures.

### **Clinical features**

Most class II division 2 malocclusions result from a skeletal class II jaw relationship; however, some authors suggested that many of these cases present a skeletal class I jaw relationship. Patients usually present with a hypodivergent facial pattern, which may accompany with an anterior rotation of the mandible, an overdevelopment of the inter-incisor bone, or an under-development of the maxillary posterior alveolar process. Karlson reported that the cephalograms of class II division 2 malocclusion indicated the vertical discrepancy between maxillary incisal and molar heights. Patients with class II division 2 malocclusion usually exhibit upright incisors, relatively small tooth size, discrepancies in the arch and tooth size, increased collum angle of maxillary incisors, and thin incisors with small tubercles. Soft tissues or muscle activities are believed to have a strong association with class II division 2 malocclusion.

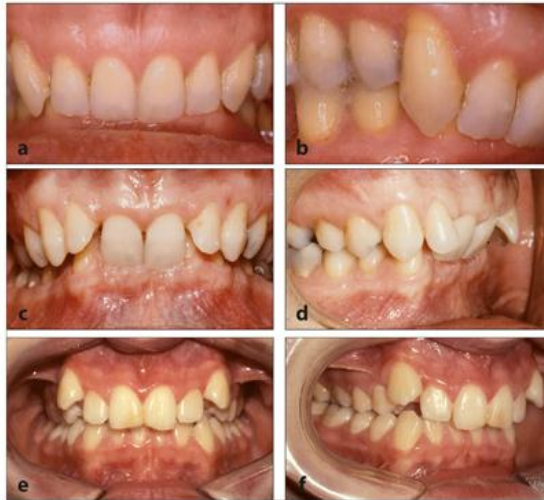

Fig 1. Class II, division 2 malocclusions. *(a and b)* Type A. With excess space in the maxillary dental arch, all four maxillary incisors can tip palatally, and the canines attain a correct position in the dental arch. *(c and d)* Type B. With limited space, the maxillary central incisors tip palatally, and the lateral incisors tip labially. *(e and f)* Type C. With marked shortage of space, the four maxillary incisors tip palatally, and the canines emerge buccally outside the dental arch.<sup>19</sup>

### Features of class II division 2 on each aspects

- Skeletal
  - Skeletal class II jaw relation
  - More often a skeletal class I relation
- Dental
  - Severe deep bite, “cover-bite”
  - Retroclination of upper incisors & lower incisors
  - Labially flared maxillary lateral incisors
  - Increase in interincisal angle
  - Deep curve of spee
- Soft tissue
  - Brachycephalic head shape
  - Deep mentolabial fold
  - Intra-oral finding
  - Gingival line malaligned
  - Impinged bite over lower anterior gingival

### Treatment objectives

The treatment objectives are the following:

1. Expansion of the dentally constricted maxillary arch
2. Protrusion of the severely retroclined upper incisors
3. Resolving the crowding of the maxillary and mandibular arch

4. Correction of severe deep bite
5. Establishing class I canine and molar relationships
6. Obtaining normal overjet and overbite
7. Improvement of the patient's facial esthetic.

### **Orthodontic correction**

Heide<sup>9</sup> inferred that occlusal interference is a possible etiology of class II division 2 malocclusion. He suggested that the treatment should begin with correcting the centric relation position of the patients. This can be accomplished by instructing the patients to open the mouth widely for an extended period of time and then slowly close the mouth until the first premature dental contact is detected. Some cases of class I molar relation may not have a true class II division 2 malocclusion. If the posterior bite reveals a cusp-to-cusp relationship, the standard procedure for correcting a typical class II division 1 malocclusion can be performed. However, if the posterior bite reveals a full class II relationship, and if a class I molar relationship could not be expected after using the inter-maxillary elastics for a period of time, extraction of the maxillary bicuspid can be considered. Extraction in the mandibular arch is not suggested because correction of overbite has a high risk of relapse. Heide<sup>9</sup> has also suggested that satisfactory results may be obtained by interdental stripping and tooth contouring, i.e., grinding of the erratic incisal edges and contact areas. Uribe and Nanda<sup>10</sup> recommended that the treatment objectives should include the chief complaint of the patient and that the mechanics of correction should be individualized for each patient and based on specific treatment goals. Orthodontists generally have difficulty to decide whether the maxillary bicuspid should be extracted. Although tooth extraction may help to relieve anterior crowding, which is common in class II division 2 malocclusion, it may also complicate the correction of anterior teeth retroclination during space closure of the tooth extraction.

The treatment goal and the range of tooth movement in different mechanics of treatment should be clearly evaluated before treatment. Preformed nickel titanium intrusion wires are used in class II division 2 malocclusion. A short wire is used in cases requiring extraction, and a long wire is used in non-extraction cases. These wires can deliver a force of 35-40 gm in patients with an average arch length and a full complement of teeth. An intrusion arch produces a labial tipping movement and intrusive forces while applying extrusive force on the molars. (fig.2) To achieve an ideal angulation in the anterior teeth, the intrusion arch wire should not be cinched back in distal end of the molar tubes initially. Thus, the incisors can be flared prior to their intrusion. The wire then could be cinched 2-3 mm distal to the molar tubes for intrusion as well as flaring of the incisors. The intrusion arch wire should first be ligated to the anterior segment between the two central incisors. This enables attachment of the wire at the most anterior point is related to the center of resistance of the incisors. Once the incisor root inclinations have been corrected, the intrusion arch wire can be ligated to the anterior segment at two lateral incisors and between the central incisors. During insertion, the wire should be bent 3-5 mm mesial to the first molar auxiliary tube. Since one of the treatment goals is to correct deep overbite in class II division 2 malocclusion, vertical control could be important in some of the cases. Even though molar extrusion could help for overbite reduction, large amount of molar

extrusion would result in mandible clockwise rotation, increase lower facial height and make chin backward in position. In these cases, anchorage should be well designed and prepared. TADs and other devices could provide anchorage in these cases to prevent further mandible clockwise rotation.

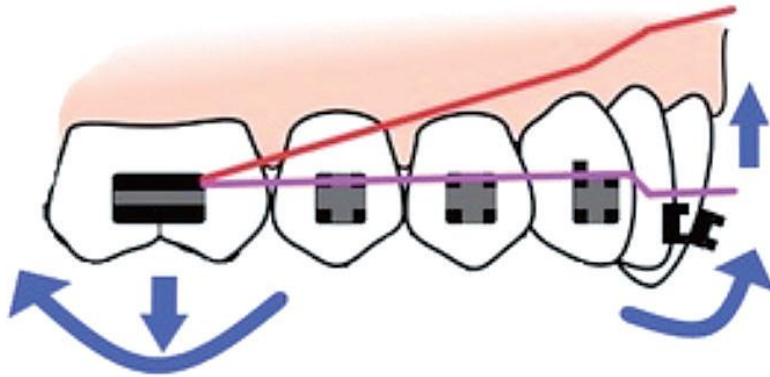


Fig 2. Intrusive arch could perform an extrusive force on molars and intrusive force on incisors that would help improve deep overbite in Class II division 2 malocclusion.

Some authors have demonstrated combined orthodontic and surgical methods to correct class II, Division 2 malocclusion in adults. Stoelting and Leenen<sup>11</sup> and Arvystas<sup>12</sup> had presented orthodontic treatments that included maxillary anterior subapical osteotomy and/or sagittal split ramus osteotomies. Anterior subapical osteotomy may help to improve deep bite and correct anterior teeth inclination. Sagittal split ramus osteotomy could provide forward mandibular movement to correct the sagittal dental or jaw bone relation. Another widely discussed issue is whether extraction of tooth is required. Different patterns of extraction therapy have been suggested, including extraction of the first four premolars, extraction of maxillary first premolars and mandibular second premolars, extraction of maxillary second molars for maxillary arch distalization, extraction of maxillary premolars with mandibular incisors, or even extraction of a single mandibular incisor. In class II division 2 cases, considerations such as crowding, molar relationships, overbite depth, retroclination of maxillary incisors, and hypodivergent facial pattern contribute to the dilemma of whether and at which site extraction therapy should be performed. Litt and Nielson<sup>13</sup> have done a study which involves comparisons of identical twins and revealed that, if one of the twins had undergone extraction of four premolars, the twin that had undergone extraction may have more mandibular forward growth rotation and more vertical molar extrusion as compared to the other twin. In adults, Tsou et al.<sup>14</sup> suggested that an initial non-extraction treatment plan could be revised to extraction therapy after reevaluating the lip profile when anterior tooth inclination is

corrected. Therefore, constant evaluation of changes in the features on the patients is necessary.

### **Retention**

Class II division 2 malocclusion is considered to be difficult to treat and is prone to relapse. A meta-analysis of 322 studies by millett et al<sup>15</sup> found that highly biased prospective and retrospective evidence apparently favored non-extraction treatment and indicate that overbite correction is reasonably stable in the short term. In growing patients, a bite-raising appliance was suggested to maintain the maxillary incisor inclination and to induce anterior mandibular growth rotation. Comparisons of various retainers indicated no effect on maxillary incisor stability at a mean of 3.5 years post treatment. However, uribe and nanda<sup>10</sup> recommended a lower bonded 3-3 retainer to ensure a stable intrusive movement. Minor overbite relapse should be expected since the correction involves some amount of posterior buccal extrusion. Therefore, some over-correction is required to achieve good long-term results in class II division 2 cases.

### **Conclusion**

Angle classification is a useful means of identifying class II malocclusions, but it oversimplifies the description of a complex pattern of skeletal, dental, and profile relationships that are present. A Class II malocclusion may be accompanied by an anteroposterior skeletal discrepancy between the maxilla and mandible, often with mandibular retrusion, however the maxilla may also be protrusive. The growth patterns in Class II individuals do not differ from the normal growth patterns. Normal faces with normal dental occlusion appear to have a combination of skeletal units that are well related to each other. On the other hand, a skeletal discrepancy may be the result of having similar skeletal units that are less favorably related to each other. However, it is generally agreed that the orthodontist should attempt to recognize, diagnose, and treat these cases during the growth period to obtain optimal results. Angle class II division 2 malocclusion includes the presence of a class II molar relationship and retroclined maxillary central incisors. The maxillary lateral incisors may be either proclined or normally inclined. Although the etiology of class II division 2 malocclusion remains unclear. Patients usually present with a hypodivergent facial pattern. Patients with class II division 2 malocclusion usually exhibit upright incisors, relatively small tooth size, discrepancies in the arch and tooth size, increased collum angle of maxillary incisors, and thin incisors with small tubercles. The treatment should begin with correcting the centric relation position of the patients. Tooth extraction may help to relieve anterior crowding, which is common in class II division 2 malocclusion, it may also complicate the correction of anterior teeth retroclination during space closure of the tooth extraction. Class II division 2 malocclusion is considered to be difficult to treat and is prone to relapse. Some over-correction is required to achieve good long-term results in class II division 2 cases. Correction of the anteroposterior and vertical dental and skeletal discrepancies is advocated for most patients in the late mixed dentition or early adolescence. This could simplify the overall treatment by taking advantage of the patient's growth potential and cooperation in wearing extraoral appliances.

Treatment is designed to redirect the growth of the maxilla and to allow the mandible to express its maximum potential.

## References

1. Angle eh. Treatment of malocclusion of the teeth and Fractures of the maxillae. In: angle's system, ed 6. Philadelphia: ss white dental mfg co ;1900.
2. Van der linden fpgm . Development of the dentition. Chicago: Quintessence Publishing Co., Inc., pp. 93–103 (1983).
3. Franchi, l. Alvetro, v. Giuntini, c. Masucci, e. Defraia, and t. Baccetti, "effectiveness of comprehensive fixed appliance treatment used with the forsus fatigue resistant device in class II patients," the angle orthodontist, vol. 81, no. 4, pp. 678–683, 2011.
4. V. F. Zymperdikas, v. Koretsi, s. N. Papageorgiou, and m. A. Papadopoulos, "treatment effects of fixed functional appliances in patients with class II malocclusion: a systematic review and meta-analysis," the european journal of orthodontics, 2015.
5. Dalci, a. T. Altuğ, and u. T. Memikoglu, "treatment effects of a twin-force bite corrector versus an activator in comparison with an untreated class II sample: a preliminary report," australian orthodontic journal, vol. 30, no. 1, pp. 45–53, 2014.
6. Pancherz H, Zieber K, Hoyer B. Cephalometric characteristics of class II division 1 and class II Division 2 malocclusions: a comparative study in children. Angle orthod 1997;67:111–120.
7. Fletcher GG. The retroclined upper incisor. Br j Orthod 1975;2:207–216.
8. Lapatki BG, mager AS, schulte-moenting J, jonas ie. The importance of the level of the lip line and resting Lip pressure in class II, division 2 malocclusion. J dent res 2002;81:323–328.
9. Heide m. Class II, division 2—a challenge. Angle Orthod 1957;27:159.
10. Uribe F, nanda. Treatment of class II, division 2 Malocclusion in adults: biomechanical considerations. J clin orthod 2003;37:599–606.
11. Stoelinga PJ, leenen RJ. Class II anomalies: a coordinated approach to the management of skeletal, Dental, and soft tissue problems. J oral surg 1981;39:827–841.
12. Arvystas mg. Treatment of severe mandibular retrusion in class II, division 2 malocclusion. Am j Orthod 1979;76:149–164. Lee kf, tseng yc, chang hp, chou st
13. Litt ra, nielsen il. Class II, division 2 malocclusion. to extract—or not extract? Angle orthod 1984;54:123–138.
14. 1984;54:123–138.
15. Tsou CH, kuo CL, liuYH, wang YY extraction or non-extraction treatment of class II division 2 malocclusion adult patients—case report. J Taiwan Assoc orthod 2014;26:114–127.
16. Pullinger AG, solberg WK, Hollender l, Petersson A, relationship of mandibular condylar position to dental occlusion factors in an asymptomatic population. Am J orthod dentofacial orthop. 1987 mar;91(3):200-6.
17. Anders CL, harzer W, eckardt L. Axiographic evaluation of mandibular mobility in children with Angle class-II/2 malocclusion (deep overbite). J orofac orthop. 2000;61(1):45-53.

18. Stamm TL, vehring A, ehmer U, bollmann F, computer-aided axiography of asymptomatic
19. Individuals with class II. *J orofac orthop.* 1998;59(4):237-45.
20. 18. Millett DT, cunningham SJ, o'brien kd, benson pe, De oliveira cm. Treatment and stability of class II Division 2 malocclusion in children and adolescents: A systematic review. *Am j orthod dentofacial orthop* 2012;142:159-169.
21. 19. Orthodontic Correction of Class II Division 2 Malocclusion. Kun-Feng Lee Department of Orthodontics, Dental Clinics, Kaohsiung Medical University Hospital, Kaohsiung Taiwan (2018).