

How to Cite:

Nayar, A. K., & Bajaj, G. (2021). Evaluation of podoplanin levels in odontogenic cysts. *International Journal of Health Sciences*, 5(S1), 441-459.
<https://doi.org/10.53730/ijhs.v5nS1.5679>

Evaluation of podoplanin levels in odontogenic cysts

Amit K Nayar

Professor & Head, Desh Bhagat Dental College & Hospital, Mandi Gobindgarh, Punjab
Email: dr.amitnayar@gmail.com

Gagan Bajaj

Senior Lecturer, Lakshmi Bai Dental College, Patiala, Punjab

Abstract---This study evaluated role of podoplanin levels in odontogenic cysts. We concluded that expression of podoplanin was significantly higher in KCOTs than in dentigerous cysts & dental follicles.

Keywords---podoplanin levels, odontogenic cysts, evaluation.

Introduction

Odontogenic cysts are relatively common lesions and account for a substantial part of total oral biopsies received by an oral pathologist. This diverse group of lesions exhibit varying presentations ranging from a small innocuous lesion (which may be detected accidentally) to highly aggressive and destructive lesions that may even cause extraoral disfigurement.¹ These lesions reflect the multiformity and complex developmental pattern of dental structures as these lesions originate through some alteration from the normal pattern of odontogenesis.² Among this above mentioned aggressive and destructive type of lesions, odontogenic keratocyst (OKC) is most commonly known for its aggressive nature. It is one of the less common odontogenic cysts which attract many researchers due to its unique characteristics. The World health organization (WHO) recognized this lesion as a cystic neoplasm in 2005 and recommended the term cystic neoplasm now known as Keratocystic Odontogenic Tumor (KCOT), as it better reflects the clinically aggressive behavior, histologically high mitotic rate, high recurrence rate, propensity for local invasion and association with genetic and chromosomal abnormalities. The KCOT is an enigmatic developmental cyst that deserves special attention. It exhibits putative high growth potential and high recurrence rate due to its nature of forming compartments within.^{1, 2}

The OKC was originally described by Philipsen in 1952. Toller, in 1967, was the first to suggest that it is a tumor and not a cyst. Hence, in this study this lesion is referred to as keratocystic odontogenic tumor (KCOT). It is defined as a benign unicystic or multicystic, intraosseous tumor of odontogenic origin, with a characteristic lining of parakeratinized stratified squamous epithelium and potentially aggressive behavior. It is most common in the 2nd and 3rd decade, and has a male predilection. Much interest was generated in this lesion after it was observed that they tend to grow to a large size before becoming clinically apparent.³

Keratocystic odontogenic tumors may behave aggressively and can penetrate cortical bone, extending into the surrounding soft tissue or into the maxillary sinuses. They are also particularly prone to recurrence, with reported local recurrence rates ranging from 13% to 60%. The recurrence rate is higher for tumors associated with Nevroid Basal Cell Carcinoma Syndrome (NBCCS) and in lesions arising from the mandible. The presence of daughter cysts is also considered to be a factor for the high recurrence rates.^{2, 3}

Another factor resulting in high recurrence rate of this lesion is its property to invade into the surrounding and underlying connective tissue. The extent of invasion can be analysed by the expression of various genes by lesional cells and their production of proteins. However, current clinical parameters cannot predict the potential for neoplastic behavior or aggressive and localized infiltration, in KCOTs. Also, to the best of our knowledge, there is no suitable immunohistochemical marker available that can be used to assess the aggressiveness of KCOT.⁴

The quest for such a marker, however, has been ongoing for some time now. Among other markers, Podoplanin has been studied in other lesions. However, its relevance in oral lesions particularly odontogenic lesions need to be assessed. Among the odontogenic cysts, second most common cyst is the Dentigerous cyst after the radicular cyst. A dentigerous cyst is one that encloses the crown of an unerrupted tooth by expansion of its follicle, and is attached to the neck of the tooth. Of great clinical significance is the fact that numerous cases of ameloblastoma, epidermoid carcinoma and mucoepidermoid carcinoma have been reported developing in the epithelial wall of dentigerous cyst. This proves the pluripotentiality of the epithelium of this cyst.⁵

Podoplanin is a 36–43-kDa mucin- like transmembrane glycoprotein that is highly and specifically expressed in lymphatic endothelial cell, but not blood vessel endothelium. Podoplanin expression has been reported in carcinomas of the skin, lung, uterus and oesophagus and is highly expressed in oral cancer some and oral premalignancies.⁶

This molecule has diverse functions, including regulation of organ development, cell mortality, tumorigenesis and metastasis. Recent studies have revealed expression of Podoplanin in some other non-endothelial tissues including odontogenic tissues like the enamel epithelia of the cervical loop of tooth germ and apical bud cell of mouse incisors at the bell stage. This molecule may also be involved in the process of local expansion of developmental, inflammatory and

neoplastic odontogenic lesions. Recent studies have correlated the Podoplanin expression with the neoplastic character as a parameter for assessment of tumors of odontogenic origin.⁷

Podoplanin which is frequently used as a lymphatic endothelial marker in OSCCs has recently been found to play a possible role in odontogenic tumorigenesis also.³ It has been observed in the recent literature that podoplanin expression is also seen in odontogenic tissues like in secretory ameloblasts, developing & mature odontoblasts, Tomes' fibres & pulp cells. It is also expressed in tumor cells of various types of cancer, such as SCC in several organs, germ cell tumors, vascular tumors, malignant mesothelioma and tumors of the central nervous system, and has been shown to play a role in tumor invasion and metastasis through its ability to remodel actin in the cytoskeleton of tumor cells.³

Morphologically, two patterns of tumour invasion can be distinguished: single cell and collective cell invasion. Various pathways have been identified that unravel the molecular mechanisms underlying tumour cell invasion which can determine the invasive potential and the invasion pattern of tumour cells. The invasion of large cell sheets into neighbouring tissue often called collective cell migration is less well understood. Recent experimental results have demonstrated that podoplanin, a small mucin-like protein, mediates a pathway leading to collective cell migration and invasion in vivo and in vitro.⁸ In addition, it was reported that podoplanin was over expressed in oral epithelial dysplasia and lichen planus, which the World Health Organization (WHO) classifies as being potentially malignant disorders. And recently, the role of podoplanin in early oral tumorigenesis has also begun to attract attention.⁹

The expression of podoplanin in tumorous odontogenic cells is a recent topic of study. There is growing evidence that the molecular expression pattern of cells in the invading front of solid tumours is different from that of cells in the tumour interior. Interestingly, both mitotic activity and podoplanin expression within the ameloblastoma are coincident (i.e., virtually restricted to the peripheral epithelial cells of the tumor cords and strands). This provides an evidence of a relationship between podoplanin and odontogenic cellular activity (i.e the protein is expressed during intense proliferative activity in odontogenic cells and when these cells reach maturity or a stable state, there is a reduction or lack of podoplanin immunoreactivity). This pattern of distribution of podoplanin immunostaining, according to the cellular subtype in ameloblastomas, may be helpful to the classification of odontogenic tumors.¹⁰

Podoplanin may be involved in the process of local expansion of developmental, inflammatory and neoplastic odontogenic lesions. The pattern of staining for podoplanin in KCOT could be related to its neoplastic nature, and may suggest a role of this protein in tumor invasiveness.⁴ The commercially available antibody D2-40 originally raised against an unidentified M2A protein derived from germ cell tumors, specifically recognizes human Podoplanin which has biochemical characteristics similar to M2A antigen. Thus it can be used for routine immunohistochemical studies of tumors lymphangiogenesis. It is known that besides endothelial cells, D2-40 is also expressed by other type of normal and neoplastic cells. Therefore D2-40 staining of tumor cells, which marks the

expression of Podoplanin can be evaluated in order to study the potential role of Podoplanin in tumor proliferation and invasion.¹¹

Thus, it is likely that the upregulated expression of Podoplanin in odontogenic cysts could be related to their neoplastic nature. Therefore, we planned the present study to analyze and evaluate the expression of Podoplanin in Keratocystic Odontogenic Tumor and Dentigerous cysts, as the former is now considered a tumor per se because of its behavior, and a significant number of the later have been known to progress to malignancy.

Aims and Objectives

The aim of this study was to “Evaluate the Podoplanin Levels in Odontogenic Cysts” immunohistochemically.

The objectives of the study were:

- To evaluate the expression pattern of Podoplanin in odontogenic keratocystic.
- To evaluate the expression pattern of Podoplanin in dentigerous cyst.
- To compare the expression of Podoplanin expression in these lesions with those seen in the normal tooth follicle.
- To elucidate whether Podoplanin can be used as a marker to indicate progression to tumor formation in Odontogenic cysts.

Materials and Methods

The study was carried out in Department of Oral Pathology and Microbiology of Swami Devi Dyal Dental Hospital and College Barwala. Paraffin-embedded tissue specimens each of Keratocystic Odontogenic Tumors (KCOTs) & Dentigerous cysts were retrieved from the archives of Department of Oral Pathology and Microbiology of Swami Devi Dyal Hospital and Dental College, Barwala.

Sample

The study specimens included were categorized as follows:

Group 1: 20 Specimens of Keratocystic odontogenic tumor (KCOT).

Group 2: 20 Specimens of Dentigerous cyst.

Group 3: 20 specimens of follicular tissue.

Data on patient age, gender, and lesion site were obtained from the biopsy requisition forms submitted. The tissue sections were stained standard hematoxylin and eosin (H & E) stain and Immunohistochemical staining using D2-40 antibody. The stained slides were studied under an Olympus research microscope with CCD video camera with the help of Q Capture pro 7 Image Analysis Software

Procedure for haematoxin and eosin staining

1. The sections were dewaxed.
2. The sections were placed in Xylene I for 1-5 minutes.
3. The sections were placed in Xylene II for 1-5 minutes.
4. The sections were hydrated through descending grades of ethyl alcohol (absolute alcohol - 2 minutes, 90% alcohol -1 minute ,70% alcohol - 1 minute).
5. The sections were then washed with running tap water for 5 minutes.
6. Harris hematoxylin was added to the sections for 5 minutes.
7. The sections were washed well in the running water until sections are blue.
8. Differentiate in 1% acid alcohol for 5-10 seconds.
9. The sections were then washed well in tap water until sections are again blue approximately for 10-15 minutes.
10. Counter staining was done with water soluble 1% Eosin Y for 5 minutes.
11. Thereafter, the sections were dehydrated through ascending grades of alcohol (70% - 1 minute, 90% - 1 minute, and absolute alcohol -2 minutes).
12. The sections were kept in Xylene I for 5 minutes.
13. The sections were kept in Xylene II for 5 minutes.
14. All slides were mounted with adequate mounting media (DPX) and were covered with a cover slip and were adequately labelled and were viewed under the light microscope.

Procedure for D2-40 immunohistochemical staining

1. Tissue section (4µm) from paraffin-embedded, formalin-fixed tissue blocks were mounted on precoated slides with silane (3-aminopropyltrimethoxy silane).
2. Deparaffinized the tissue section with 2 changes of Xylene for 10 minutes each.
3. Then hydrated by putting slides into absolute alcohol for 5 minutes, 90% ethyl alcohol for 5 minutes, 70% ethyl alcohol for 5 minutes and under running tap water.
4. For antigen retrieval, tissue sections were placed in pressure cooker filled with citrate buffer at PH 7.8.
5. Then slides were allowed to cool for half an hour.
6. The sections were then washed with phosphate buffer (PBS) (3 cycles for 3 minutes) in hydrated chamber.
7. The endogenous peroxidase activity was blocked by treating the sections for 10-15 minutes in 0.3% peroxide block solution in an incubator maintained at 40°C.
8. The sections then were washed with phosphate buffer (PBS) (3 cycles for 2 minutes each).
9. After this power block was added on tissue sections for 10-15 minutes and incubated at 40°C.
10. The excess liquid around the tissue section was wiped out with paper pads.
11. The slides were laid flat in a hydrating chamber and 2 drops of primary antibody (D2-40) was added on each tissue section and incubated for 1 hour.

12. The slides were then Washed with phosphate buffer (PBS) (3 cycles for 2 minutes each) in a hydrated chamber.
13. After this, Super Enhancer was added for 20 minutes on the tissue sections and tissues were incubated at 40⁰ C.
14. The slides were then Washed with phosphate buffer (PBS) (3 cycles for 2 minutes each) in a hydrated chamber
15. After this, secondary antibody was added for 30 minutes on the tissue sections and tissues were incubated at 40⁰ C.
16. The slides were then washed with phosphate buffer (PBS) (3 cycles for 2 minutes each) in a hydrated chamber.
17. DAB (Diaminobenzidine) was added for 5-10 minutes till the brown colour appeared.
18. The slides were then kept in distilled water for 10 minutes.
19. After that the slides were counterstained with Hematoxylin for 1 minute.
20. Then the slides were again kept in distilled water for 10 minutes.
21. The slides were then dehydrated through ascending concentration of alcohol (50%, 70%, 90% and absolute alcohol) for 5 minutes each
22. Lastly the slides were placed in Xylene × 2 changes for 5 minutes each and were then mounted with DPX.

Immunostaining Evaluation

Cytoplasmic and / or membranous Podoplanin expression by epithelial odontogenic cells in KCOT, dentigerous cysts & dental follicles were studied under the microscope at a magnification of 40X. The following parameters were followed for scoring of the sections:⁴

0 = Negative

1(+) = weak to moderately positive

2(++) = strongly positive

Statistical Analysis

All data analysis was carried out using Statistical Package for Social Science (SPSS, Version 17) for the descriptive analysis & statistical tests of significance. The Chisquate test was used to compare the mean scores among the study groups. The level of significance was set at 5% for all tests.

Results

Table 1: Showing staining intensity in all the study groups

STAINING CRITERIA		GROUP			TOTAL
		DENTIGROUS CYST	OKC	DENTAL FOLLICLES	
NEGATIVE (-VE)	Count	3	2	0	5
	% within group	15.0%	10.0%	0%	8.3%

WEAKLY POSITIVE (+VE)	Count	8	3	14	25
	% within group	40.0%	15.0%	70.0%	41.7%
STRONGLY POSITIVE (+VE)	Count	6	14	3	23
	% within group	30.0%	70.0%	15.0%	38.3%
NOT ABLE TO EVALUATE	Count	3	1	3	7
	% within group	15.0%	5.0%	15.0%	11.7%
Total	Count	20	20	20	60
	% within group	100.0%	100.0%	100.0%	100.0%

Table 1 shows that Dentigerous Cyst showed:

Negative staining in 3 out of 20 cases studied (15%),
Weakly positive staining in 8 out of 20 cases studied (40%),
Strongly positive staining in 6 out of 20 cases studied (30%), and
3 out of 20 cases studied (15%) could not be evaluated.

Table 1 shows that Parakeratinized Odontogenic Keratocyst Cyst showed:

Negative staining in 2 out of 20 cases studied (10%),
Weakly positive staining in 3 out of 20 cases studied (15%),
Strongly positive staining in 14 out of 20 cases studied (70%), and
1 out of 20 cases studied (5%) could not be evaluated.

Table 1 shows that Dental Follicles showed:

Weakly positive staining in 14 out of 20 cases studied (70%),
Strongly positive staining in 3 out of 20 cases studied (15%), and
3 out of 20 cases studied (15%) could not be evaluated.

Table 2: Comparison Of Podoplanin Staining In Between DC, OKC And DF Cases

Chi- square test	Value	Df	Asymp. Sig. (2-sided)
Pearson Chi-Square	19.658(a)	6	.003**
Likelihood Ratio	21.610	6	.001
Linear-by-Linear Association	.000	1	1.000
N of Valid Cases	60		

** : Significant

Table 2 shows that a comparison of staining of Dentigerous Cyst, Parakeratinized Odontogenic Keratocyst and Dental follicle shows that maximum cases of OKC exhibited strongly positive staining whereas majority of cases of dental follicle and dentigerous cyst showed weakly positive staining.

Table 3: Podoplanin Staining In OKC and DC

STAINING CRITERIA		GROUP		TOTAL
		DENTIGROUS CYST	OKC	
NEGATIVE (-VE)	Count	3	2	5
	% within group	15.0%	10.0%	12.5%
WEAKLY POSITIVE (+VE)	Count	8	3	11
	% within group	40.0%	15.0%	27.5%
STRONGLY POSITIVE (+VE)	Count	6	14	20
	% within group	30.0%	70.0%	50.0%
NOT ABLE TO EVALUATE	Count	3	1	4
	% within group	15.0%	5.0%	10.0%
TOTAL	Count	20	20	40
	% within group	100.0%	100.0%	100.0%

Table 3 shows that:

- Of the slides showing negative staining 3 out of 5 (17.6%) were Dentigerous Cyst, and 2 out of 5 (10.5%) were Parakeratinized Odontogenic Keratocyst.
- Of the slides showing weakly positive staining 8 out of 25 (47.1%) were Dentigerous Cyst, and 3 out of 25 (15.8%) were Parakeratinized Odontogenic Keratocyst, and 14 out 25 (82.4%) were Dental Follicles.
- Of the slides showing strongly positive staining 6 out of 25 (35.3%) were Dentigerous Cyst, and 14 out of 23 (73.7%) were Parakeratinized Odontogenic Keratocyst, and 3 out 25 (17.6%) were Dental Follicles.

Table 4: Comparison of podoplanin staining in between DC and OKC cases

Chi - square test	Value	df	Asymp. Sig. (2-sided)
Pearson Chi-Square	6.673(a)	3	.083
Likelihood Ratio	6.897	3	.075
Linear-by-Linear Association	.878	1	.349
N of Valid Cases	40		

Table 4 shows that a comparison of staining of Dentigerous Cyst with Parakeratinized Odontogenic Keratocyst shows more negative and weakly positive staining in the former and more strongly positive staining in the latter.

Table 5: Podoplanin Staining in DF and DC

STAINING CRITERIA		GROUP		TOTAL
		DENTIGROUS CYST	DENTAL FOLLICLES	
NEGATIVE (-VE)	Count	3	0	3
	% within group	15.0%	.0%	7.5%
WEAKLY POSITIVE (+VE)	Count	8	14	22
	% within group	40.0%	70.0%	55.0%
STRONGLY POSITIVE (+VE)	Count	6	3	9
	% within group	30.0%	15.0%	22.5%
NOT ABLE TO EVALUATE	Count	3	3	6
	% within group	15.0%	15.0%	15.0%
Total	Count	20	20	40
	% within group	100.0%	100.0%	100.0%

Table 5 shows that:

- Of the slides showing negative staining 3 out of 3 (100%) were Dentigerous Cyst, and none of the dental follicle slide showed negative staining.
- Of the slides showing weakly positive staining 8 out of 22 (47.1%) were Dentigerous Cyst, and 14 out of 22 (15.8%) were **Dental Follicles**.
- Of the slides showing strongly positive staining 6 out of 9 (35.3%) were Dentigerous Cyst, and 3 out 9 (17.6%) were Dental Follicles.

Table 6: Comparison of podoplanin staining in between DC and DF cases

Chi- square test	Value	df	Asymp. Sig. (2-sided)
Pearson Chi-Square	5.636(a)	3	.131
Likelihood Ratio	6.836	3	.077
Linear-by-Linear Association	.000	1	1.000
N of Valid Cases	40		

Table 6 shows that a comparison of staining of Dentigerous Cyst with Dental follicles shows more weakly positive staining in the latter, while Dentigerous Cyst shows a more irregular staining with no particular predilection in any one group.

Table 7: Podoplanin staining IN DF and OKC

STAINING CRITERIA		GROUP		TOTAL
		OKC	DENTAL FOLLICLES	
NEGATIVE (-VE)	Count	2	0	2
	% within group	10.0%	.0%	5.0%
WEAKLY POSITIVE (+VE)	Count	3	14	17
	% within group	15.0%	70.0%	42.5%
STRONGLY POSITIVE (+VE)	Count	14	3	17
	% within group	70.0%	15.0%	42.5%
NOT ABLE TO EVALUATE	Count	1	3	4
	% within group	5.0%	15.0%	10.0%
Total	Count	20	20	40
	% within group	100.0%	100.0%	100.0%

Table 7 shows that:

- Of the slides showing negative staining 2 out of 2 (17.6%) were OKC and none of them were dental follicle.
- Of the slides showing weakly positive staining 3 out of 17 (47.1%) were Parakeratinized Odontogenic Keratocyst, and 14 out of 17 (82.4%) were Dental Follicles.
- Of the slides showing strongly positive staining 14 out of 17 (35.3%) were Parakeratinized Odontogenic Keratocyst, and 3 out of 17 (17.6%) were Dental Follicles.

Table 8: Comparison of podoplanin staining in between DC and DF cases

	Value	df	Asymp. Sig. (2-sided)
Pearson Chi-Square	17.235(a)	3	.001**
Likelihood Ratio	19.265	3	.000
Linear-by-Linear Association	1.119	1	.290
N of Valid Cases	40		

** : Significant

Table 8 shows that a comparison of staining of Parakeratinized Odontogenic Keratocyst with Dental follicles shows more strongly positive staining in the former and weakly positive staining in the latter.

Table 9: Showing mean and SD in all the study groups

Group		N	Mean	SD	Min	Max	Percentiles		
							25 th	50 th (Median)	75 th
Dentigerous Cyst	RESULTS	17	2.18	.728	1	3	2.00	2.00	3.00
	GROUP	20	1.00	.000	1	1	1.00	1.00	1.00
OKC	RESULTS	19	2.63	.684	1	3	2.00	3.00	3.00
	GROUP	20	2.00	.000	2	2	2.00	2.00	2.00
Dental Follicle	RESULTS	17	2.18	.393	2	3	2.00	2.00	2.00
	GROUP	20	3.00	.000	3	3	3.00	3.00	3.00

Table 9 shows maximum deviation from the standard in Dentigerous cyst, followed by Parakeratinized Odontogenic Keratocyst, and least in Dental Follicle. This seems probable, as the staining and findings in a physiologic structure as Dental Follicle should be more predictable than a pathology.

Discussion

Of the developmental Odontogenic Cysts, the Odontogenic Keratocyst has long been a lesion of interest to the oral pathologist, and the dental community in general. There is considerable literature on the so called "Primordial cyst", a lesion thought to arise from the primitive odontogenic cells of the dental lamina. The Odontogenic Keratocyst is an aggressive odontogenic cyst, generally causing considerable damage of the bone before it gets diagnosed. Over the years, the Odontogenic Keratocyst had come to be recognized as a distinct entity, and the term Primordial cyst was discontinued for its ambiguity and vagueness. The term Odontogenic Keratocyst was used to indicate a distinctive form of developmental odontogenic cyst that deserves special consideration because of its specific histopathologic features & clinical behaviour. The odontogenic keratocyst was later divided into a less aggressive Orthokeratinized variant and a more aggressive Parakeratinized variant. The parakeratinized variant, with time got established as a distinct entity having true tumorous potential, and the name "Keratocystic Odontogenic Tumor" was coined for the same.¹²

Several investigators have suggested that odontogenic keratocyst be regarded as benign cystic neoplasm rather than cyst, & in the recent WHO Classification of odontogenic tumors (2005), this lesion has been given the name Keratocystic Odontogenic Tumor. The arguments to support this change in nomenclature largely rely on a few studies that have shown certain molecular genetic alterations that are also present in some neoplasms. Unfortunately, these studies have not examined other cystic lesions of the jaws; therefore, it is currently unknown whether these alterations are unique to the odontogenic keratocyst. Most oral & maxillofacial pathologists do not feel that sufficient evidence exists to justify

renaming this widely recognized lesion, with the likely result of causing widespread confusion among the professional community.¹³

Recent times, however, have reverted to the previous concept of this lesion being an aggressive odontogenic cyst. The most important clinical features of the keratocystic odontogenic tumor (KCOT) are its potential for locally destructive behavior and a tendency to recur. The clinical features of KCOT are similar to those of ameloblastoma (AM). Many studies have been done in an attempt to clarify the invasive phenomenon in KCOT. However, the exact molecular mechanism of invasion in these lesions has not yet been well elucidated. Attempts have been made to study the invasive mechanism in KCOT using different molecular markers.

It is also plausible to think whether the dentigerous cyst changing into a malignant lesion has done so because of its long standing presence or had a potential towards malignancy de novo. It may be speculated that dentigerous cyst got diagnosed earlier as compared to other cyst because of routine radiographic examination for individual in the 2nd and 3rd decade of life, as many of these individuals report for orthodontic checkup. So the dentigerous cyst may get diagnosed early in the course of the lesion and lesion which persist for longer period may have the potential to be the tumorous. In support of this hypothesis, it is a frequent finding that many dentigerous cysts are diagnosed after extraction of 3rd molar.

So we attempted to compare the molecular changes in dentigerous cyst with well known aggressive odontogenic cyst i.e the odontogenic keratocyst. Podoplanin (T1a-2, aggrus and gp36) is a 36-43kDa type-1 transmembrane sialomucin like glycoprotein which consists of 162 amino acids. It is specifically expressed in the lymphatic vascular endothelium. Although the protein has been considered as a specific marker for lymphatic endothelial cells, its expression has also been demonstrated in various normal as well as neoplastic cells. In normal human tissues and cells, in addition to the lymphatic endothelium, podoplanin expression has been detected in basal epithelial keratinocytes of the skin, cervix, esophagus, peritoneal mesothelial cells, osteocytes, ependymal cells, stromal reticular cells, and follicular dendritic cells of lymphoid organs. Apart from these, podoplanin expression is also been found in odontogenic epithelial and mesenchymal tissues. In human neoplasms, podoplanin expression has been reported in squamous cell carcinoma (SCC) of the skin and various other malignancies. In addition, podoplanin is reportedly associated with tumor-induced platelet aggregation and tumor metastasis. Podoplanin expression has also been demonstrated in oral leukoplakias and other potentially malignant disorders. Its expression may serve as a marker for predicting the aggressive nature of the lesion. As all these studies have showed increased expression of podoplanin in various malignant tumors, its potential role in tumor progression has been suggested. Recently, podoplanin has been found to play a possible role in odontogenic tumorigenesis and in aggressive/ invasive nature of odontogenic cysts.⁴

Hence, it is important to know the molecular mechanisms by which we can understand the clinical behaviour of these odontogenic cysts and tumors.

Therefore, we felt the need to compare the proliferative potential of these two lesions: the parakeratinized variant of Odontogenic Keratocyst, and the dentigerous cyst. In our study, we compared the immunohistochemical expression of Podoplanin in 20 specimens each of Odontogenic Kertocyst, Dentigerous cyst and Dental follicle (taken as control).

In the present study, we observed weakly positive staining in 8 out of 20 cases of the Dentigerous cyst (40%), and strongly positive staining in 6 out of 20 cases (30%). The staining of Parakeratinized Odontogenic Keratocyst showed weakly positive staining in 3 out of 20 cases (15%), and strongly positive staining in 14 out of 20 cases (70%). The dental follicles which were considered as controls showed weakly positive staining in 14 out of 20 cases (70%). While the weakly positive staining in the dental follicles served to confirm the technique used, a strongly positive stain in 70% of the cases definitely co-related with the aggressive nature and known proliferative potential of the epithelium in Parakeratinized Odontogenic Keratocysts. As compare with this, the dentigerous cyst showed an almost equal distribution of weakly positive and strongly positive staining for podoplanin.

We observed a statistically significant difference on comparing the staining intensity of podoplanin in between DC, OKC and DF (P- value < 0.05). Our results were in correlation with the results obtained by Singhal et al who also observed similar pattern of staining in of Odontogenic Kertocyst, Dentigerous cyst and Dental follicle.¹⁴ Wicki et al., suggested that podoplanin expression can be induced by Epidermal Growth Factor, Basic Fibroblast Growth Factor (FGF2) and Transforming growth factor a in MCF7 breast cancer cells thereby strongly implying the possible role of stroma around the tumor cells in the invasive behaviour of ameloblastomas.¹⁵

Overall, we found more strongly staining pattern in KCOT, whereas Dentigerous cyst showed almost equal pattern of weakly and strongly staining epithelium. We also found that expression of podoplanin was significantly higher in KCOTs than in dentigerous cysts. Our findings are consistent with the findings of Okamoto et al.,³ who also observed similar immunohistochemical reactivity for podoplanin in KCOTs. They have also reported that podoplanin is expressed in limited myoepithelial elements of pleomorphic adenomas which has a tendency to invade surrounding tissues.³

Agaram NP et al.,⁴⁹ observed that a significant number of OKCs showed clonal loss of heterozygosity of tumor suppressor genes like p16, p53, PTCH. Hence, they also supported the hypothesis that OKCs are neoplastic rather than developmental in origin. Our observation of strong expression of podoplanin in basal & suprabasal layers in KCOTs suggests the proliferative activity of these cells, increasing their potential for intrinsic growth and making them locally invasive & aggressive.¹⁶

Staining pattern observed in OKC in our study is similar to the results obtained in ameloblstoma cases in previous studies which fulfill the Vickers and Gorlin criteria, including basal cell layer composed of columnar cells displaying

hyperchromatism, palisaded nuclei, with reverse polarity and subnuclear vacuolization. We, therefore, believe that podoplanin probably plays a role along with other proteins and growth factors, in increasing the proliferative activity of the lining epithelium in KCOT thereby making it to behave more like a neoplasm rather than like a cystic lesion. Hence, we suggest that podoplanin can be used as a potential proliferative marker to indicate the neoplastic behaviour of KCOTs and dentigerous cyst .

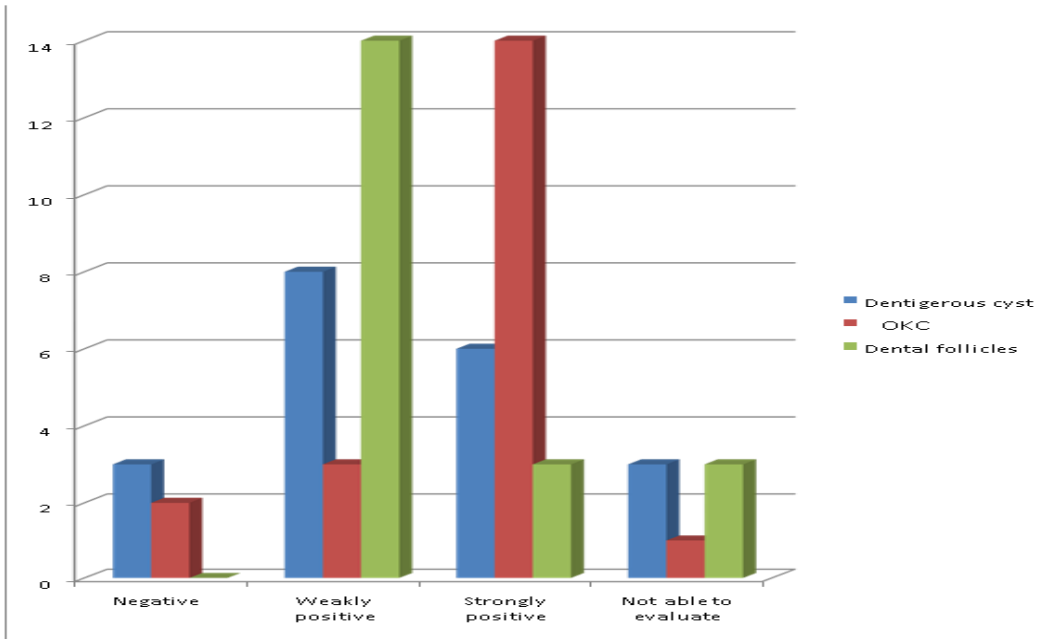
The expression of podoplanin in odontogenic epithelial cells of dental follicle was similar to that of dentigerous cyst lining. Our results are in accordance with the findings of Singhal et al and Tjioe KC et al. According to them, the ameloblasts reduce their size and the number of cellular organelles after the conclusion of their secreting and proliferative activities. This may suggest that podoplanin might be necessary for the proliferative activity of the epithelial odontogenic cells.^{14, 17}

Our study showed an almost equal distribution of podoplanin staining with pattern resembling those seen in KCOT and normal dental follicle. The results of our study suggest that while a sub population of dentigerous cyst may be benign, those seem to be a distinct subpopulation that exhibits molecular changes favouring their aggressive behaviour. In light of the results of our study, we find it plausible to suggest that some dentigerous cyst might be benign, while other may have as aggressive component in their molecular mechanism de novo.

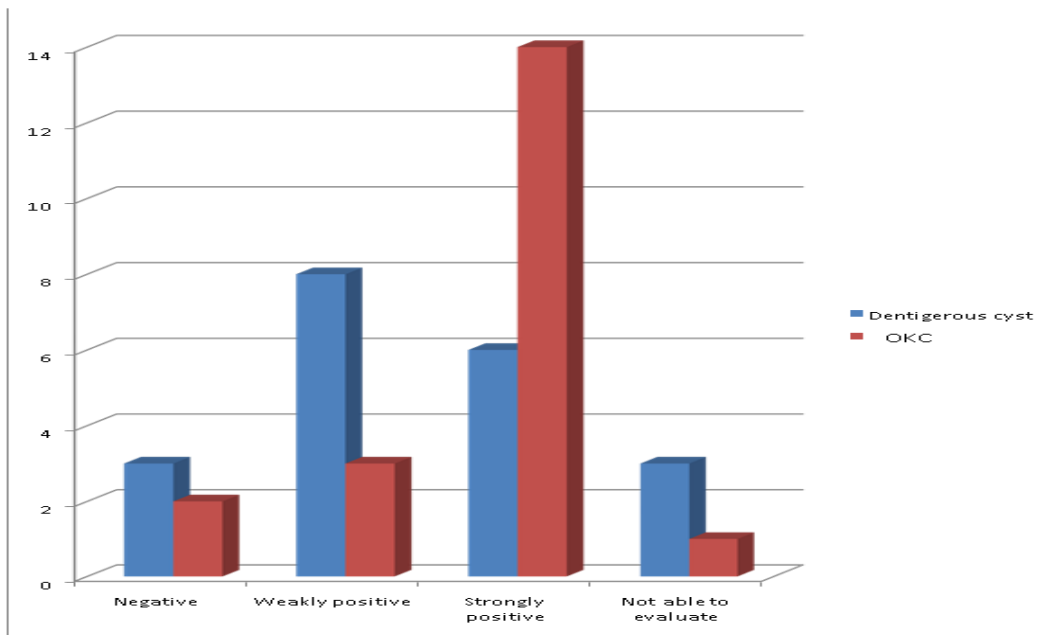
Summary and Conclusion

The results of our study showed that the expression of podoplanin was significantly higher in KCOTs than in dentigerous cysts & dental follicles. The enhanced expression of podoplanin was evident in the cell membrane and cytoplasm of most of the cells in the basal and suprabasal layers & epithelial nests in the connective tissue. To summarize, we feel it is reasonable to say that our results showed strongly positive staining in a majority of the Parakeratinized Odontogenic Keratocysts, while majority of the Dental follicles that were used as negative controls showed weakly positive staining. Dentigerous cysts showed an almost equal distribution in Weakly and strongly positive staining, thereby giving an indication that while some lesions of dentigerous cysts may be benign, others may have a more malignant nature.

Graph 1: Showing the staining intensity in dentigerous CYST, OKC and dental follicle cases



Graph 2
Dentigerous CYST and OKC cases



References

1. Nayak MT, Anjali Singh, Abhishek Singhvi, and Rohit Sharma. Odontogenic Keratocyst: What is in the name? *J Nat Sci Biol Med.* 2013 Jul-Dec; 4(2): 282–285.
2. Shafer, Hine, Levy. *Shafer's Textbook of Oral Pathology.* 7th Edition Elsevier, Delhi 2006
3. Eri Okamoto, Kentaro Kikuchi, Yuji Miyazaki et al. Significance of podoplanin expression in keratocystic odontogenic tumor. *J Oral Pathol Med* 2010; 39: 110–114.
4. Wright JM, Odell EW, Speight PM, Takata T. Odontogenic Tumors, WHO 2005: Where Do We Go from Here? *Head and Neck Pathology.* 2014;8(4):373-382. doi:10.1007/s12105-014-0585-x.
5. Aher V, Chander PM, Chikkalingaiah RG, Ali FM. Dentigerous Cysts in Four Quadrants: A Rare and First Reported Case. *Journal of Surgical Technique and Case Report.* 2013;5(1):21-26.
6. Ugorski M, Dziegiel P, Suchanski J. Podoplanin - a small glycoprotein with many faces. *American Journal of Cancer Research.* 2016;6(2):370-386.
7. Catón J, Tucker AS. Current knowledge of tooth development: patterning and mineralization of the murine dentition. *Journal of Anatomy.* 2009;214(4):502515. doi:10.1111/j.1469-7580.2008.01014.x.
8. A Wicki and G Christofori. The potential role of podoplanin in tumour invasion. *British Journal of Cancer* 2007; 96:1– 5.
9. Shimamura Y, Abe T, Nakahira M, Yoda T, Murata S, Sugasawa M. Immunohistochemical Analysis of Oral Dysplasia: Diagnostic Assessment by Fascin and Podoplanin Expression. *Acta Histochemica et Cytochemica.* 2011;44(6):239-245. doi:10.1267/ahc.11032.
10. Tjioe KC, Oliveira DT, Soares CT, Lauris JR, Damante JH. Is podoplanin expression associated with the proliferative activity of ameloblastomas? *Oral Diseases,* 2012 ;18:673-9.)
11. Bartuli FN, Luciani F, Caddeo F, Compagni S, Piva P, Ottria L, Arcuri C. Podoplanin in development and progression of oral cavity cancer: a preliminary study. *Oral Implantology (ROME).* 2012;5(2-3):33-41.
12. Reichart A : *Odontogenic Tumors and Allied lesions.*
13. Neville, *Oral and Maxillofacial Pathology,* third edition
14. N. Singhal, et al., Immunohistochemical evaluation of podoplanin in odontogenic tumours & cysts using antihuman podoplanin antibody, *J Oral Biol Craniofac Res.* (2017), <http://dx.doi.org/10.1016/j.jobcr.2017.05.001>.
15. Wicki A, Christofori G. The potential role of podoplanin in tumour invasion. *Br J Cancer.* 2007;96:1–5.
16. Agaram NP1, Collins BM, Barnes L, Lomago D, Aldeeb D, Swalsky P, Finkelstein S, Hunt JL. Molecular analysis to demonstrate that odontogenic keratocysts are neoplastic. *Arch Pathol Lab Med.* 2004 Mar; 128(3):313-7.
17. Tjioe KC, Oliveira DT, Soares CT, Lauris JR, Damante JH. Is podoplanin expression associated with the proliferative activity of ameloblastomas. *Oral Dis.* 2012;18:673–679.

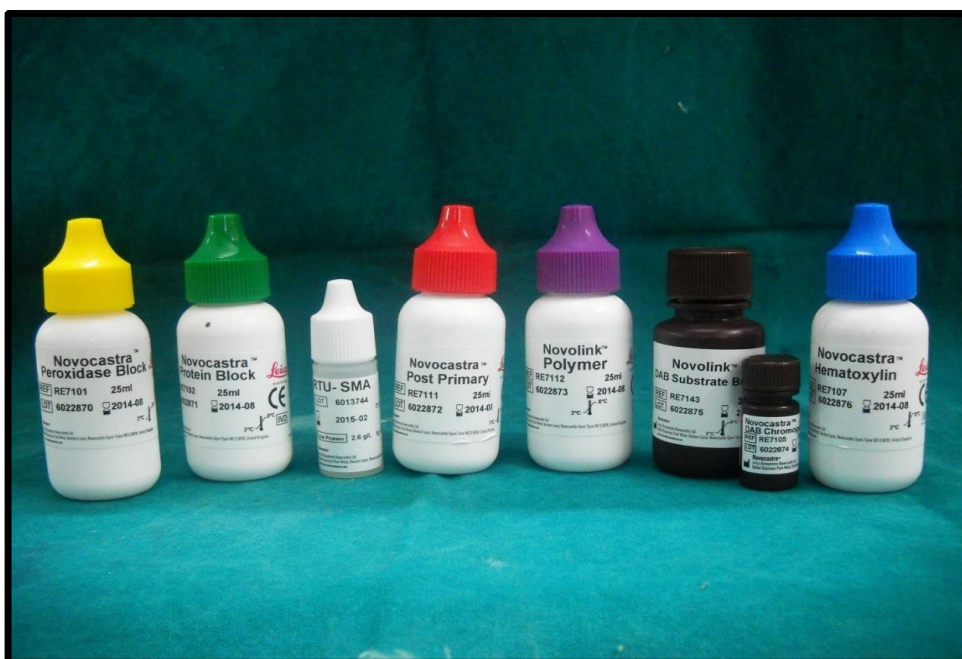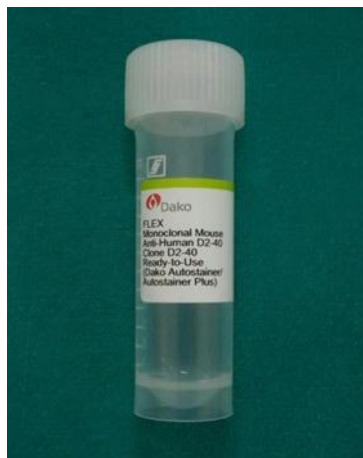


Figure 1. Podoplanin (monoclonal mouse anti human d2-40, Clone d2-40, ready to use, dako flex, autostainer plus, usa) and secondary antibody

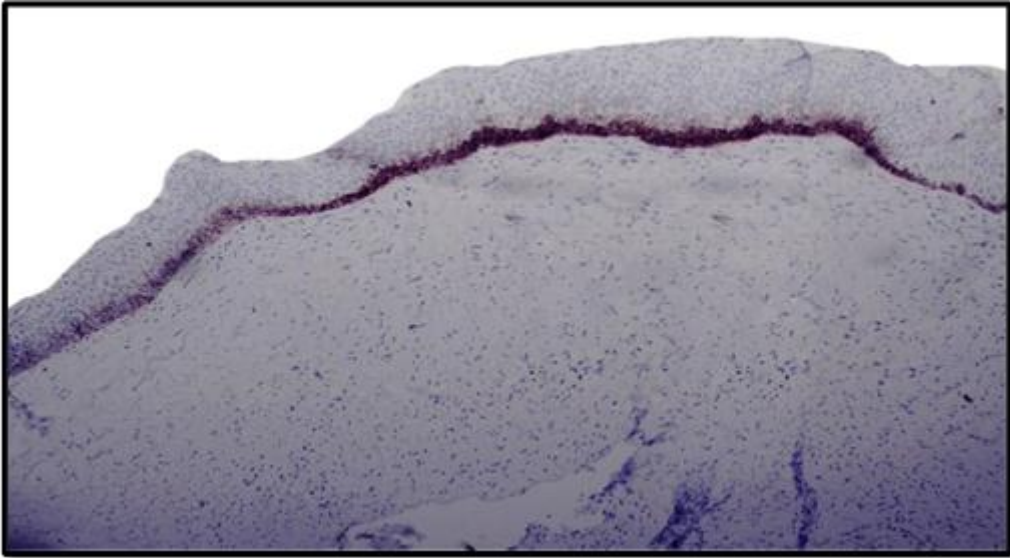


FIGURE 2 : IMMUNOHISTOCHEMICALLY STAINED SECTION OF ODONTOGENIC KERATOCYST, 10X (WEAKLY +VE)

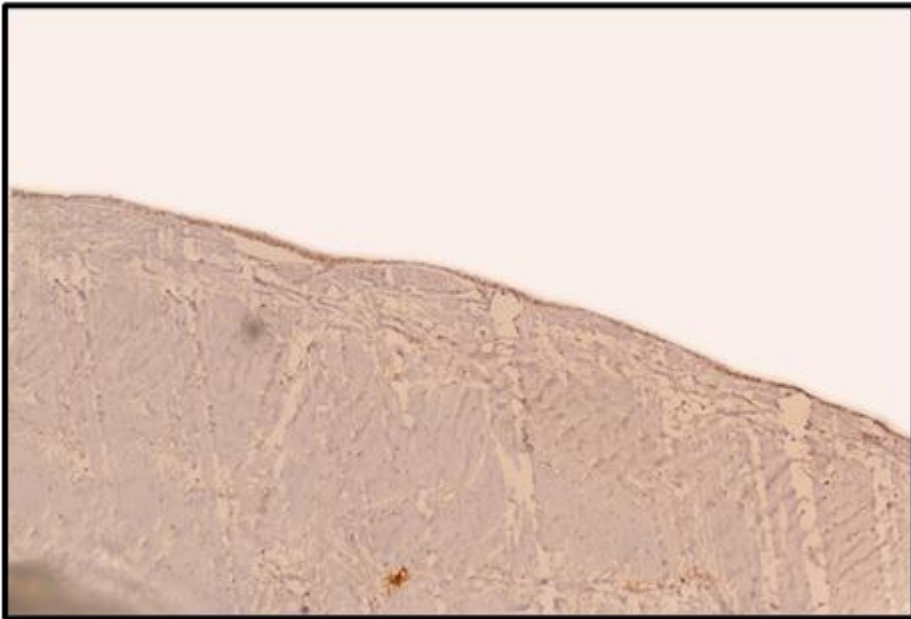


FIGURE 3 : IMMUNOHISTOCHEMICALLY STAINED SECTION OF DENTIGEROUS CYST, 10X (WEAKLY +VE)

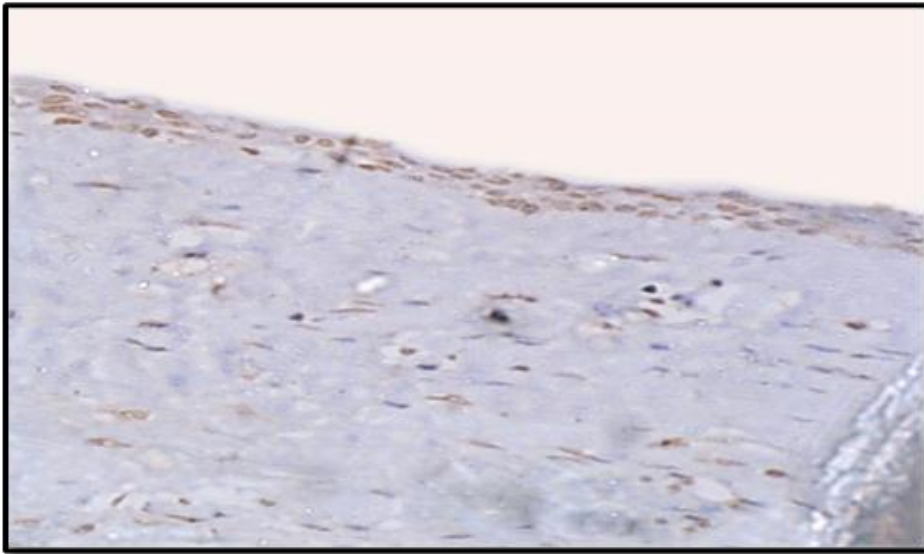


FIGURE 4: IMMUNOHISTOCHEMICALLY STAINED SECTION OF DENTIGEROUS CYST SHOWING STRONGLY POSITIVE STAINING OF EPITHELIAL LINING, 40X (STRONGLY +VE)

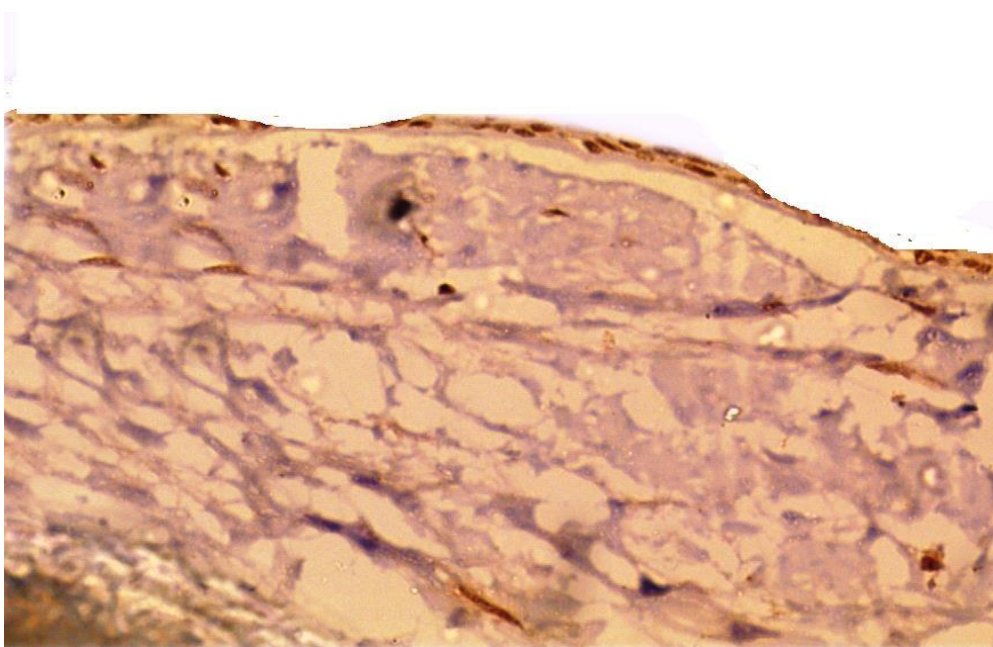


FIGURE 5 : IMMUNOHISTOCHEMICALLY STAINED SECTION OF DENTAL FOLLICLE, 40X (WEAKLY +VE)