

How to Cite:

Shokeir, H. A., Ramadan, W. M., Eittah, M. R. A., & Seessy, N. A. M. E. (2022). Evaluation of fractional erbium: YAG laser and glycolic acid 70% peeling in melasma improvement. *International Journal of Health Sciences*, 6(S3), 1554–1563. <https://doi.org/10.53730/ijhs.v6nS3.5687>

Evaluation of fractional erbium: YAG laser and glycolic acid 70% peeling in melasma improvement

Hesham Aly Shokeir

Professor of Laser Applications in Dermatology, National Institute of Laser Enhanced Sciences Niles (NILE), Cairo University, Egypt
Email: hishamshokeir@hotmail.com

Wafaa Mohammad Ramadan

Faculty of Medicine, Tanta University, Egypt
Email: profwafaramadan@yahoo.com

Maha Rafie Abo Eittah

Assistant Professor of Laser Applications in Dermatology, National Institute of Laser Enhanced Sciences Niles (NILE), Cairo University, Egypt
Email: manalrafei@yahoo.com

Noura Abdel Moneim El Seessy

Master Degree of dermatology and Venereology, Assistant lecture of dermatology- Faculty of Medicine- kafr El Sheik University, Egypt
Email: nouraelseessy@yahoo.com

Abstract--Melasma is an acquired chronic hyperpigmentation which mainly affects women on sun-exposed areas of the body, especially on the face in Fitzpatrick skin types III-V. The study setting is at the Dermatology Clinic at NILES, Cairo University, Egypt. This study aims to evaluate the clinical efficacy and safety of fractional ablative erbium:YAG Laser therapy versus chemical peeling in treatment of melasma. This study included 30 patients with melasma on their face aged 20-50 years. The patients were divided into two groups. In group I, 15 patients were treated by four sessions of fractional erbium YAG laser at 4 weeks interval. In group II, 15 patients were treated by four sessions of chemical peeling with glycolic acid 70%.The percentage of improvement in patients treated by fractional erbium YAG laser was 20 – 80% with a mean 54.33 ± 18.01 and the percentage of improvement in patients treated by chemical peeling was 30 – 85 % with a mean 53.33 ± 18.09 . So, there was no significant difference in the percentage of improvement in both groups (P- value = 0.881). It

was observed that fractional erbium YAG is as effective as 70% glycolic acid peel in patients with melasma.

Keywords---chemical peeling, erbium YAG laser, glycolic acid, Melasma.

Introduction

Melasma is a common pigment disorder associated with psychosocial distress. Melasma occurs mainly in women (only 10% of the cases are males) with Fitzpatrick skin types IV to VI. Melasma is characterized by brownish macules usually on the face [1], [2]. The pathogenesis of melasma is not clear enough but the most important etiologic factors are genetic factor and ultraviolet radiation exposure [3]. Melasma can be classified based on the site of the lesions into craniofacial, malar and mandibular. Histologically, melasma is three types: epidermal type, dermal type and mixed type. Also the Wood's lamp is used to determine type of melasma: epidermal, dermal and mixed [4], [5]. Various lasers are used to treat melasma, including Q-switched Nd:YAG, Q-switched alexandrite, pulsed dye laser, and different fractional lasers as fractional ablative erbium:YAG laser (2940 nm) [2].

The laser treatment of pigmented lesions is based on the theory of Selective Photothermolysis as specific wavelength of energy is delivered in a period of time shorter than the thermal relaxation time (TRT) of the target chromophore [2]. The ablative lasers target the water. These lasers can indirectly reduce melanin deposits from both the epidermis and dermis by vaporization of tissue including number of abnormal epidermal melanocytes and melanin content. Also, during healing process, the epidermis is regenerated from the appendiceal units by migration of new melanocytes to the epidermis that is unable to produce melanin [6]. Also, melasma can be treated by chemical peels such as glycolic acid. Mechanism of chemical peeling in the treatment of melasma is to create an injury of a specific skin depth to stimulate skin growth and improve surface, texture and appearance [7].

Aim of the study

To evaluate the clinical efficacy and safety of fractional ablative erbium:YAG Laser therapy versus chemical peeling in treatment of melasma.

Patients, Materials and Methods

This study included **30** patients with melasma on their face aged 20-50 years, divided into two groups. Group (I), 15 patients were treated by fractional erbium YAG laser. Group (II), 15 patients were treated by chemical peeling (Glycolic acid 70%). We excluded the patients who had previously been treated within the past 6 months, pregnant patients or lactating women. The study protocol was approved by the ethical committee of National Institute of Laser Enhanced Sciences (NILES), Cairo University. In addition, the study followed the ethical guidelines of the National Institute of Laser Enhanced Sciences (NILES), Cairo University .

Informed consent was obtained from all individual participants included in the study.

Patients were subjected to full history taking including age, sex, occupation, duration of the lesion, previous treatments received past history and family history of same condition. Full examination to determine type of melasma was done by both Wood's lamp and Dermoscopy, its distribution on the face, and its severity index by MASI score, and its vascular and pigmentary component by dermoscopy. Treatment was every 4 weeks with fractional ablative erbium:YAG (2940 nm) laser. Chemical peeling by glycolic acid 70% was done every 4 weeks. Pre-operative measures: application of topical anesthesia for one hour prior to laser. Post-operative measures: application of local cooling, antibiotic ointment, and sunscreen. Mild topical steroid was prescribed if erythema and edema persist more than 3 days. Avoidance of rubbing and scratching was advised. Assessments were carried out on the basis of patient satisfaction, observations and photographic records at the beginning and the end of the treatment and after the period of follow up.

Histopathological examination: small skin biopsy (by punch 2mm) under complete sterilization from the side of the face before and after the treatment. The sites of biopsies healed with unnoticeable scars on the face. Dermoscope was used to evaluate degree of pigmentation and vascular component of melasma. Patients were followed up six months after the end of the treatment to observe recurrences and any side effects (after one month, after three months and after six months). Safety assessment to detect any complications occurred for the patients as burning pain erythema, edema, itching, infection, any allergic manifestations, post inflammatory hypo or hyperpigmentation etc. Statistical analysis for the data was done.

Results

This study was carried out on 30 patients with melasma on their face, aged between 20 years and 50 years with a mean 37.365 ± 2.955 . The patients were divided into two groups of 15 patients each. In group I, patients were subjected to four sessions of 2940 nm Erbium YAG fractional laser with mean age 37.13 ± 5.60 . In group II patients with mean age 37.60 ± 6.31 , four sessions of chemical peeling with 70% glycolic acid were performed. The type of melasma was divided by woods light in to 3 types (epidermal, dermal, and mixed). In group (I), there were 8 patients with epidermal melasma, 5 patients with dermal melasma, and 2 patients with mixed melasma. In group (II), there were 8 patients with epidermal 3 patients with dermal melasma, and 4 patients with mixed melasma. The skin types of the patients ranged from II – IV. In both groups; there were 6 patients with skin type II, 7 patients with skin type III and 2 patients with skin type IV.

Severity index of melasma according to MSI score in patients treated by laser, there were 2 patients with mild melasma, 9 patients with moderate melasma and 4 patients with severe melasma. But in patients treated by glycolic acid 70%, there were 3 patients with mild melasma, 9 patients with moderate melasma and 3 patients with severe melasma. The percentage of improvement by laser therapy was 60 – 80 % in epidermal melasma, 20 - 50 % in dermal melasma, and 30 – 50

% in mixed type. There was significant improvement in epidermal type by laser treatment (P- value = 0.001*). The percentage of improvement by peeling therapy was 50 – 85 % in epidermal melasma, 30 - 50 % in dermal melasma and 30 – 40 % in mixed type. There was significant improvement in epidermal type by chemical peeling treatment (P- value = 0.002*). The percentage of improvement in patients treated by fractional erbium YAG laser was 20 – 80 % with a mean 54.33 ± 18.01 and the percentage of improvement in patients treated by chemical peeling was 30 – 85 % with a mean 53.33 ± 18.09 . So, there was no significant difference in the percentage of improvement in both groups (P- value = 0.881) Table (1). Clinical and histopathological images of some patients are shown in Figs. 1 and 2.

The percentage of improvement in patients treated by laser with skin type II was 50-80% , 20 - 70% in patients with skin type III and 30% in patients with skin type IV with significant improvement in skin type III (p. value =0.012*). By chemical peeling, the percentage of improvement was 40-70% in patients with skin type II, 30-85% in patients with skin type III and 30-75% in patients with skin type IV with non-significant value (p. value =0.998). In group (I), the improvement was 50% in patients with mild melasma, 20-80% in patients with moderate melasma and 30-75% in patients with severe melasma with non-significant value (p. value =0.693). In group (II), the improvement was 30-60% in patients with mild melasma, 30-85% in patients with moderate melasma and 40-80% in patients with severe melasma with non-significant value (p. value =0.453).

By dermoscopy, melasma has pigmented component and vascular component. The percentage of decrease of vascular component in group (I) was 20-60% and in group (II) was 10-30% with significant decrease in vascular component in patients treated by fractional Erbium YAG laser (P. value= 0.001*) Table (2). In this study, all patients were followed up after 3 months and after 6 months. No recurrence occurred in both groups after 3 months but the recurrence occurred in some cases after 6 months in both groups. There was recurrence in 6 patients of 15 patients treated by laser (40 %) and 4 patients of 15 patients treated by peeling (26.7 %). So there was no significant difference between both groups (P – value = 0.439). The total percentage of recurrence in all patients in both groups was 33.3 %. All patients (100%) suffered from burning pain during and immediately after session with variable degree in both groups. All patients (100%) suffered from erythema after laser sessions but this erythema was improved by the topical steroid. Only 5 patients (30%) suffered from erythema after peeling sessions. No post inflammatory hypo or hyperpigmentation was occurred.

Discussion

Melasma is a common pigment disorder and always needs for dermatological care. Melasma causes psychosocial and emotional distress, and reduces the quality of life of the affected patients [8]. This study was carried out on 30 patients (29 female and only one male) with melasma on their face with skin types II-IV, with mean age 37.365 ± 2.955 . That was in agreement with Miot in 2009 and Handel in 2014 who said that melasma is an acquired chronic hypermelanosis which mainly affects women during fertile age and more pigmented phenotypes (Fitzpatrick skin types III-V). Melasma is characterized by irregular brown macules symmetrically

distributed on sun-exposed areas of the body, especially on the face [8-9]. Sun exposure (without burning) is the most important triggering factor for melasma. The use of high-protection-factor sunscreen decreases the intensity of the disease in 50% [8-9-10].

In the present study, the patients were treated by 2940 nm Erbium YAG fractional laser or chemical peeling with 70% glycolic acid. That was in agreement with Lee in 2017 who said that main stays of treatment include topical hypopigmenting agents, lasers, chemical peels, and dermabrasion. Also Sharad in 2013 said that melasma, post inflammatory hyperpigmentation, photoaging, and seborrhea are indications for glycolic acid peel. Also Manaloto in 1999 reported that the Erbium YAG laser resurfacing effectively improves melasma. Sarkar in 2012 also reported that hydroxy peels like glycolic acid, salicylic acid, Jessner's, TCA, azelaic acid peels have been studied extensively for their therapeutic benefits in resistant melasma [11-12, 13]. There are other topical modalities of treatment of melasma as topical hydroquinone. Hydroquinone is the gold standard treatment of melasma. Hydroquinone affects not only the formation, melanization, and degradation of melanosomes, but it also affects the membranous structures of melanocytes and eventually causes necrosis of whole melanocytes [12, 14].

Also there are other types of lasers used in treatment of melasma as Q- switched Nd:YAG. It is the most widely used laser for the treatment of melasma. The 1064 nm Q- switched Nd:YAG is well absorbed by melanin and being a longer wavelength causes minimal injury to epidermis and is not absorbed by haemoglobin. The deeper skin penetration is also helpful to target dermal melanin. Low dose QS Nd:YAG laser induces sublethal injury to melanosomes causing fragmentation and rupture of melanin granules into the cytoplasm [2, 15]. The type of melasma was divided by woods light in to 3 types (epidermal, dermal, and mixed). That was in agreement with Tamler in 2009 who mentioned that by Wood's lamp examination: epidermal melasma - there is a color accentuation as the light is absorbed by the excess of melanin in the basal or suprabasal regions, dermal melasma- no color accentuation is noticeable and mixed melasma- increased staining is seen only in a few sites as the deposit of melanin occurs in both dermis and epidermis [16].

Tamler also said that by dermoscopy, epidermal type the brownish and regular pigmented network; dermal type, the staining bluish gray, in which the network loses its regularity; and mixed type, the presentation of areas compatible with both [16]. On the other hand, Lee in 2017 mentioned that melasma involves increased melanin production and melanocytosis. It may be principally epidermal, dermal, or mixed [13]. Also Hammerschmidt in 2012 reported that although Wood's lamp is a widely used method in the classification of melasma, however it has a low rate of correct diagnosis and dermoscopy can be used to classify melasma into: epidermal (brownish hue and regular pigmentary network), dermal (bluish-gray hue, with irregular pigmentary network), and Mixed [17]. Melasma was classified according to the severity index of melasma in to mild, moderate and sever. As Hammerschmidt in 2012 reported that the MASI is a useful measure in the clinical classification of melasma [17].

In this study, the percentage of improvement was 60 – 80 % with significant in epidermal melasma treated by laser (P- value = 0.001*). It was in agreement with Wanitphakdeedech in 2009 who mentioned that the fractional lasers that target the water, can indirectly decrease melanin deposits from both the epidermis and dermis because of vaporization of tissue leading to decrease the number of abnormal epidermal melanocytes and melanin content and also to decrease the amount of melanin deposited into dermal melanophages. Also, during healing process, the epidermis is regenerated from the appendiceal units by migration of new melanocytes to the epidermis that is unable to produce melanin [6].

Also the percentage of improvement was 50 – 85 % in epidermal melasma treated by glycolic acid 70% (P- value = 0.002*). It was in agreement with Morais in 2013 who mentioned that melasma can be treated by chemical peels such as glycolic acid. Chemical peels are used to create an injury of a specific skin depth to stimulate skin growth and improve surface, texture and appearance. The exfoliating effect of chemical peel stimulates new epidermal growth and collagen with more evenly distributed melanin [7]. In this study, the percentage of improvement in patients treated by fractional erbium YAG laser was 20 – 80 % with a mean 54.33 ± 18.01 and the percentage of improvement in patients treated by chemical peeling was 30 – 85 % with a mean 53.33 ± 18.09 . So, there was no significant difference in the percentage of improvement in both groups (P- value = 0.881). This is expected as the mechanisms of both procedures are very effective.

By dermoscopy, melasma has pigmented component and vascular component. The percentage of decreasing in vascular component in group (I) was 20-60% and in group (II) was 10-30% with significant vascular decrease in patients treated by laser (P. value= 0.001*). Tamler in 2009 mentioned that dermoscopy of melasma shows very characteristic changes. It is possible to observe the vascular component, which is present in a large number of patients [16]. Vascular and pigmented components can be observed by dermoscopy. But the dermoscopy is more useful in measuring the vascular component and Wood's lamp is more useful in measuring the pigmented component. It was in agreement with Hammerschmidt in 2012 who reported that in a comparative study with Wood's lamp, dermoscopy was considered more appropriate for classifying melasma because it evaluated vascular components objectively. Dermoscopy was not considered a good classification method to evaluate pigmentary components [17].

The decrease of vascular component by the laser might be due to thermal effect of laser on blood vessels causing thermal necrosis. It was in agreement with Katz in 2010 who reported that fractional photothermolysis creates multiple microscopic zones of thermal damage and leaves the majority of the skin intact as a reservoir for healing. These multiple columns of thermal damage are called micro thermal treatment zones (MTZ) and lead to extrusion of melanin and damaged melanocytes [18]. Also Park in 2015 mentioned that the fractional type produces denatured columns of epidermis and dermis, and disrupts the dermal-epidermal junction [19]. During the follow up of patients, there was recurrence in 6 patients of 15 patients group I (40 %) and 4 patients of 15 patients group II (26.7 %). So there was no significant difference between both groups (P – value = 0.439). The total percentage of recurrence in all patients in both groups was 33.3 %. Sardesai in 2013 and Sheth in 2011 said that due to unclear pathogenesis of melasma,

treatments of melasma aim to decrease exposure to sun radiation. This reduces the biosynthesis, transport and transfer of melanin. Thus, long-term therapies are necessary, and recurrence rates are high [20-21].

All patients (100%) suffered from burning pain during and immediately after session with variable degree in both groups. All patients (100%) suffered from erythema after laser sessions but this erythema was improved by the topical steroid. Only 5 patients (30%) suffered from erythema after peeling sessions. No post inflammatory hypo or hyperpigmentation was occurred. Sharad in 2013 reported that the minor side effects reported are: erythema, stinging sensation, sensation of pulling of facial skin, mild burning, and transient post inflammatory hyperpigmentation. Glycolic acid can cause erosive blisters and scarring. In rare cases, hypopigmentation and persistent erythema have been reported [22]. Also Arora in 2012 mentioned that the laser treatment of melasma is still controversial. This is because lasers have not been able to produce complete clearance of melasma and recurrence rates are high. Laser treatments also cause complications such as hypopigmentation and post-inflammatory hyperpigmentation [2]. And Puri in 2013 reported also that the common side effects after peels were burning sensation, pain, erythema and hyperpigmentation [3].

Conclusion

In this study, Melasma occurred mainly in females (skin type II-IV). There was no significant difference in the percentage of improvement in patients treated by laser or chemical peeling. By dermoscopy, the laser treatment caused significant decreasing in the vascular component. There was recurrence in both groups after 6 months with non-significant difference between the two groups.

Conflict of interest

The authors declare that they have no conflict of interest.

Funding

There are not any financial ties to include.

Ethical approval

“All procedures performed in studies involving human participants were in accordance with the ethical standards of National Institute of Laser Enhanced Sciences (NILES), Cairo University. In addition, the study followed the ethical guidelines of the National Institute of Laser Enhanced Sciences (NILES), Cairo University.”

Informed consent

Informed consent was obtained from all individual participants included in the study.

References

1. Pawaskar MD, Parikh P, Markowski T, Mc Michael AJ, Feldman SR, Balkrishan R (2007) Melasma and its impact on health related QOL in Hispanic women. *J Dermatolog Treat* 18:5-9.
2. Arora P, Sarkar R, Garg VK, Arya L (2012) Lasers for treatment of melasma and post-inflammatory hyperpigmentation. *J Cutan Aesthet Surg* 5 (2): 93-103.
3. Puri N and Puri A (2013) A study on fractional erbium glass laser therapy versus chemical peeling for treatment of melasma in female patients. *J Cutan Aesthet Surg* 6(3):148 – 151.
4. Kang WH, Yooh KH, Lee ES, Kim J, Lee KB, Yim H, et al (2002) Melasma: Histopathological characteristics in 56 korean patients. *Br J Dermatol* 146: 228- 237.
5. Rokhsar CK and Fitzpatrick RE (2005) The treatment of melasma with fractional photothermolysis: A pilot study. *Dermatol Surg* 31: 1645 – 1650.
6. Wanitphakdeedech R, Manuskiatti W, Siriphukpong S, Chen TM (2009) Treatment of melasma using variable square pulse Er:YAG laser resurfacing. *Dermatol Surg* 35:475-481.
7. Morais OO, Lemos EF, Sousa MC, Gomes CM, Costa IM, Paula CD (2013) The use of ablative lasers in the treatment of facial melasma. *An. Bras. Dermatol.* 88:590 – 596.
8. Handel AC, Miot LD, Miot HA (2014) Melasma: a clinical and epidemiological review. *An Bras Dermatol.* 89(5):771–82.
9. Miot HA, Miot LD (2009) Re: Topical 10% zinc sulfate solution for treatment of melasma. *Dermatol Surg.* 35:2050-1.
10. Lakhdar H, Zouhair K, Khadir K, Essari A, Richard A, Seite S, et al (2007) Evaluation of the effectiveness of a broad-spectrum sunscreen in the prevention of chloasma in pregnant women. *J Eur Acad Dermatol Venereol.* 21:738-42.
11. Manaloto RM, Alster T (1999) Erbium:YAG laser resurfacing for refractory melasma. *Dermatol Surg.* 25(2):121-3.
12. Sarkar R, Chugh S, Garg VK (2012) Newer and upcoming therapies for melasma. *Indian J Dermatol Venereol Leprol.* 78(4):417-28.
13. Lee BW, Schwartz RA, Janniger CK. Melasma (2017) *G Ital Dermatol Venereol.* 152(1):36-45.
14. Bandyopadhyay D. TOPICAL TREATMENT OF MELASMA *Indian J Dermatol.* 2009; 54(4): 303–309.
15. Lee MW. Combination 532-nm and 1064-nm lasers for noninvasive skin rejuvenation and toning. *Arch Dermatol.* 2003; 139:1265–76.
16. Tamler C, Fonseca RM, Pereina FB and Barcani CB (2009) Classification of melasma by dermoscopy: comparative study with Wood’s lamp. *Surgical & Cosmetic Dermatology* 1(3):115-119
17. Hammerschmidt M, Mattos SM, Freitas CF, and Mukal MM (2012) Evaluation of melasma classification methods based on response to treatment. *Surg Cosmet Dermatol* 4(2):155-8.
18. Katz TM, Glaich AS, Goldberg LH, Firoz BF, Dai T, Friedman PM (2010) Treatment of melasma using fractional photothermolysis: A report of eight cases with long-term follow-up. *Dermatol Surg.* 36:1273–80.

19. Park GH, Chang SE, Bang S, Won KH, Won KH, Won CH, Lee MW et al (2015) Usefulness of Skin Explants for Histologic Analysis after Fractional Photothermolysis. *Ann Dermatol.* 27(3): 283-290.
20. Sheth VM, Pandya AG (2011) Melasma: a comprehensive update: part II. *J Am Acad Dermatol.* 65:699-714.
21. Sardesai VR, Kolte JN, Srinivas BN (2013) A clinical study of melasma and a comparison of the therapeutic effect of certain currently available topical modalities for its treatment. *Indian J Dermatol.* 58:239.
22. Sharad J (2013) Glycolic acid peel therapy – a current review. *Clinical, Cosmetic and Investigational Dermatology* 6:281-288.

Appendix

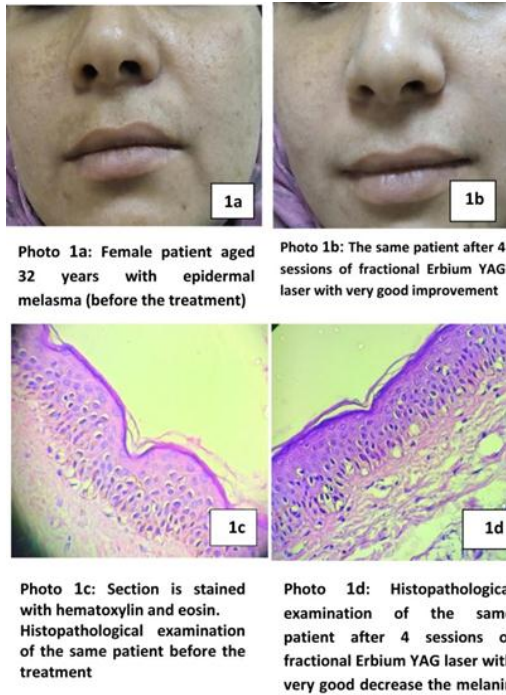

Fig 1. Patient with Epidermal Melasma Before And After The Laser Treatment

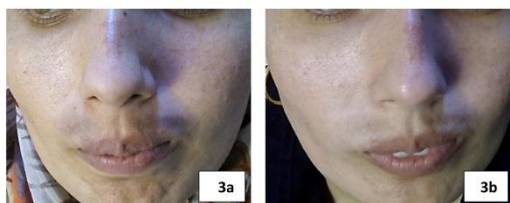


Photo 3a: Female patient aged 31 years with epidermal melasma (before the treatment)

Photo 3b: The same patient after 4 sessions of chemical peeling with glycolic acid 70% with very good improvement

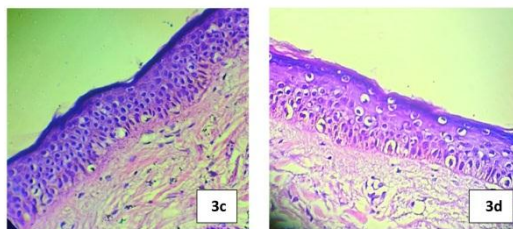


Photo 3c: Section is stained with hematoxylin and eosin. Histopathological examination of the same patient before the treatment

Photo 3d: Histopathological examination of the same patient after 4 sessions of chemical peeling with glycolic acid 70% with very good decrease in the melanin content

Fig 2. Patient with Epidermal Melasma before and After Chemical Peeling Treatment

Table 1
The percentage of improvement in both groups

Improvement %	Group (I) Erbium YAG Laser	Group (II) Chemical Peeling
Range	20 – 80	30 – 85
Mean \pm SD	54.33 \pm 18.01	53.33 \pm 18.09
T. test	0.023	
P. value	0.881	

Table 2
The percentage of decrease of vascular component in both groups by dermoscopy

Dcrease of vascular component % by dermoscopy	Group (I) Erbium YAG Laser	Group (II) Chemical Peeling
Range	20 – 60	10 – 30
Mean \pm SD	45.23 \pm 12.46	24.33 \pm 7.24
T. test	34.968	
P. value	0.001*	