

**How to Cite:**

Sakolia, A., Kaur, G., & Aggarwal, P. (2021). Recent advances in orthodontic diagnostic aids. *International Journal of Health Sciences*, 5(S2), 252–260.

<https://doi.org/10.53730/ijhs.v5nS2.5768>

## Recent advances in orthodontic diagnostic aids

**Avkash Sakolia**

PG student (1st year), Department of Orthodontics & Dentofacial Orthopaedics, Desh Bhagat Dental College & Hospital, Desh Bhagat University, Mandi Gobindgarh

**Gurpreet Kaur**

Professor, Department of Orthodontics & Dentofacial Orthopaedics, Desh Bhagat Dental College & Hospital, Desh Bhagat University, Mandi Gobindgarh

**Pancham Aggarwal**

Reader, Department of Orthodontics & Dentofacial Orthopaedics, Desh Bhagat Dental College & Hospital, Desh Bhagat University, Mandi Gobindgarh

**Abstract**--In the field of Orthodontics, there have been many advances. This article summarizes the recent advancements in diagnostic aids in Orthodontics which has helped revolutionize treatment planning for the Orthodontic fraternity. Many advances have been taken place in the field of dentistry since its development. Dental diagnostic records have advanced from study casts and periapical x-rays to cone beam computed tomography, magnetic resonance imaging and ultrasound. Orthodontic diagnosis require a broad overview of the patient's situation & must take into consideration both objective & subjective findings.

**Keywords**--orthodontics, cone beam, computed tomography.

**Introduction**

Diagnosis is an essential step that forms an important link between clinical examination and medical or dental treatment. Diagnosis involves the development of comprehensive and precise database of pertinent information, sufficient to understand the patient problem as well as questions arising in clinicians mind during treatment. Based on the clinical examination, radiographic interpretation and laboratory results, diagnosis can be further modified<sup>1</sup>. Many advances have been taken place in the field of dentistry since its development. Dental diagnostic records have advanced from study casts and periapical x-rays to cone beam computed tomography, magnetic resonance imaging and ultrasound<sup>2</sup>.

## **Digigraph**

Kevin H Y Mok and Michael S Cooke<sup>3</sup> described about the use of digigraph in orthodontic diagnosis. It is a sonic digitization technique. This technology helps to register linear distances, while also reducing the radiation exposure from lateral cephalometric tracings for patient diagnosis. Mesiodistal widths of teeth are recorded after digitization of the plaster cast. Mesiodistal measurements were taken with the help of digitizing hand piece. The tip of the hand piece is positioned on the chosen landmark and while pressing the button on the handpiece.

## **Rapid Prototyping (RP)**

RP is a type of computer-aided manufacturing (CAM) and is one of the components of rapid manufacturing. It is a technology that can make physical objects directly from 3D computer data by adding a layer-upon-layer<sup>4</sup>. First, slicing of the digital model is done, and then through an automated process of layer-by-layer construction, transverse sections are physically produced. These 3D physical structures are known as rapid prototypes. Rapid prototypes contain mobile parts with complex geometry that is impossible to be made by other construction techniques<sup>5,6</sup>. In addition, before definitive fabrication of prosthesis, this technique allows visualization and testing of objects, which reduces cost<sup>7</sup>. RP model can be used as a tool for diagnosis and treatment planning in orthodontia. These may include identifying the exact position of impacted canine as suggested by Faber,<sup>8</sup> locating exact anatomical relationship between the impacted tooth and other teeth. Fabrication of anatomical model with use of RP can help the surgeon to plan and perform the surgery in a better way and achieve better postoperative results. Discrepancies due to asymmetry can be measured directly on the model, and manipulation can be made if required before the actual surgical procedure is performed.<sup>9</sup> As a part of computer-assisted orthognathic surgery, SLA can also be used for making surgical splints.<sup>10</sup>

## **Digital study models**

Stevens R D et al<sup>11</sup> described about digital study models.( fig.1) The digital study models help an orthodontist to send the alginate impression of the patient or the existing plaster model of the patient to dental imaging companies and help to process the impression or plaster study models into a virtual 3D image in the computer. They can be retrieved any time from the company website. They have traditionally been cast out of either plaster or stone and have served two main purposes:

- To provide information for diagnosis and treatment planning
- To provide a 3D record of the original malocclusion, any stage during correction and outcome of the treatment. <sup>12,13</sup>.

Some successful companies in producing high-quality 3-D models are Orthocad<sup>13,14</sup>and Geodigm<sup>15</sup>.

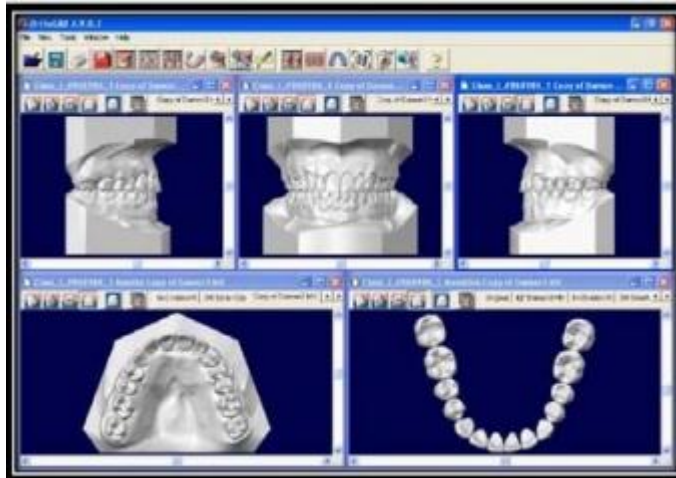


Figure 1. Digital Study Models (orthocad)

### **Orthocad**

The Orthocad digital study model capture, assess, and storage system which is used by approximately 10% of the orthodontists in USA and Canada<sup>13</sup>. This software has been developed by CADENT (computer aided dentistry, Fairview, NJ, USA.). They use state of the art computer-aided design to optically scan in the model image from a plaster equivalent. These are then presented to orthodontist through the patent orthocad software user interface that allows both structured and free manipulation of models in virtual space, and data collection through a range of diagnostic tools.

### **Geodigm**

Geodigm E-models are constructed through a proprietary laser scanning process, that digitally maps the geometry of patient's anatomy into a high dimensional 3-D image, with an accuracy of 0.1 mm. Scanners project a laser stripe on the surface of the cast and use digital cameras to analyze distortions in the stripe. The cast is oriented in all axes to expose for scanning. This produces 3D vertices that are connected to thousands of triangles to form the 3D image. The software then displays the e-model on the computer screen by giving colour shades, to each triangle based on its orientation to a digital light source. The result is a 3D image, which can be viewed, measured or manipulated on screen as if it is cast in your hand<sup>15</sup>.

### **Tuned aperture computed tomography (TACT)**

RL Webber, RA Horton, D A Tyndall and JB Ludlow<sup>16</sup> described a novel technology for the acquisition of 3-dimensional radiographic data. It is also known as transmission radiography. TACT images are produced from a number of x-ray projections based on a reference point. They are helpful in visualizing hard tissues of the oral cavity. From an arbitrary number of x-rays projection a TACT slice can be produced. Every projection should contain a reference point produced by the fiducial object which is located above the detection plane. For creating

TACT slices one x-ray source can be used and it can be moved through several points in space to create multiple x-ray projections. These images are not much of help in the diagnosis of caries periodontal and periapical diseases.

### **Cone Beam Computed Tomography (CBCT)**

Craniofacial CBCT were developed to counter some of the limitations of conventional CT scanning devices. In craniofacial CBCT the object to be evaluated is captured as the radiation falls onto a two-dimensional retractor. This simple difference allows a single rotation of the radiation source to capture an entire region of interest as compared to conventional CT device where multiple slices are stacked to obtain a complete image. The cone beam also produces a more focused beam and considerably less scatter radiation compared to conventional fan shaped CT devices (Figure 2). CBCT produces a cone shaped beam of radiation and the beam rotates around the patient. The computer reconstruction of the image is obtained by software algorithms. Both the x-ray source and the detector are able to move around the patients head and create a sequential 2 dimensional image. Using computer software a 3 dimensional image is created<sup>17</sup>. The radiation exposure depends on the field of view, exposure time, voltage and amperage. It helps in imaging and visualization of impacted tooth, TMJ morphology and diseases associated with it, assessment of upper airway, extent of root resorption, assessment bone morphology, ankylosis of teeth<sup>18</sup>.

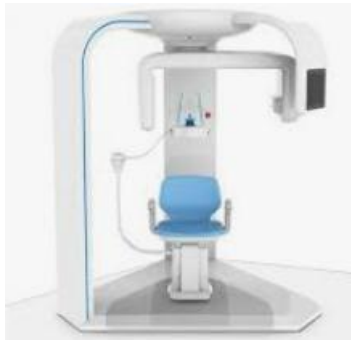

Figure 2. CBCT machine

### **Digital Cephalometry**

Cephalometry is a vital tool in orthodontics for evaluation of craniofacial complex, determination of morphology and growth, diagnosis of anomalies forecasting future relationship, planning treatment and evaluating the results of growth and effects of treatment. Cephalometrics remains the only quantitative method that permits investigation and examination of the spatial relationship between both cranial and dental structures. The lateral cephalogram provide information regarding skeletal, dental, and soft tissue morphology as well as relationship between these structures<sup>19</sup>. The use of lateral cephalograms in research includes

- Quantifying craniofacial parameters in individuals as well as a population of individuals
- Distinguishing normal from abnormal.

- Comparing treated samples to untreated controls.
- Differentiating populations as homogenous or mixed, and assessing the change of pattern over time.

The cephalometric measurements from the 3D cephalometry provide a much more valuable tool in assessing growth and the effects of orthodontic treatment. A plethora of software's is available to clinician to choose from –

- Vistadent
- Dolphin
- Quick ceph
- Dentofacial Planner
- Vixwin software
- Dr ceph
- Ortho plan
- Ceph x
- Orthoviewceph

### **Conventional tomography**

Developed by Hounsefield in 1972. Computed tomography generates an image with the help of a computer. By using multiple slices of an image it helps to give 3 dimensional form of an image. But the soft tissue contrast produced by the CT is not that efficient<sup>20</sup>.

### **Micro computed tomography (Micro CT)**

Gary Yip, Paul Schneider, and Eugene W. Roberts reported about the usefulness of micro computed tomography in orthodontic diagnosis. It evolved as a successor to routine histological sectioning and bone assessment using micro radiographic techniques. Micro CT is a new dental technology to detect subtle changes in bony structures in relation orthodontic implants, dentofacial orthopaedics and normal orthodontics. They help to assess the modelling and remodelling of bone in mineralized tissues. This imaging technology is a major breakthrough in dental imaging as it helps to evaluate the supporting bone around dental implants<sup>21</sup>.

### **Multi detector CT**

It is a form computed tomography imaging for diagnostic imaging. It uses two dimensional array of detector elements. Thus it helps to acquire multiple thin slices and forms faster CT image. Special algorithms allow multiplanar reformation of 3 dimensional images and reconstruction of panoramic images. Helps in detailed assessment of pathologic malformations. It has comparatively shorter acquisition time and thus reduces the motion artefacts due to patient movement. Decreased noise and scatter radiation when compared to CBCT and higher soft tissue resolution.. It allows image creation in the axial, coronal, sagittal and oblique or curved image planes<sup>22,23</sup>.

### **Spectrophotogrammetry**

Formation and comparison of a sequence of photographic images by making use of the principle of triangulation is the basis of spectrophotogrammetry. Cameras are positioned in the space. A point  $p$  is noted in the images ( $x$  and  $y$  coordinates) for this value it is possible to determine the third coordinate that is the  $z$  axis. It is denoted as point  $b$  in the triangle knowing the angles and distance between cameras. Two different positions of the cameras to be set to determine the 3D coordinates of the points by drawing virtual lines from the intersection of the cameras to the object and thus helps to define the size and shape of the object. A 3D model is now obtained of the soft tissues in the form of point cloud. A mesh is created from this point cloud, face is reconstructed and it consists of tiny polygons. A computer is then used to process the image with the help of photogrammetric software<sup>24</sup>.

### **Stereo lithography**

Also known as rapid prototyping. It is initially used in engineering science to create replicas of objects before wide range production. It uses the technique of computer assisted designing and computer assisted manufacturing. The CAD data is transferred to stereolithographic apparatus to build the models. The stereolithographic apparatus consists of liquid photosensitive resin in a container, a model building platform and a curing ultraviolet laser. The laser beam is computer controlled and directed to the resin and, on contact, polymerizes the surface layer; when this layer is completed, a mechanical platform moves down 1 mm (or less) into the resin bath, carrying and exposing a new layer of resin, and this second layer is then cured and bonded on the previous one, in a sequential fashion this process is repeated, layer-by-layer, as necessary, until completing the stereolithographic model of the anatomical structures of interest<sup>25</sup>.

### **Oblique lateral transcranial radiography**

The oblique lateral transcranial projection visualizes the lateral part of the temporomandibular joint. No measurement of depth is obtained. It is more accurate than lateral tomography, because in lateral tomography there can be a difficulty in identification of landmarks because of displacement of condyle<sup>26</sup>. Jumean et al. has found that oblique transcranial TMJ radiographs are the accurate method of radiographically evaluating the lateral aspect of the temporomandibular joint<sup>27</sup>.

### **Sure Smile**

Recent advances in computer management 3D imaging of dentition, manipulation of complex 3D data, and robotics have resulted in a new approach to treatment<sup>28</sup>. A patient centred practice is one that delivers high-quality care with a minimum amount of patient discomfort, compliance demand and chair time and completes treatment on time.

## Procedure

The process begins with a 3D scan of patients dentition using the oro-scanner (oro matrix) a hand held scanner, this captures in real time in vivo images of dentition. The dentition is prepared for scanning by applying a thin white film, similar to articulating spot spray. It uses structured white light to generate images in rapid succession by projecting a precisely patterned grid on to the teeth. As the hand held scanner is passed over the dentition, reflected images of dentition, reflected images of a distorted grid are recorded with a video camera built into the handle of the scanner. The scanner is passed over the dentition in a rocking motion to allow visualization of all tooth surfaces, including undercut areas. The entire process takes about 1½ minutes per arch. The image is reference independent; meaning the image capturing process is not affected by the movement of patient or scanner. The scanner is placed in a mobile care smile cart that rolls from chair to chair. During the scanning stage, the multiple and overlapping images go to the computer. With sophisticated data registration and management techniques, the images are processed and the computer model is created. The teeth are then compared with teeth in a library of dental morphology. Information voids in the scan are filled with data from the library to further refine models.<sup>29,30</sup>

## Advantages of Sure Smile<sup>29</sup>

- Undesirable tooth movement may be reduced.
- Arch-wire selection errors may be reduced.
- Bracket positioning errors may be reduced.
- Bonding adhesive thickness errors can be reduced.

## Conclusion

These advancements can be utilized in all departments of dentistry for maintaining patient records. These digital records also improve storage, access, conservation, communication with patient and duplication capabilities regarding records. But these still have some limitations. Researchers and developers are striving hard continuously to make dental practice easier worldwide. Their efforts and dedications towards these advancements are appreciable and hope they continue to move forward with further technological advancements.

## References

1. MorreesC F, Gron A M. Principles of orthodontic diagnosis. Angle orthod 1966;6(3):25-62
2. Shah N, Bansal N, Logani A. Recent advances in imaging technologies in dentistry. World J Radiol 2014; 6(10): 794-807
3. Mok K H Y, Cooke M S.Space analysis a comparison between sonic digitization and (digigraph workstation) and digital caliper. European journal of orthodontics1998;20:653-661
4. Wolfaardt J, King B, Bibb R, Verdonck H, de Cubber J, Sensen CW, *et al.* Digital technology in maxillofacial rehabilitation. In: Buemer J, editor. Textbook of Maxillofacial Rehabilitation: Prosthodontic and Surgical

- Management of Cancer Related, Acquired, and Congenital Defects of the Head and Neck. 3<sup>rd</sup> ed. Illinois, USA: Quintessence Publishing Co, Inc; 2011.
5. Wohlers T. Wohlers Report: State of the Industry, Annual Worldwide Progress Report. Fort Collins, CO.: Wohlers Associates, Inc.; 2008
  6. Silva JV, Gouveia MF, Santa Barbara A. Rapid prototyping applications in the treatment of craniomaxillofacial deformities-utilization of bioceramics. *Key Eng Mater* 2004;254-256:687-90.
  7. Winder J, Bibb R. Medical rapid prototyping technologies: State of the art and current limitations for application in oral and maxillofacial surgery. *J Oral Maxillofac Surg* 2005;63:1006-15.
  8. Faber J, Berto PM, Quaresma M. Rapid prototyping as a tool for diagnosis and treatment planning for maxillary canine impaction. *Am J Orthod Dentofacial Orthop*.2006;129:583-9
  9. Choi JY, Choi JH, Kim NK, Kim Y, Lee JK, Kim MK, *et al*. Analysis of errors in medical rapid prototyping models. *Int J Oral Maxillofac Surg*.2002;31:23-32.
  10. Gateno J, Xia J, Teichgraeber JF, Rosen A, Hultgren B, Vadnais T. The precision of computer-generated surgical splints. *J Oral Maxillofac Surg*.2003;61:814-7
  11. Daron R. Stevens, Carlos Flores-Mir, Brian Nebbe, Donald W. Raboud, GiseonHeo, and Paul W. Major Validity, reliability, and reproducibility of plaster vs digital study models: Comparison of peer assessment rating and Bolton analysis and their constituent measurements. *Am J Orthod Dentofacial Orthop*.2006;129:794-803
  12. McClure SR, Sadowsky PL, Ferreria A, Jacobson A. Reliability of digital versus conventional Cephalometric radiology: A comparative evaluation of landmark identification error. *Semin Orthod*. 2005; 11: 98-110.
  13. Joffe L. Current products and practices Orthocad: Digital models for a digital era. *J Orthod*. 2004; 31: 344 -347.
  14. Ronald Redmond W. Digital models: A new diagnostic tool. *J Clin Orthod*. 2001; 35: 386-388
  15. James Mah, Martin Freshwater. The Cutting Edge. *J Clin Orthod*. 2003; 37: 101-103.
  16. Webber RL, Horton RA , Tyndall DA and Ludlow JB. Tuned-aperture computed tomography (TACT™). Theory and application for three-dimensional dento-alveolar imaging. *Dento maxillofacial Radiology*.1997 ;26: 53-31
  17. Genevive L. Machado. CBCT imaging – A boon to orthodontics. *The Saudi Dental Journal* (2015): 27:12–21
  18. Iury Oliveira Castro, Carlos Estrela, José Valladares-Neto. Orthodontic treatment plan changed by 3D images. *Dental Press J Orthod* 75 2011 Jan-Feb;16(1):75-80
  19. Gregory,I, Stuart,A, Arthur,J, William,D. Comparison between traditional 2-dimensional cephalometry and a 3-dimensional approach on human dry skulls. *Am J Orthod Dentofac Orthop*. 2004; 126: 397-409.
  20. Quintero J C et al. Craniofacial imaging in orthodontics: historical perspectives, current status and future and future developments. *Angle Orthod* 1999;69;(6)491-506
  21. Gary Yip, Paul Schneider, and Eugene W. Roberts. Micro-Computed Tomography: HighResolution Imaging of Bone and Implants in Three Dimensions. *Semin Orthod*.2004;10:174-187



22. Shweel M, Amer MI, Fathy El-shamanhory A. A comparative study of cone-beam CT and multidetector CT in the preoperative assessment of odontogenic cysts and tumors. *The Egyptian Journal of Radiology and Nuclear Medicine*. 2013;44(1):23-32.
23. Mortelet KJ, McTavish J, Ros PR. Current techniques of computed tomography. Helical CT, multidetector CT, and 3D reconstruction. *Clin Liver Dis* 2002;6:29-52.
24. Deli et al. Three-dimensional methodology for photogrammetric acquisition of the soft tissues of the face: a new clinical-instrumental protocol. *Progress in Orthodontics* 2013: 14;32.
25. Pessa J E. The potential role of stereolithography in the study of facial aging. *Am J Orthod Dentofacial Orthop* 2001;119:117-20
26. Rosenquist et al, Accuracy of the Oblique Lateral Transcranial Projection, Lateral Tomography, and X-Ray Stereometry in Evaluation of Mandibular condyle displacement. *J oral Maxillofac surg* 1988;46:862- 867.
27. Keesler J T et al. A transcranial radiographic examination of the temporal portion of the temporomandibular joint. *Journal of Oral Rehabilitation*, 1992 ;Vol 19:71-84
28. Mah. J, Sachdeva R. Computer assisted orthodontic treatment: The sure smile process. *Am J Orthod Dentofac Orthop*. 2001; 120: 85-87.
29. Sachdeva RC. SureSmile technology in a patient--centered orthodontic practice. *J Clin Orthod*. 2001; 35: 245-253.
30. Kaur S, Singh R, Kaur S. Digital revolution in orthodontic diagnosis. *Annals of Geriatric Education and Medical Sciences*, July-December, 2017;4(2):38-40