

**How to Cite:**

Verma, S., Gulati, M., & Kumar, M. S. (2021). Hinge axis recording of the temporomandibular joint. *International Journal of Health Sciences*, 5(S2), 274–280. <https://doi.org/10.53730/ijhs.v6nS3.5771>

# Hinge axis recording of the temporomandibular joint

**Sumit Verma**

PG student 3<sup>rd</sup> year, Dept.of Prosthodontics and Crown & Bridge, Desh Bhagat Dental College and Hospital, Mandi Gobindgarh

**Manmeet Gulati**

Prof. and Head, Dept.of Prosthodontics and Crown & Bridge, Desh Bhagat Dental College and Hospital, Mandi Gobindgarh

**Manmohit Singh Kumar**

Professor, Dept.of Prosthodontics and Crown & Bridge, Desh Bhagat Dental College and Hospital, Mandi Gobindgarh

**Abstract**--The temporomandibular joint is called as ginglymoarthrodial joint. It is a complex joint in which two basic movements of the mandible can be distinguished. Rotary or hinge like movement taking place between the articular disk and condyle in the lower compartment of the temporomandibular articulation. Various studies have shown that an arbitrary location of the hinge axis is an acceptable alternative to its accurate location. With the availability of easy to use ear piece facebow, locating and transfer of hinge axis to the articulator is an easy and quick procedure. Precision is the key to prosthodontics and it is thus imperative that restorations are made as accurately as possible.

**Keywords**--hinge axis, recording, temporomandibular.

**Introduction**

The temporomandibular joint is called as ginglymoarthrodial joint. It is a complex joint in which two basic movements of the mandible can be distinguished. Rotary or hinge like movement taking place between the articular disk and condyle in the lower compartment of the temporomandibular articulation. Prior to the 1920s, Snow, Gysi and others were aware of the existence and importance of an opening and closing axis. Yet their methods were not advanced enough to exactly pinpoint the location of the hinge axis from this the concept of Hinge axis comes into consideration. The hinge axis is an imaginary line that passes horizontally

through the rotation center of both condyles to the right and left when the condyles are in their most distal, unstrained, retruded positions in their respective fossae. It is a position where the condyles can demonstrate pure rotary motion around the horizontal axis of rotation during the opening and closing movements of the mandible, thus the name hinge axis or terminal hinge axis. The Glossary Prosthodontic terms defines Hinge axis as an imaginary line passing through the two mandibular condyles, around which the mandible can rotate without translatory motion (Fig no. 1)

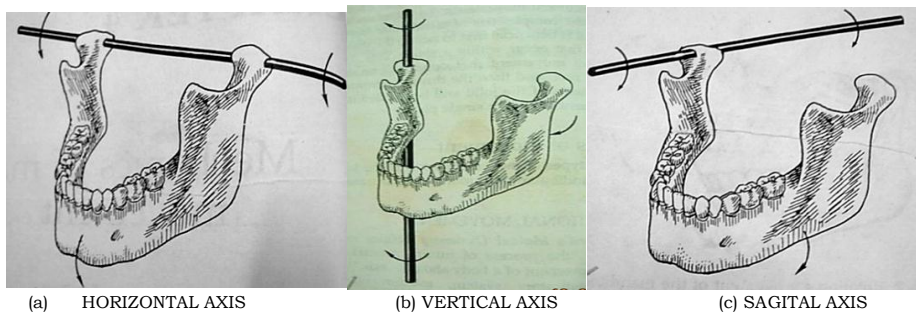


Fig 1. Axis of rotation

The temporomandibular articulation is a complex joint in which two Translatory or sliding movement between the temporal bone and articular disc in the upper compartment of the temporomandibular articulation.

### Various schools of thought regarding hinge axis

From early experiments there have evolved four main schools of thought regarding the horizontal axis. They are as follows.

- *Group I: Absolute location of the axis.*  
There are those who believe that there is a definite transverse axis and it should be located as accurately as possible. McCollum, Stuart & Lucia believe that the hinge axis is a component of every masticatory movement and cannot be disregarded. The investigators who endorsed this concept have established a repeatable point of reorientation from which the above information and relationships may be obtained.
- *Group II: Arbitrary location of the axis.*  
The second group includes those who believe that the arbitrary location is not worth the added effect. Craddock for one stated that the search for the axis, in addition to being troublesome, is- of no more than academic interest. Though, this group believed in location of the axis.
- *Group III Non believers in the transverse axis locations.*  
Then, there is a third group who believes it is impossible to locate the terminal hinge position with accuracy. Lauritzen and Watford confirm this, and Kurth and Feinstein, using an articulator and a range of 2mm. \The opening and closing movement was limited to approximately 10 to 11 degrees. Borgh and Posselt could not record the axis on a modified Hanau H articulator without errors. The errors amounted -to 1 to 5mm at a 10 to 15 degree opening.

- Beck has proposed another reason for doubting the validity of the hinge axis location. He claims that there can be many compensating movements of the condyle other than pure rotation, and that these compensating movements are movements of translation and side shift that are integrated with the movement of rotation. He concludes that the opening and closing movements of an articulator, which is about one axis only, cannot repeat the opening and closing hinge movement of the mandible, together with its fragmentary movements. Therefore, an arbitrary terminal hinge position would or could be just as accurate as one located with a kinematic face-bow.
- *Group IV Split axis rotation*  
These are believers of the Transographic theory. They believe in the "split axis" with which each condyle rotates independently of the other. Slavens states "by definition, an axis is always a line, never a point. Again, by definition, an axis is invariably perpendicular to the path or plane of rotation it controls. That means that the transverse axis of each joint is a line and both of these are perpendicular to the same plane of opening and closing rotation. The significance of the fact that these two transverse axes are never symmetrically positioned in the same head becomes 'inescapable. Being perpendicular to the same plane of rotation, they are parallel to each other even though asymmetrically positioned and, by definition parallel lines never meet".

### **Controversies regarding hinge axis**

- Existence and accurate location of hinge axis
- Single or multiple hinge axis exists.
- Clinical usefulness regarding location of hinge axis.
- Whether and arbitrary point can be satisfactorily substituted for kinematic axis. (Gordon, 1984).

### **Location and transfer of the hinge axis using device**

Different methods have been used to locate and transfer the hinge axis to the articulator. The first actual kinematic location was evolved through the California Gnathologic society under the leadership of McCollum and credit for the idea of the mechanical location of an axis was given to Dr. Robert Harlan. The first location employed a modified Snow face-bow and consumed as much as 8 hours. The transverse axis of rotation can be located by use of an instrument called the 'Face-Bow'. According to GPT-7: A caliper-like instrument used to record the spatial relationship of the maxillary arch to some anatomic reference point or points and then transfer the relationship to the articulator. Parts of a Face-Bow (Fig no.2):

- U-shaped frame: Large enough to extend from the region of the TMJ to a position 2-3 inches in front of the face and wide enough to avoid contact with the sides of the face.
- Condylar rods or earpieces: Condylar rods contact skin over the region of the TMJ, whereas earpieces are inserted into the external auditory meatus.

- Bite fork: It is attached to the occlusal rim.

- × U shaped frame work.
- × Condylar rods.
- × Bite fork.
- × Locking device
- × Orbital pointer with clamp (optional).  
Additional features & parts vary according to types & brands.

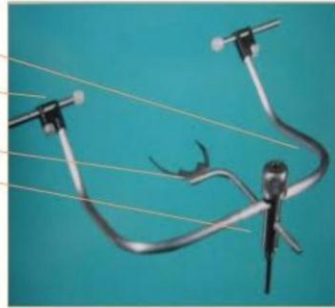

Fig. no.-2

### **Classification of Face-Bows**

#### **Arbitrary face-bow**

It relates the maxilla to the exact or the arbitrary position of the condylar axis and transfers this relationship to the articulator. Use arbitrary or approximate points on the face as posterior reference points. The condylar rods are positioned on these predetermined points during the facebow transfer procedure. Most widely used type of face-bow and are sufficient for fabrication of most complete dentures, fixed partial and removable partial dentures. Many studies have shown that a small error in location will have a negligible effect at the occlusal level. Furthermore, the 'Realeff' of the oral tissues make the exact location and transfer of the hinge axis unnecessary. (fig no. 3)

#### **Types of arbitrary face-bow**

- Fascia type: the hinge axis or posterior reference point is 13mm anterior to the external auditory meatus and the anterior reference point is the orbitale. The face-bow has a pointer that can be positioned to the posterior reference point.
- Earpeice type: The posterior reference point is the external auditory meatus and the anterior reference point is the orbitale. The earpieces engage into the posterior reference points.

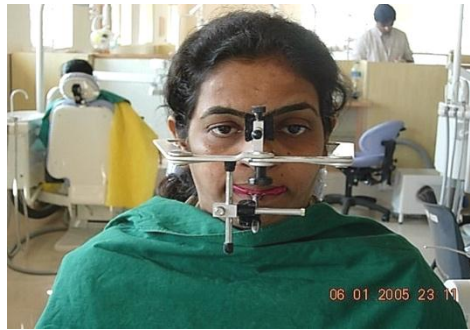

Fig. 3

**Kinematic face-bow**

The hinge axis face-bow with adjustable caliper ends that locates the exact axis of rotation of the condyles. Hinge axis is determined by the clutch. It uses terminal hinge axis and inferior orbital rim or reference points. This method is not commonly used method of locating hinge axis because of complexity in procedures. It is used only in fixed prosthesis with reorganized approach. This device consists of clutch/bite fork, cross bar, stud, axis indicator, graph pad and universal clamp/ screws. (fig.no. 4 )

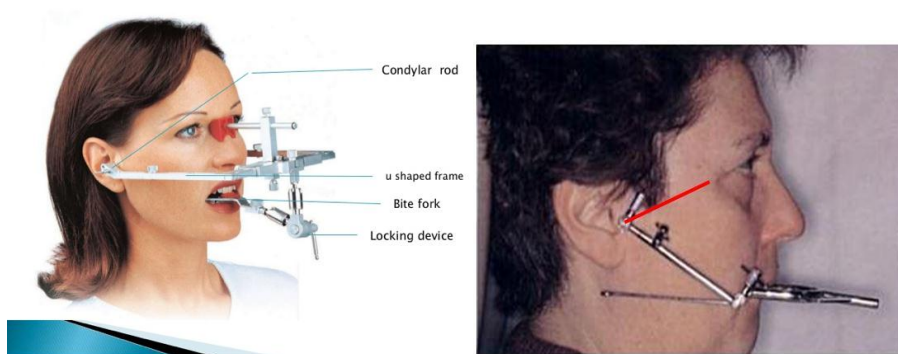
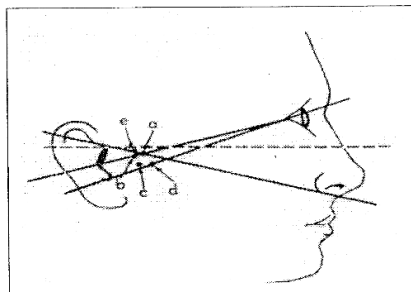
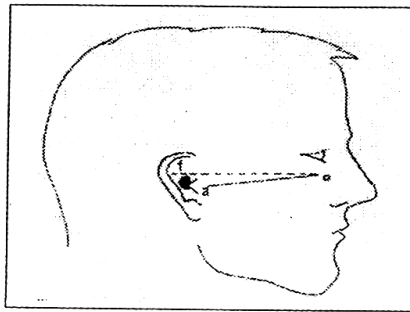


Fig. 4



Arbitrary axis points: a. Beyron's point; b. Gysi's point; c. Bergstrom's point; d. Teteruck and Lundeen's point; and e. Experimental point.  
Broken line represents Frankfort horizontal plane

Fig.5



Orbitale (o), axis - orbital plane  
(a - o) and Frankfort horizontal  
plane (f - o)

**Fig. 6**

It requires more chair side time because of the use of extendable condylar shafts on the articulator; since the articulator's intercondylar distance is fixed. Rarely used for routine prosthodontic procedures .

### **Clinical significance of hinge axis & its use**

The biological significance of recording hinge axis is maintain the guiding mechanism for opening and closing movements in the cases of fully edentulous patients. The proprioceptive signals are absent due absence of periodontal ligament and certain receptor are present on capsule of temporomandibular joint. These signals are activated only when condyles are in the centric relation position or the hinge position which guide the mandible during movements (sicher, 1956). Therefore by placing the condyles in centric position, we can make hinge axis on a constant point to both maxilla and mandible. The terminal hinge axis plus one anterior reference point serves to locate the maxilla in space. The maxilla is therefore oriented spatially in the articular region in the same position as it occurs in patient's head. Thus the location of terminal hinge axis serves to orient the maxilla and to record the static starting point for functional mandibular movement.

### **Conclusion**

The hinge axis concept is still controversial inspite years of study. The various schools of thought regarding its existence and location often leads to doubt regarding its application in everyday clinical practice. Various studies have shown that an arbitrary location of the hinge axis is an acceptable alternative to its accurate location. With the availability of easy to use ear piece facebow, locating and transfer of hinge axis to the articulator is an easy and quick procedure. Precision is the key to prosthodontics and it is thus imperative that restorations are made as accurately as possible. This is best achieved by the use of hinge axis concept and thus it should be incorporated into routine clinical practice to achieve optimum results.

**References**

1. Zakaria R. Ma'an, Huwaizi Al F. Hussain and Alnakkash A. Widad(2011) A comparison between arbitrary and kinematic mandibular hinge axis location in full mouth rehabilitation patients .
2. Bainiwal Deepika and Dhiman Meenu (2018) Hinge axis recording “THE ESSENTIAL NEED IN PROSTHODONTICS”
3. Mutneja Puneet (2015) methods of recording mandibular movements – A review article.
4. Singh Sunint , Rehan Sharique , Palaskar Jayant, Mittal Sanjeev(2017) Hinge axis –location , clinical use and controversies.
5. Craddock F.W. and Symmons H.F. : Evaluation of the face-bow. J. Prosthet. Dent. 2: 633-642, 1952.
6. Thure Brandrup-Wongnsen : The face-bow. Its significance and applications. J. Prosthet. Dent. 3: 619-629, 1953.
7. Vincent R. Trapozzano and John B. Lazzari: The physiology of the terminal rotational position of the condyles in the temporomandibular joint. J. Prosthet. Dent. 17: 122-133, 1967.
8. Robert G. Schallhorn : A study of the arbitrary center and the kinematic center of rotation for face-bow mountings. J. Prosthet. Dent. 7: 162-169, 1957.
9. Ulf Posselt: Terminal hinge movement of the mandible. J. Prosthet. Dent. 7: 787-797, 1957.
10. Wienberg A. Lawrence: The transverse hinge axis : Real or imaginary. J. Prosthet. Dent. 9: 775-787, 1959.
11. Thomas E.J. Shanahan and Alexander Leff: Mandibular and articulator movements. Part III: The mandibular axis dilemma. J. Prosthet. Dent. 12: 292-297, 1962.
12. Don N. Brotman : Hinge axis: Part III. Vertical and sagittal rotational centers. J. Prosthet. Dent. 872-876, 1960.