

How to Cite:

Singh, M., Gulati, M., Kaur, G., Gupta, P., Mishra, A., & Arora, J. (2021). Single step border molding revisited: A case report. *International Journal of Health Sciences*, 5(S2), 290–294. <https://doi.org/10.53730/ijhs.v5nS2.5774>

Single step border molding revisited: A case report

Manmohit Singh

Professor Department of Prosthodontics, Desh Bhagat Dental College & Hospital, Mandi Gobindgarh

Manmeet Gulati

Professor & Head, Department of Prosthodontics, Desh Bhagat Dental College & Hospital, Mandi Gobindgarh

Gurpreet Kaur

Professor Department of Orthodontics, Desh Bhagat Dental College & Hospital, Mandi Gobindgarh

Pratik Gupta

Reader, Department of Prosthodontics, Desh Bhagat Dental College & Hospital, Mandi Gobindgarh

Aalok Mishra

Sr. Lecturer, Department of Prosthodontics, Desh Bhagat Dental College & Hospital, Mandi Gobindgarh

Jasleen Arora

Sr. Lecturer, Department of Prosthodontics, Desh Bhagat Dental College & Hospital, Mandi Gobindgarh

Abstract---The specialty of Prosthodontics has developed from the need to replace missing dentition, and associated structures. In this, the impression stage plays a very critical role, as it is the first of many stages involved in the production of the restorative procedures. This case report presents a simple, single step border molding using heavy body elastomeric impression material.

Keywords---complete denture, impression, border molding, elastomeric impression material.

Introduction

The fabrication of complete removable dentures has evolved noticeably over the last few years with the advent of new materials and a better understanding of patients' expectations. There is general agreement about one aspect of complete denture treatment: an accurate impression of the edentulous alveolar ridges and adjacent functional structures must be obtained before proceeding to fabricate the complete dentures. Without this foundation, there is no hope of providing patients with ideal function, comfort, and aesthetics. Making accurate final impression for complete dentures is a multistage process that involves a preliminary impression, a customized final impression tray and a final border impression.^[1, 2] It is important to thoroughly examine the patient's mouth and select the most appropriate impression technique. A major requirement for final impression of complete dentures is to develop the peripheral contours to accommodate normal muscular function and to ensure peripheral adaptation without allowing air penetration between the future denture base and the mucous membrane.^[3]

Advances in the accuracy of impression techniques and an increase in the methods of border molding and obtaining a posterior palatal seal were among the major innovations during 1900-1928.^[4] In recent years numerous publications states the characteristics of new materials and techniques. Some materials are more accurate and have advantage over the materials of past. Nevertheless many dentists have been reluctant to change their impression techniques and materials because any change requires learning time and loss of productivity. There are many axioms in the production of dentures that must be understood; ignorance of one axiom can lead to failure of the denture case. When the dentist is busy concentrating on the axioms, the patients feel that they should be free from the dental chair in no time. This case report explains one such time saving procedure in complete denture fabrication.

Case report

A male patient of age 80 years was referred to the Department of Prosthodontics requesting for of a new set of complete denture. The patient had been edentulous (Fig.1 a & b) for the past 4 years and had one set of complete denture made previously. The patient complained that the previous denture was loose. He reported difficulty in eating and speaking with his old dentures. He did not give any relevant medical history. The case was planned for fabrication of complete denture in balanced occlusion with an altered single step border molding technique.^[5] The preliminary impression was made using impression compound (Fig. 2) in selected edentulous trays and the diagnostic cast was poured. Special trays were fabricated after adaptation of spacer wax for making of final impression. Before making of the final impression the trays were checked for the proper extension in the oral cavity. Tray adhesive was applied on the borders of the tray, both the base and the catalyst of heavy body elastomeric impression material were kneaded according to the manufacturer's instructions and applied onto the tray borders. Tray was placed inside the oral cavity and border molding was carried out in the conventional manner (Fig 3). After the material had set tray was removed and checked for any errors if any. Similar procedure was followed

for the mandibular border molding (Fig. 4). Final impression was made using light body elastomeric impression material (Fig. 5). Beading and boxing was done using plaster pumice method and master cast was prepared on which denture was fabricated.

Discussion

One of the most important aspects of high-quality complete denture therapy occurs early in the treatment sequence. Because complete denture fabrication is an indirect restorative procedure, an analogue of the edentulous ridges must be developed to be able to proceed with denture construction in the laboratory. The method used to capture critical anatomic information for transport to the laboratory construction process involves making impressions of the denture-bearing tissues and peripheral structures and fabricating dental casts. A wide variety of impression procedures has been described for conventional complete denture therapy. Procedures vary with respect to impression materials used, the design and construction of impression trays, intended extensions of peripheral borders, pressure delivered to denture-bearing tissues, and the incorporation of oral function during impression making. The degree to which this analogue accurately represents oral contours and condition, both anatomically and functionally, determines in large part the quality of the therapeutic outcome.

Different materials that can be used to record the functional and physiologic border of the denture are low fusing impression compound, waxes, elastomeric materials, acrylic resin and tissue conditioner. The most functional and physiologic border are recorded using a materials that would continuously flow for extended period of time. In this case one step border molding technique was used. Advantages of using this technique are: a) firstly, the total time for the procedure is reduced, which saves the chair side time; b) secondly, the number of insertions of the tray is reduced to one; c) thirdly, it avoids propagation of errors caused by a mistaken in one section affecting the border contours in another. As this technique has advantages it has some disadvantages too. a) firstly, no sectional changes can be made while using this material; b) secondly, use of heavy body can produce extremely thick borders, which can makes it unacceptable for clinical use as it can affect aesthetics and retention.^[6] No doubt number of techniques and materials has been mentioned in the literature for recording of the peripheral tissue and making of secondary impression, but the use of particular technique lies on personal preference of the operator.

Conclusion

Complete denture impression can be defined as a dynamic process that can be divided into two stages: preliminary impression and final impression. The aim on each patient is to fashion the impression surface and the peripheral rolls of the complete dentures in such a way that support, retention and stability of the denture are maximized. Although conventional approaches to impression making in complete denture therapy have served the profession well over the years, the relatively recent appearance of new materials and devices provides an opportunity to rethink conventional wisdom.

References

1. Heartwell C M, Rahn A O. Syllabus of complete dentures. 4th ed. Philadelphia: Lea & Febiger; 1986.
2. Zarb A Z, Bolender C L, Hickey J C, Carlsson GE. Boucher's prosthodontic treatment for edentulous patients. 10th ed. St Louis: C V Mosby; 1990.
3. Suenaga K, Sato T, Nishigawa G, Minagi S. Relationship between size of complete foundation area and resorption of alveolar ridge in the edentulous mandible. *J Oral Rehabil* 1997; 24:315-319.
4. Zinner I D, and Sherman H An analysis of the development of complete denture impression techniques. *J of Prostht Dent* 1981; 46(3) 242-49
5. Smith D E, Toolson L B, Bolender C L, Lord JL. One-step border molding of complete denture impressions using a polyether impression material. *J Prosthet Dent*. 1979 ;41(3):347-51.
6. Patel J R, Sethuraman R, Chaudhari J. Comparative evaluation of border morphology produced by three different border molding materials. *Int. Journal of Contemporary Dentistry* 2010;1(3): 82-88
7. *Journal of Contemporary Dentistry* 2010;1(3): 82-88

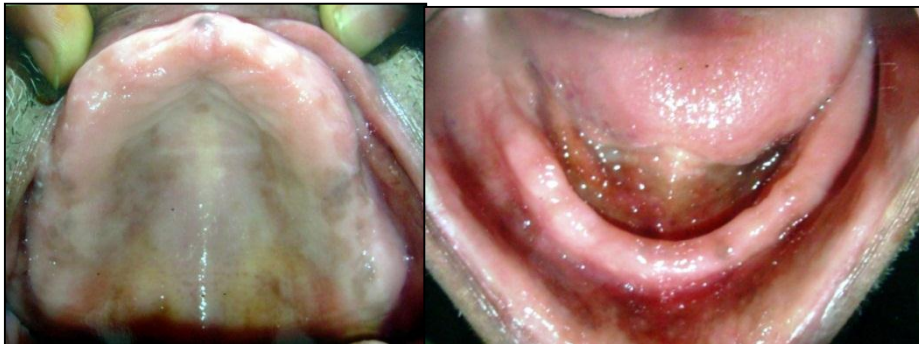

Fig 1. Edentulous arches a) Maxillary b) Mandibular



Fig. 2. Preliminary Impression

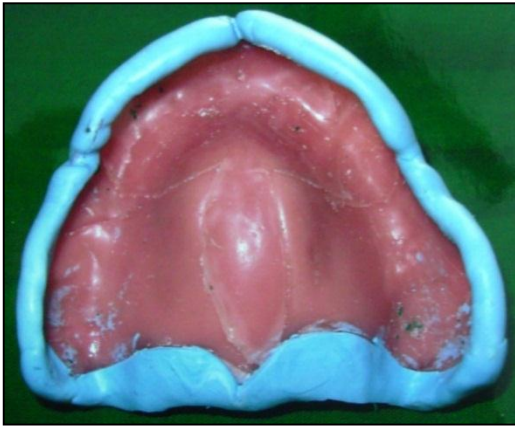

Fig. 3

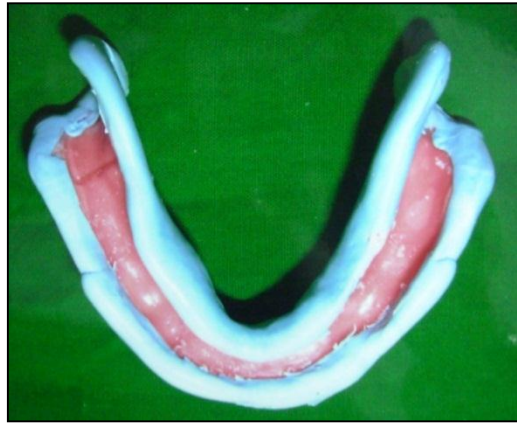


Fig. 4

Fig.3 &4: Single Step Border Molding done on Maxillary & Mandibular Special Tray Using Elastomeric Impression Material

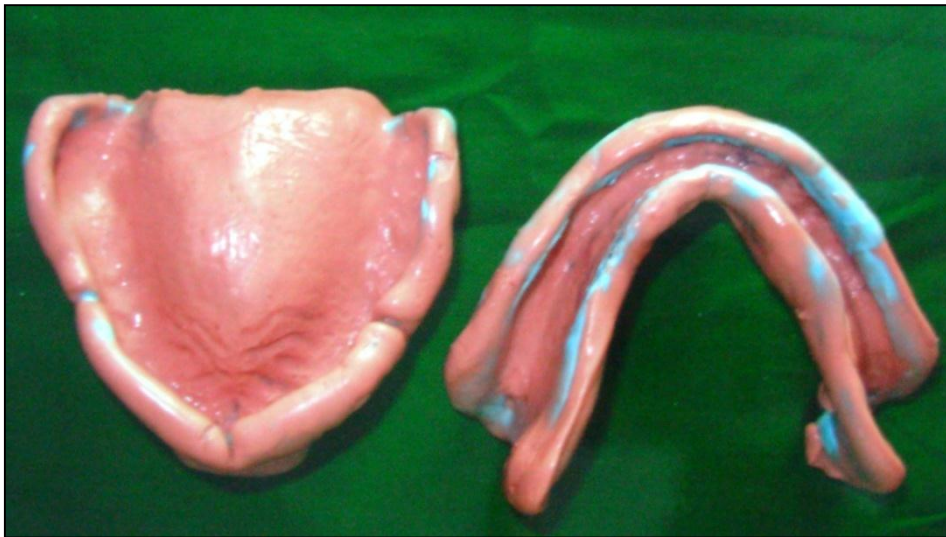

Fig. 5. Secondary Impression Made Using Light Body Impression Material