

**How to Cite:**

Yakubov, Y. K., Tillyashaikhov, M. N., Soipov, B. D., Sabirov, S. S., & Tuyiev, K. N. (2022). Combined drainage of the bilic and virsung ducts for the prevention of postoperative complications during pancreatoduodenal resection. *International Journal of Health Sciences*, 6(S1), 4184–4190. <https://doi.org/10.53730/ijhs.v6nS1.5821>

## **Combined drainage of the bilic and virsung ducts for the prevention of postoperative complications during pancreatoduodenal resection**

**Yakubov Yu.K.**

Republican Specialized Scientific and Practical Medical Center of Oncology and Radiology

**Tillyashaikhov M.N.**

Republican Specialized Scientific and Practical Medical Center of Oncology and Radiology

**Soipov B.D.**

Republican Specialized Scientific and Practical Medical Center of Oncology and Radiology

**Sabirov S.S.**

Republican Specialized Scientific and Practical Medical Center of Oncology and Radiology

**Tuyiev Kh.N.**

Republican Specialized Scientific and Practical Medical Center of Oncology and Radiology

**Abstract**---Pancreatoduodenal resection is a standard procedure usually performed for benign and malignant tumors of the biliopancretoduodenal zone. The development and implementation of new technologies and techniques has made it possible to significantly reduce postoperative mortality to 5% over the past decade in specialized institutions around the world. But the number of postoperative complications still remains high - from 30% to 60% according to different authors; such as postoperative pancreatic and biliary fistulas, intra-abdominal infection, and late gastric emptying. Among them, pancreatic and biliary fistulas are the most frequent serious complications after pancreatoduodenal resection with a frequency of up to 30-60%, which is the main cause of postoperative mortality. In this work, we analyzed the internal intraoperative combined drainage of the pancreatic and bile ducts in 7 patients.

**Keywords**---tumors, pancreas, pancreatoduodenal resection, drainage, duct, pancreato-jejuno anastomosis, hepatico-enteroanastomosis, pancreatic fistula.

## **Introduction**

It is known that for tumors of the biliopancreatoduodenal zone, operations of pancreatoduodenal resection (PDR) are performed with the formation of gastroentero-, pancreatoentero- and hepaticoentero-anastomoses. The technique for performing all stages of the standard PDR has now reached a certain limit and is well represented in the literature. PDR is a surgical intervention associated with the risk of postoperative complications, primarily the failure of hepaticoentero- and pancreatoentero-anastomoses. Pancreatic fistula is the "Achilles' heel" of this operation. The main reason for the development of complications is a violation of the tightness between the pancreas, bile ducts and the small intestine, and therefore, the most important element in preventing complications from the stump of the pancreas and biliary tract, and providing favorable conditions for the healing of the anastomosis, its tightness is adequate decompression of the ductal system stump of the gland and biliary tract in the early postoperative period, which is provided by temporary external, external-internal or internal drainage of the pancreatic stump and biliary tract. The development of many technological methods and the introduction into clinical practice of various drug methods for their prevention have led to a decrease in postoperative mortality, however, postoperative complications are observed in up to 30-60% of cases.

Known methods of external drainage of the pancreatic stump and bile ducts have common drawbacks that significantly reduce the effectiveness of their practical application. When using methods of external drainage of the pancreatic stump, there is no possibility of sanitation of the ductal system of the pancreas, the need for which is obvious due to the important role of intraductal mucoprotein precipitation in the genesis of acute postoperative pancreatitis. Known drainage systems are often obturated with ductal mucus, highly viscous secretions, and precipitates that are abundant intraductally as a result of direct surgical trauma to the pancreas. Under these conditions, the drainage system becomes an insurmountable obstacle to the outflow of pancreatic secretions. It is not possible to perform mechanical sanitation of the drainage systems and the main pancreatic duct of the pancreatic stump and bile ducts using known methods of draining the pancreatic stump of the pancreas, and an attempt to implement it will inevitably lead to an increase in intraductal pressure, induction of acute inflammation in the pancreatic stump, with possible violation integrity of the pancreatodigestive anastomosis. The presence of a long-term obstruction to the outflow of pancreatic secretions (with tumors of the periampullary zone or chronic complicated pancreatitis) often leads to dramatic changes in the rheological properties of the secretion, up to intraductal deposition of calculi. Intraoperative sanitation of the ductal system in most cases is incomplete, fragments of calculi, as a rule, continue to profusely drain through the drainage, while there is a high risk of obturation of the drainage lumen or, if large, remain in the ductal system, which becomes a possible cause of future morphofunctional disorders of the pancreatic stump glands.

The disadvantages of external drainage are the loss of about 2 liters (1.2 liters of pancreatic and 0.8 liters of bile) of fluids, proteins, trace elements, etc., which leads to a violation of the rheology of homeostasis and a deterioration in the general condition of the patient. To prevent shortcomings in external drainage, reduce postoperative complications and prevent the development of peritonitis, we proposed a method of combined internal drainage of the bile and Wirsung ducts with stents or catheters that can be easily removed in the postoperative period.

A method for combined drainage of the pancreatic and bile ducts during pancreatoduodenal resection, including decompression of the Wirsung duct with a silicone stent or catheter, fixation of the drainage with sutures, formation of an end-to-side pancreatoenteroanastomosis, characterized in that the Wirsung duct is first decompressed, the stent or catheter is fixed in the anastomosis with one suture of the inner row, the free end of the stent or catheter is freely placed in the small intestine, and then an end-to-side hepaticoenteral anastomosis is simultaneously performed with drainage by a second catheter with a diameter corresponding to the diameter of the bile duct, the catheter is inserted at one end into the lumen of the bile duct, fixed it in the created hepaticocentric anastomosis with one suture, and with the other through the Brown anastomosis, is brought into the cavity of the small intestine, and a month later the stents or catheters are removed with an endoscope.

### **Materials and Methods**

In the period from 2018 to 2021, 13 patients underwent pancreatoduodenal resection with a diagnosis of malignant tumors of the biliopancreatoduodenal zone in the Department of Abdominal Surgery of the RSNPMCOR of the Republic of Uzbekistan. In all patients in the reconstructive stage of the operation, combined drainage of the pancreatic and bile ducts was performed.

To determine the resectability of the tumor process, all patients underwent a three-phase MSCT in the angiographic mode - portal and pancreatic phases. The relation of the tumor to the main vessels was assessed, primarily the relation to the superior mesenteric vein and to the portal vein in the portal phase, as well as to the superior mesenteric artery in the arterial phase, respectively. In both TNM groups, we excluded patients with T4, i.e. when there was invasion of the tumor into the main vessels. By gender in the main group of men - 7, women - 6. The age of patients is from 49 to 72 years.

With the development of obstructive jaundice in the preoperative period, 8 patients underwent drainage of the bile ducts. The level of the oncomarker CA 19-9 was also studied, (n=13) the value of the oncomarker was higher than the reference value (40 U/ml). In cases of adenocarcinoma, an increase in this marker was observed. Histological examination revealed adenocarcinoma in 9 patients, and neuroendocrine tumor in 4 patients.

### **Results and Discussion**

All PDR operations were performed by a team of surgeons specializing in onco-abdominal surgery. The method of combined drainage of the pancreatic and bile

ducts during pancreatoduodenal resection is carried out as follows: Under general combined intubation anesthesia, with the patient in the supine position, upper and middle laparotomy is performed in layers with a 25 cm incision. An audit is performed. The stages of the operation of pancreatoduodenal resection are performed according to the generally accepted method. To achieve internal drainage before the reconstructive stage of the operation, one end of the silicone catheter was inserted 3-5 cm into the duct of the pancreatic stump with side holes, and the other end, about 35 cm long, was left in the intestinal lumen through the anastomosis. The diameter of the catheter depended on the diameter of the pancreatic duct; the largest stent that could be inserted into the pancreatic duct was used. Catheter migration was prevented by a fixation suture, which secured the catheter to the wall of the pancreatic duct at the anastomotic site with a single absorbable suture. Care was taken to ensure that there were no lateral holes in the part of the catheter in the jejunum. After that, they proceed to the stage of reconstruction of the pancreas in the form of pancreatoenteroanastomosis (Fig. 1). The pancreas and small intestine are connected according to the "end-to-side" scheme (4), a series of atraumatic sutures are applied. The Wirsung duct (7) is decompressed with a silicone stent or catheter. The stent or catheter is fixed in the anastomosis with one suture of the inner row. The free end of the stent or catheter is freely placed in the small intestine 4-5 cm below the Brown anastomosis. Further, at the same time, at the moment of creating a hepaticoenteric anastomosis (2), an angiographic conductor is inserted into the lumen of the biliary tract and, along the conductor, using a rigid cannula, one end of a polyethylene catheter or stent (1) is installed with a diameter corresponding to the diameter of the bile duct. Then, the conductor is removed. The end of the catheter (1) is fixed with one suture to the hepaticoenteric anastomosis (2). The second one is free, the end of the catheter (1) is brought out through the created Brown anastomosis (6) into the cavity of the small intestine. The catheter is installed for a period of one month, after which it is removed endoscopically.

In the postoperative period, all patients received an infusion to maintain fluid and electrolyte balance. To maintain the nutrition of patients, total parenteral nutrition was used throughout the day, and antibiotic therapy was performed to prevent infectious complications. All patients in the postoperative period were injected with somatostatin analogues 3 times a day for one week, as well as proteolytic enzyme inhibitors, which were also administered for at least a week, depending on the level of amylase in the blood.

The implementation of the method of combined drainage of the pancreatic and bile ducts during pancreatoduodenal resection is illustrated in the figure. On fig. No. 1 shows a scheme of combined drainage of the pancreatic and bile ducts after pancreatoduodenal resection, where 1 - drainage of the bile duct with a silicone stent or catheter, 2 - hepatoenteroanastomosis, 3 - plug of the ascending branch of the small intestine, 4 - pancreatoenteroanastomosis, 5 - gastroenteroanastomosis, 6 - Brownian anastomosis, 7 - drainage of the pancreatic duct with a silicone stent or catheter.

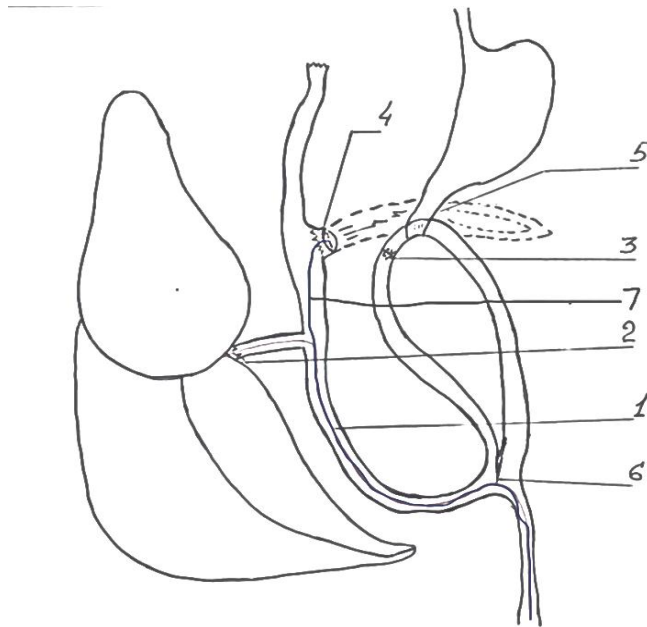


Fig.1.

Intra-abdominal infection occurred in 3 patients. When studying the spectrum of the bacteriological nature of the sowing of the drainage excretion, E.Coli was found. These patients underwent antibiotic therapy against E.Coli. Pancreatic fistula in one case was treated conservatively for 25 days with the use of pancreatic secretion blockers and enzyme inhibitors. No deaths were observed. The hospital stay in the postoperative period was  $12 \pm 2$  days.

Decompression of the Wirsung duct through a silicone stent or catheter from pancreatoenteroanastomosis into the small intestine allows the outflow of pancreatic juice to go directly to the small intestine, while maintaining the full volume of 1.5-2 liters of pancreatic juice necessary for digestion, makes it possible to increase the time (month) finding a catheter in the pancreatoduodenal zone with maximum prevention of pancreatoenteroanastomosis failure. Also, the internal location of the catheter can reduce discomfort and inconvenience for the patient after pancreatoduodenal resection. Performing internal drainage eliminates the sanitation of the drainage tube, since the secreting fluid without an obstacle is released by gravity and does not create an obstacle to the outflow of pancreatic secretions.

Drainage of the bile duct through a silicone stent or catheter from the hepaticenteric anastomosis into the small intestine allows the outflow of bile involved in digestion in full (0.8-1.0 liters) into the small intestine, preventing bile from entering the abdominal cavity, the development of peritonitis and bleeding.

## Conclusion

Simultaneous drainage after pancreaticoduodenal resection does not require repeated intervention to install the catheter, it allows a month later, in a minimally invasive way, to remove the catheter from the hepaticocentric anastomosis area with maximum prevention of failure. Also, the internal location of the silicone stent or polyethylene catheter does not cause side effects, it allows to reduce intra-intestinal pressure, discomfort and inconvenience in the patient after pancreatoduodenal resection. Removal of a polyethylene catheter in the postoperative period - a month later, with an endoscope is less traumatic. Removal of a silicone stent or catheter in the postoperative period - a month later, with an endoscope is less traumatic.

The method allows to significantly reduce the risk of failure of pancreatocentric and hepaticocentric anastomoses, the formation of postoperative fistulas, the development of peritonitis and other postoperative complications. This technique improves the immediate results and the occurrence of complications, but does not affect the long-term results of treatment. Thus, the proposed method is the method of choice in the treatment of patients with tumors of the pancreatoduodenal zone.

## Literature

1. Malignant neoplasms in Russia in 2017 (morbidity and mortality) / Ed. HELL. Kaprina, V.V. Starinsky, G.V. Petrova. - M., 2018. - P.4-5.
2. Kotelnikov A.G., Patyutko Yu.I., Tryakin A.A. Clinical guidelines for the diagnosis and treatment of malignant tumors of the pancreas. - M., 2014. - P. 44.
3. Tseimakh A.E. Surgical treatment using minimally invasive technologies and photodynamic therapy of malignant neoplasms of the hepatopancreatobiliary zone complicated by obstructive jaundice: Abstract of the thesis. dis. ... cand. honey. - Barnaul, 2020. - 21.p.
4. Chan C., Franssen B., Dominguez I., Ramirez-Del Val A., Uscanga L.F., Campuzano M. Impact on quality of life after pancreatoduodenectomy: a prospective study comparing preoperative and postoperative scores // J. Gastrointest. Surg. - 2012. - Vol.16, N7. - P.1341-1346.
5. Khasanovna M. G. Features of Computer Dependence Comparative Characteristics of Computer-Dependent and Computer-Independent Adolescents by Anthropometric Indicators //International Journal of Innovative Analyses and Emerging Technology. - 2021. - T. 1. - №. 6. - C. 213-217.
6. Venkat R., Edil B.H., Schulick R.D., Lidor A.O., Makary M.A., Wolfgang C.L. Laparoscopic distal pancreatectomy is associated with significantly less overall morbidity compared to the open technique: a systematic review and meta-analysis // Ann. Surg. - 2012. - N255. - P.1048-1059.
7. Khasanovna M. G. Comparative characteristics of morphometric parameters of physical development and anthropometric data of the upper extremities of healthy and computer-dependent children //ResearchJet Journal of Analysis and Inventions. - 2021. - T. 2. - №. 09. - C. 14-17.

8. Мухидова, Гулмира Хасановна. "Comparative Characteristics of morphometric parameters of physical development and anthropo extremities of healthy and computer. Research." *Jet Journal of Analysis and Inventions-RJAI* 2.9 (2021): 14-17.
9. Мухидова Г. Х. Сравнительная характеристика компьютерно-зависимых компьютерно-независимых подростков по антропометрическим показателям //Тиббиётда янги кун. – 2021. – Т. 5. – С. 37.
10. Bahodirovna R. G., Shavkatovna G. S. Hemodynamic profile of patients with chronic obstructive pulmonary disease and obstructive sleep apnea syndrome //ACADEMICIA: An International Multidisciplinary Research Journal. – 2021. – Т. 11. – №. 12. – С. 587-591.