

How to Cite:

Goyal, T., & Gagandeep. (2021). Functional and esthetic rehabilitation of deciduous maxillary anteriors: A case report. *International Journal of Health Sciences*, 5(S2), 327–332. <https://doi.org/10.53730/ijhs.v6nS3.5849>

Functional and esthetic rehabilitation of deciduous maxillary anteriors: A case report

Tanya Goyal

MDS, Pedodontics, Associate professor, Desh Bhagat Dental College and Hospital, Amloh Road, Mandi Gobindgarh, Punjab, India

Gagandeep

MDS, Periodontology & Implantology, Associate professor, Desh Bhagat Dental College and Hospital, Amloh Road, Mandi Gobindgarh, Punjab, India

Abstract---Dental caries is the most common chronic childhood disease. Although the rate of dental caries has significantly decreased in recent years, it is still the most prevalent chronic disease of childhood. In Early Childhood Caries (ECC), there is early carious involvement of all maxillary and mandibular posterior teeth with gross destruction of maxillary anteriors. This case presents the clinical sequence of complete rehabilitation of decayed maxillary and mandibular primary teeth with placement of prefabricated metal post and strip crowns in maxillary central incisors.

Keywords---early childhood caries (ECC), maxillary central incisors, prefabricated metal posts, strip crowns.

Introduction

Early childhood caries is a rampant dental disease associated with unusual dietary practices that affects mostly young children and is characterized by an overwhelming infectious challenge. The American Academy of Pediatric Dentistry defines ECC “as the presence of 1 or more decayed, missing (due to caries), or filled tooth surfaces in any primary tooth in a child 71 months of age or younger”¹. Clinical examination of this condition discloses a distinctive pattern with involvement of all the teeth except mandibular anteriors.² The maxillary primary incisors are the most severely affected with deep carious lesions usually involving the pulp. In extreme cases, ECC can even lead to total loss of the crown structure.³

Earlier, the most pragmatic treatment was to remove the involved teeth. However, the loss of these teeth can lead to space loss, masticatory deficiency, phonetic

challenges, lack of pre-maxilla development and resulting malocclusion, development of para-functional habits (tongue-thrusting and mouth-breathing) and mainly psychological problems²⁻⁷. Because of the reduced coronal structure, direct restorative procedures do not always give satisfactory results.⁷ Various studies have shown that post and cores can overcome this problem by reestablishing the morphology of the crown and increasing the resistance to mechanical loads and masticatory forces³⁻⁹. Various posts can be used for intracanal retention in primary teeth including: resin composite posts, reinforced polyethylene fibers, orthodontic wires, prefabricated metal posts, nickel chromium cast posts with macroretentive features, and biologic posts^{5-7, 8-10}. Recently, a new technique has been introduced in which a prefabricated metal post is cemented upside down into the canal. This technique is a simple and effective treatment modality for such reconstructions⁵. This clinical case report presents a child with ECC and its complete oral rehabilitation, stressing on the treatment modality applied to restore the grossly decayed maxillary primary central incisors.

Case report

A 4 year old male patient reported to the Department of Pedodontics and Preventive Dentistry, with a chief complaint of decayed upper front teeth from past two years (Fig. 1a). There was no complaint of any pain or swelling in any region of mouth. Patient's medical history, family history, prenatal and natal history was non-contributory. Patient had never visited a dentist before. Patient's mother gave a history of breast feeding for 1 year after which the child was bottle fed for 2 years, with night bottle feeding habit. Diet history chart was obtained from patients guardian for 1 week and it revealed that patient consumes 3-4 sticky sugar candies per day and with brushing habit of once daily in morning. Extra oral examination revealed no abnormality. Intra-oral examination revealed a complete set of deciduous dentition with all the teeth (except mandibular anteriors) affected with dental caries. Radiographic examination by Orthopantomogram (OPG) and intra-oral periapical radiographs revealed pulp involvement wrt 51, 61,74,75,84 and 85 (Fig. 1b, 3a and 3c). On the basis of clinical history, clinical and radiographic investigations, the final diagnosis is Early childhood caries.

Treatment

After thorough diet analysis, the diet chart was prepared for the patient and complete oral prophylaxis was done, followed by diet counseling and oral hygiene instructions. Indirect pulp capping was done wrt 52 and 62, followed by coronal restoration with strip crowns (Fig. 1c). Pulpectomy was carried out for 51, 61 and orifices were sealed with fast setting zinc-phosphate cement (Fig. 2a). After 3 days, post space was prepared by removing approximately 4mm of obturating material (Metapex) with No. # 50 K-file. The post space was dried and 1mm base of glass ionomer cement was placed to isolate the obturated material from the rest of post space. Two metal posts of size- "short 1" (NORDIN, Swiss dental production) (Fig. 2b) were selected and trimmed from their ends to make them 6mm in length (3mm inside the canal and 3mm projecting outside the canal in coronal portion for core build up). The diameters of the posts were trimmed to make it fit in to the canal. An IOPA was taken to check the placement and

extension of metal posts (Fig. 2c). The prepared post space was then cleaned with normal saline and dried with paper points. The posts were cemented with the help of Glass ionomer cement (Type I) (Fig. 2d) and core build up was done (Fig. 2e). An appropriate sized strip crown (3M ESPE, MN USA) was selected. Coronal crown build up was done with light cure composite resin (Fig. 2f) using strip crowns and final finishing & polishing was done (Fig. 2g). 55, 54, 53, 63, 64 and 65 was restored with light cure composite resin. Pulpotomy was done wrt 74, 75 (Fig. 3b), 84 and 85 (Fig. 3d) and the patient is still on recall for Stainless steel crowns.

Discussion

Esthetic restoration of primary teeth has long been a challenge to pediatric dentists.³ When there is severe loss of coronal tooth structure, the use of posts will give retention and stability to the reconstructed crown.² The use of conventional prefabricated metal posts is a fast, low-cost and simple technique.⁵ Eshghi *et al*⁴ stated that the metal post technique is better than composite post and fiber post in terms of marginal adaptation, fracture resistance, stain resistant and retention. The use of prefabricated nonmetallic posts such as ceramic posts, carbon fibers, polyethylene fibers, glass fibers, etc has been an acceptable treatment option but due to excessive cost, technique sensitivity and multiple steps, this treatment becomes difficult.⁵

In this case report, a new technique for reconstruction of severely decayed primary anterior teeth has been presented. This direct restorative technique is easy to perform, without any laboratory procedures and can be completed in single appointment. The intracanal length of the post occupies only the cervical one-third of the canal to avoid interference with the process of primary tooth root resorption and permanent tooth eruption. In paediatric patients with multiple decayed primary anterior teeth, the presented technique is simple, economical and easy to perform and practical for all dentists. Hence long-term clinical studies are needed to investigate the advantages and disadvantages of this new technique, and evaluate the clinical successes and failures of the teeth restored with the above-mentioned method.

References

1. American Academy of Pediatric Dentistry: Policy on baby bottle tooth decay/ ECC revised 2008. (Reference Manual)
2. Schwartz SS, Rosivack RG, Michelotti P. A child's sleeping habit as a cause of nursing caries. J Dent Child. 1993; 60(1): 22-25.
3. Chunawalla YK, Zingade SS, Ahmed BJN, Thanawalla EA. Glass fibre reinforced composite resin post & core in decayed primary anterior teeth –A case report. Int J Clinic Dent Sci. 2011; 2(1): 55-59.
4. Eshghi A, Isfahan RK, Khoroushi M. Evaluation of three restorative techniques for primary anterior teeth with extensive carious lesions: A 1-year clinical study. J Dent Child. 2013; 80(2): 80-87.
5. Eshghi A, Isfahan RK, Khoroushi M. A simple method for reconstruction of severely damaged primary anterior teeth. Dent Res J. 2011; 8 (2): 221-25.
6. Saini S, Sharma D. Functional and esthetic rehabilitation during deciduous dentition stage: A case report. Dent Res J. 2011; 8(2): 108–11.

7. Jain M, Singla S, Bhushan BAK, Kumar S, Bhushan A. Esthetic rehabilitation of anterior primary teeth using polyethylene fiber with two different approaches. *J Indian Soc Pedod Prev Dent*. 2011; 29(4): 327-32.
8. Wanderley MT, Ferriera SLM, Rodrigues MD, Filho LER. Primary anterior tooth restoration using posts with macroretentive elements. *Quintessence Int*. 1999; 30(8): 432-36.
9. Mendes FM, Benedetto MS, Zardetto CG, Wanderley MT, Correa MSN. Resin composite restoration in primary anterior teeth using short-post technique and strip crowns: A case report. *Quintessence Int*. 2004; 35(5): 689-92.
10. Mandroli PS. Biologic restoration of primary anterior teeth: A case report. *Indian Soc Pedo Prev Dent*. 2003; 21(3): 95 – 97.

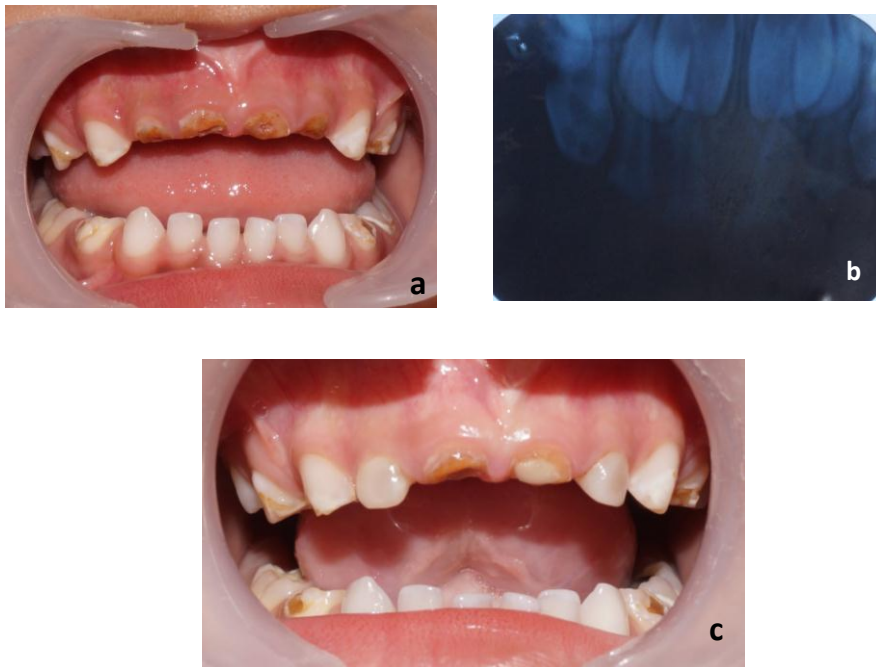

Fig 1: (a) Intraoral photograph wrt 52, 51, 61 and 62. (b) IOPA wrt 52, 51, 61 and 62 (c) Strip crowns wrt 52 and 62

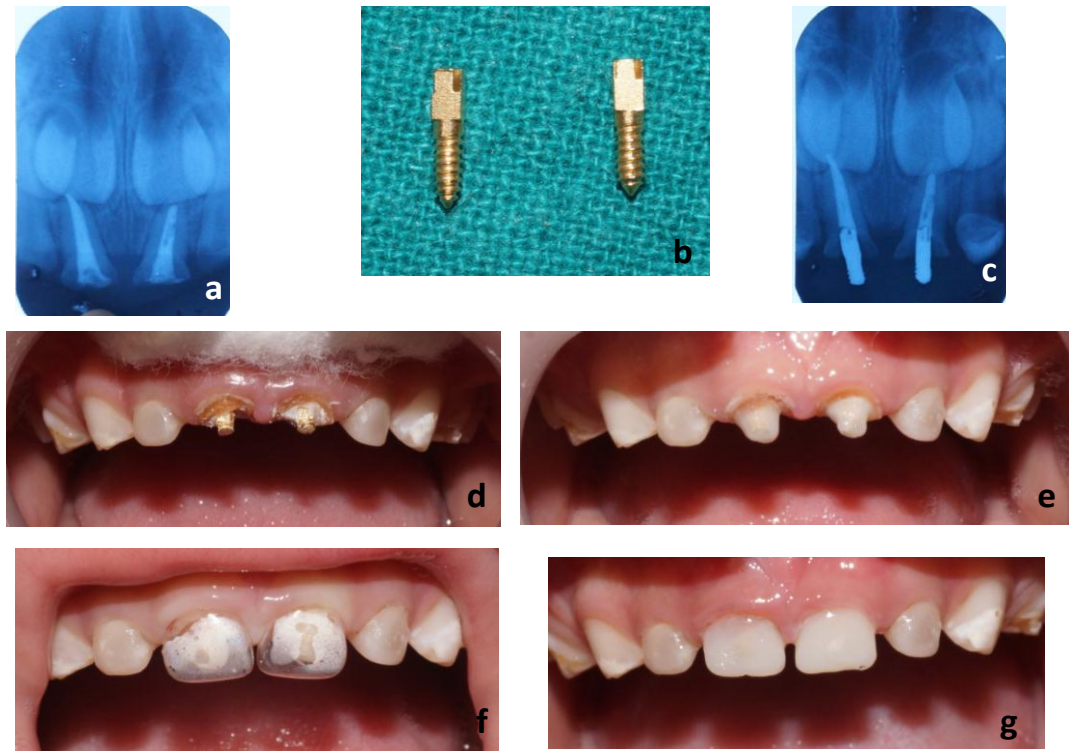


Fig 2: (a) Pulpotomy wrt 51 and 61 (b) Prefabricated metal posts (c) IOPA with metal posts wrt 51 and 61 (d) Metal posts cemented wrt 51 and 61 (e) Core build up with light cure composite resin wrt 51 and 61 (f) Strip crowns adjusted wrt 51 and 61 (g) Strip crowns wrt 51 and 61.

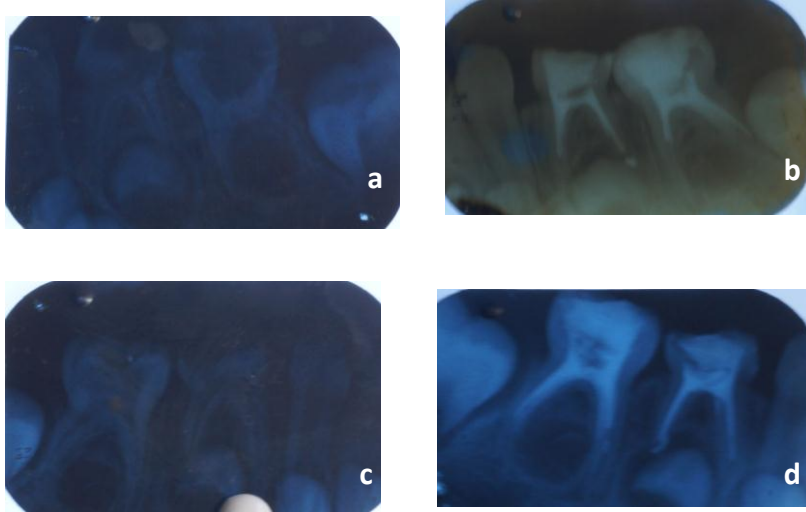


Fig 3: (a) Preoperative IOPA wrt 74 and 75 (b) Postoperative IOPA wrt 74 and 75.
(c) Preoperative IOPA wrt 84 and 85. (d) Postoperative IOPA wrt 84 and 85