

How to Cite:

Swarna, K. V., Chaudhary, D., Singh, H., Chacko, S. A., Ahamed, H. J., & Daniel, N. (2022). Management of acute alveolar abscess: A case report. *International Journal of Health Sciences*, 6(S1), 4610–4613. <https://doi.org/10.53730/ijhs.v6nS1.5872>

Management of acute alveolar abscess: A case report

K V Swarna

Final year PG Student, Department of Conservative Dentistry and Endodontics, Maharaja Ganga Singh Dental College and Research Centre, Sriganganagar, Rajasthan, India

Devendra Chaudhary

Principal and Head of Department, Department of Conservative Dentistry and Endodontics, Maharaja Ganga Singh Dental College and Research Centre, Sriganganagar, Rajasthan, India

Harmeet Singh

Reader, Department of Conservative Dentistry and Endodontics, Maharaja Ganga Singh Dental College and Research Centre, Sriganganagar, Rajasthan, India

Sreya Ann Chacko

Second year PG Student, Department of Conservative Dentistry and Endodontics, Maharaja Ganga Singh Dental College and Research Centre, Sriganganagar, Rajasthan, India

H. Javid Ahamed

Second year PG Student, Department of Conservative Dentistry and Endodontics, Maharaja Ganga Singh Dental College and Research Centre, Sriganganagar, Rajasthan, India

Nikhil Daniel

First year PG Student, Department of Conservative Dentistry and Endodontics, Maharaja Ganga Singh Dental College and Research Centre, Sriganganagar, Rajasthan, India

Abstract--The article is a case report on the management of acute periapical abscess associated with maxillary left first premolar by conventional root canal treatment and incision drainage. Radiographic examination on follow up showed healing of the endodontic lesion. Clinical evaluation also revealed no pain and sensitivity in relation to the upper left first premolar. Early diagnosis and proper management of the endodontic lesion led to successful resolution of this infection.

Keywords---infection, acute alveolar abscess, radiographic examination.

Introduction

An acute apical abscess is an infection of the tooth that manifests by rapid onset, spontaneous pain, tenderness to pressure, and pus formation followed by swelling of associated tissue¹. Acute alveolar abscess also known as acute dentoalveolar abscess or acute periapical abscess is caused by bacterial invasion of necrotic pulp tissue. Trauma, mechanical or chemical irritation are considered to be some of the causes for symptomatic (acute) alveolar abscess. A periapical abscess is a dental infection that occurs when bacteria invade the dental pulp, causing the pulp to die². This most commonly happens as a result of untreated tooth decay or trauma to the tooth. A periapical abscess can be found by performing an x-ray and will typically show up as an area of radiolucency on a radiograph. A clinician must have a knowledge about the management and regimens that is best given to treat the endodontic lesions^{3,4}. The purpose of this article was to describe the endodontic management of an Acute Periapical Abscess in a 22 year-old boy presenting with extra-oral swelling.

Case report

A 22 year old male patient attended to the department of conservative dentistry and endodontics at Maharaja Ganga Singh Dental College and Research Centre, Sriganganagar, Rajasthan, India, with the chief complaint of pain and swelling in the upper left back tooth region. He had no relevant past medical history. Extra-oral examination revealed facial swelling on the left side of cheeks. Intra-oral examination showed swelling in the alveolar mucosa adjacent to tooth #24 (Figure 1A). Clinically, tooth decay in the disto-occlusal surface of the tooth #24 was evident with tenderness on palpation in the adjacent alveolar mucosa. On percussion testing, the tooth #24 was tender and periodontal pocket was absent. A periapical radiograph revealed well-defined radiolucency surrounding root of upper left first premolar (Figure 1B). The treatment plan for the tooth #24 was decided as incision drainage of swelling in the alveolar mucosa followed by root canal therapy on tooth #24. The tooth was anesthetized with lidocaine. The suppurative yellowish fluid was drained by performing incision and drainage in the alveolar mucosa adjacent to the tooth #24. The intraoral swelling was compressed followed by copious irrigation with saline. Access cavity was prepared using round diamond bur and canal was negotiated using #10 K file. Working length was determined for both buccal and palatal canals. Biomechanical preparation was done using Neoendo Flex files followed by irrigation with sodium hypochlorite (3% NaOCl) and normal saline. The canals were enlarged to #25 and the root canals were filled with non settable calcium hydroxide as intracanal medicament. The access cavity was then sealed using temporary restoration, Cavit and patient was recalled after 10 days. Meanwhile, antibiotics and analgesics were prescribed for duration of 5 days. In the second appointment which was done after 1 week, the intra-oral swelling was completely healed and the temporary restoration was removed (Figure 1C). The root canals were irrigated by flushing normal saline and teeth were clinically asymptomatic. After proper

cleaning of the root canals, the canals were dried using absorbent points and obturation was done with 6% #25 Gutta-percha using single cone technique and AH plus sealer(Figure 1 D). Clinical and radiographic evaluation showed no pain or sensitivity to palpation and percussion with complete healing of the lesion in relation to tooth #24.

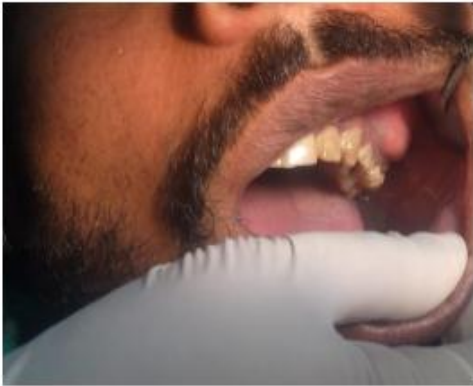

Figure 1A (Intraoral swelling)

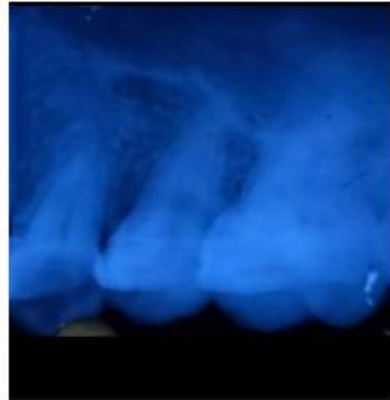

Figure 1B (Preoperative radiograph)

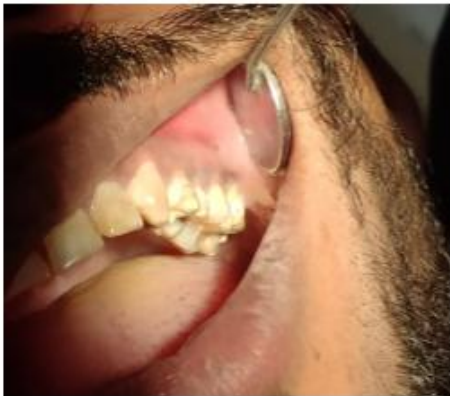

Figure 1C (After 1 week)

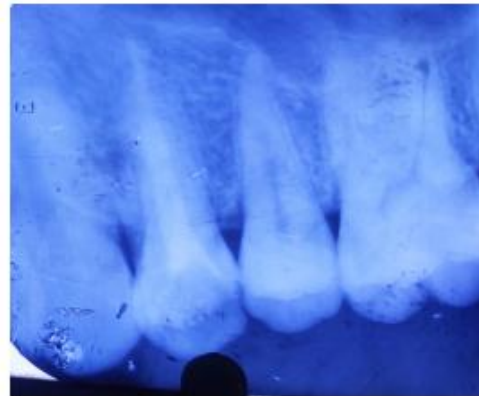


Figure 1D (Postoperative radiograph)

Discussion

In the present case, the main reason for the origin of pain and swelling in relation to 24 should be the tooth decay in relation to 24 which is pulpally involved. In this article, the clinical management of an acute apical abscess was performed by root canal treatment in addition with the systemic administration of amoxicillin and clavulanic acid (MOXCLAV 625mg) for 5 days to achieve an effective antibacterial effect. Here along with root canal treatment, pus drainage was done to relieve the pain by decreasing the apical infection. Non settable calcium hydroxide was placed within the root canals as intracanal medicament. Intracanal medicaments are indicated for antibacterial properties and help in reduction of inflammation⁵. According to Guttman, the success of endodontic treatment

depends on the debridement and neutralization of tissue, bacteria or inflammatory products that is present in the root canal. In the present study sodium hypochlorite was used as an intracanal irrigant to disinfect canals because it is effective against *E. faecalis* and has pulp dissolving ability^{2,6}.

Conclusion

The present case report demonstrates the efficacy of endodontic treatment in reducing periapical lesion and swelling. For any successful endodontic treatment, the clinician should have a proper knowledge and understanding of canal configurations and variations with radiographic evaluation.

References

1. John I. Ingle, Leif K. Bakland, J. Craig Baumgartner. Ingle's Endodontics, 6th edition, 2008 BC Decker Inc.
2. V. Gopikrishna. Grossman's Endodontic Practice, 14th edition. 2021;pp 75-77.
3. Robertson D, Smith AJ. The microbiology of the acute dental abscess. *J Med Microbiol.* 2009; 58:155-162.
4. Pedraza A.J, Cepeda N.A.M, Treviño F.J.J, Delgado R.I, Cepeda N.E.S and Meléndez G.R. *International Journal of Applied Dental Sciences* 2017; 3(4): 42-44.
5. Daramola OO, Flanagan CE, Maisel RH, Odland RM. Diagnosis and treatment of deep neck space abscesses. *Otolaryngol Head Neck Surg.* 2009; 141:123-130.
6. Kuriyama T, Williams DW, Yanagisawa M, Iwahara K, Shimizu C, Nakagawa K et al. Antimicrobial susceptibility of 800 anaerobic isolates from patients with dentoalveolar infection to 13 oral antibiotics. *Oral Microbiol Immunol.* 2007; 22:285-288.