

**How to Cite:**

Yadav, P., Sen, M., Srivastava, J. K., Das, A., & Chatterji, T. (2022). Fatal cryptococcal meningitis in a non-HIV patient: A case report. *International Journal of Health Sciences*, 6(S1), 5653–5664.  
<https://doi.org/10.53730/ijhs.v6nS1.6010>

## Fatal cryptococcal meningitis in a non-HIV patient: A case report

**Pushpa Yadav**

PhD. Scholar, Amity Institute of Biotechnology, Amity University Uttar Pradesh, Lucknow Campus, Malhour, Gomti Nagar Extension Lucknow-228028, India & Dept. of Microbiology, Dr Ram Manohar Lohia Institute of Medical Sciences, Lucknow-226010, India  
Email: [gudia65@gmail.com](mailto:gudia65@gmail.com)

**Manodeep Sen**

MD Professor, Dept. of Microbiology, Dr Ram Manohar Lohia Institute of Medical Sciences, Lucknow-226010, India  
Email: [sen\\_manodeep6@yahoo.com](mailto:sen_manodeep6@yahoo.com)

**Janamejai Kumar Srivastava**

PhD. Director, Biotechnology, Amity Institute of Biotechnology, Amity University Uttar Pradesh, Lucknow Campus, Malhour, Gomti Nagar Extension Lucknow-228028, India  
Email: [jksrivastava@lko.amity.edu](mailto:jksrivastava@lko.amity.edu)

**Anupam Das**

MD Professor, Dept. of Microbiology, Dr Ram Manohar Lohia Institute of Medical Sciences, Lucknow-226010, India  
Email: [dranupam06@yahoo.co.in](mailto:dranupam06@yahoo.co.in)

**Tanushri Chatterji**

PhD (Reader), Dept. of Microbiology, Babu Banarasi Das College of Dental Sciences, Babu Banarasi Das University, Lucknow-226028, India  
Email: [tanushri@gmail.com](mailto:tanushri@gmail.com)

**Abstract**---Cryptococcal infections (Cryptococcosis) are fatal fungal infections typically caused by *Cryptococcus neoformans*, a saprophyte frequently found in soil contaminated with pigeon droppings and frequently seen in immunocompromised (specifically HIV Positive) individuals. Now a day's awareness is emerging on cryptococcal disease among non-immunocompromised patients also. We present a case of *Cryptococcus meningitis* (CM) in a patient with cardiopulmonary arrest. A 55 year old male patient came with history of headache and fever with neck rigidity since last 3 months. The patient was admitted as a case of CM based on clinical findings and

radiological features. Investigations were done to rule out other disorders of the immune system. He was treated with Amphotericin B (IV) and Fluconazole orally for 2 weeks. Culture of CSF was done which showed presence of *Cryptococcus neoformans*. It is concluded from the findings that *Cryptococcus* may also affect non-HIV patients regardless to their immune system.

**Keywords**---cryptococcal infection, cardiopulmonary Arrest, *cryptococcus neoformans*, cryptococcal meningitis.

## Introduction

*Cryptococcus neoformans* is fourth commonly found fungal infection which affects the central nervous system with pulmonary manifestations of immunocompromised and AIDS patients. Immunocompromised patients are more prone to become infected due to hospitalization and death rate in renal transplant recipients is very high which approximately accounts of about 20.9%. [1,2,] while immune-competent patients are usually asymptomatic or report with pulmonary illness[3]. *Cryptococcus neoformans* and *Cryptococcal gatti* are the two types of encapsulated yeast which can cause life-threatening infection known as cryptococcosis in patients suffering from impaired cellular immunity.[4]. Globally, each year around 2,23, 000 cases of CM are reported among people with HIV/AIDS, with mortality of about 1,81, 000 [5]. Mortality and disability in CM has an important long-term impact on patients. To prevent death and other consequence of CM, proper and early diagnosis, combined antifungal therapy and Fluconazole treatment should be implemented, [6] though a very recent study [7] reported a case of CM with pulmonary cryptococcoma and that immune-competent patient has not responded well when on effective antifungal therapy alone.

For improving the quality of life in CM patients, impairment and access to rehabilitation is necessary. In developed countries cryptococcosis emerged to be rising in Non- HIV immunocompromised patients while on the other hand it is reported that due to improve access to entry vitro viral therapy it has been decreasing in HIV AIDS patients.[8]. Prevalence of HIV remains high in few nations and whenever the CD4 count drops below 100/mm<sup>3</sup> exploration of CM is predominant, though cryptococcosis does not necessarily made an impact in an apparently immunocompetent entity. Depending on the site of invasion of the pathogen, a dispersed cryptococcal infection can be apparent in diverse clinical form which includes meningoencephalitis, skin disease, pulmonary disease, peritonitis, osteomyelitis, and other comorbidities [9-14]. The significance of rapid and precise diagnosis of cryptococcosis is emphasized for better patient management

CASE REPORT

A 55 year old male patient with diabetes and chronic obstructive pulmonary disease came to the hospital. He complaint with severe headache with fever for last 3 months. His neck was rigid with 2-3 kg weight loss over a 3 to 6weeks period. He was under medication (steroid) for last five year due to medical issues but he was unable to explain the same. He also informed contact with a huge

population of pigeon at his work place. His neurological function was alert and normally oriented. The other parameters were also taken into consideration where his oral temperature was 37 degree centigrade, blood pressure 110 /70, heart rate 80, Oxygen saturation 96% with respiratory rate 20. Initially his lab report showed erythrocyte  $2.07 \times 10^6/\mu\text{l}$ , Leukocyte  $13.78 \times 10^3/\mu\text{l}$ , serum creatinine 1.09mg/dl Hemoglobin 6.5mg/dl, Serum urea 53mg/dl, Serum Potassium 2.05mmol/l and Random glucose 134mg/dl respectively. Liver and renal function was normal, hepatitis B and C Tumor Marker, HIV and syphilis was absent. There was a heterogeneous density of cerebellum present with multiple ring enhancing lesions of inferior cerebellum with four discrete lesions (Head computed tomography, MRI of brain.) (Figure 1). After admission, on day 1, patient complained severe headache with fever and evaluated clinically, patient's lumbar puncture was done and Cerebrospinal fluid (CSF) was obtained.

On day 2, patient was suffering from severe sepsis, decreased urination, and Low platelets count  $70,000/\text{mm}^3$  with breathing problems. Body temperature was 21 degree centigrade, Respiratory rate 16. Heart rate 60, High sensitive C - reactive protein 10 mg/ml, Procalcitonin (PCT) 5ng/ml and C - reactive protein was 110 mg/L respectively. The patient was under medication for sepsis with appropriate antibiotics included intravenously. Ceftriaxone 2 gm and Azithromycin 500 mg IV per day.

On day 3-day 6, patient CSF was analyzed for sugar and protein levels. The CSF sugar was 0.08mg/dl and protein were 243.8mg/dl respectively. CSF India ink preparation revealed 4-7 $\mu\text{m}$  rounded bud yeast with capsule (Figure 2) and 6-8 Lymphocytes per high power field. CSF samples were cultured on Sabouraud Dextrose Agar media [15], after 48 hrs incubation period of Creamy white, mucoid colonies were appeared. (Figure 3). Further the identification of *Cryptococcus neoformans* was done by the isolated culture and urease production. After identification treatment for infection was commenced with Liposomal Amphotericin B 350 mg intravenously daily and Flucytosine (100mg/kg/day, QDS). To determine the safety measures associated to undertake a lumbar puncture, Head CTs were done after every 2-3 days to assess brain edema and mass effect. Dexamethasone 4 mg at every 6 hrs also started intravenously.

Over the next few days (Day 7- Day 10) blood routine and biochemical analysis revealed no abnormality. Erythrocyte count  $2.07 \times 10^6/\mu\text{l}$  and  $13.78 \times 10^3/\mu\text{l}$  of leukocyte value respectively. There was 1% of monocyte,  $136 \times 10^3/\mu\text{l}$  platelet count, 6.5 gm/dl Hb, 1.09 mg/dl creatinine, 2.05mmol/L serum potassium and 53mg/dl serum urea respectively. Patient showed mild improvement.

On day 11-14 the patient reported more responsive and mild improvement in his mental status. The patient response to oral and sense stimulus and was able to reply to simple questions, though, he remained inactive and was feverish. During this time period his serum glucose level rises to 298mg/dl and continued to be uncontrolled and CSF sugar level was 5.0 mg/dl and protein level was 116 mg/dl.

On day 15- day 19 of admission, His repeat MRI head showed leptomeningeal enhancement. A repeat Lumbar Puncture was performed for CSF analysis it

reported with confirmed Cryptococcal Antigen Latex Test with a titer of 1:32 and a positive culture. Now the treatment for cryptococcosis was Fluconazole (1200 mg daily) + Flucytosine (100 mg/kg/day, QDS) and Amphotericin B (1.0 mg/kg/day) but his condition was worsening.

On day 20-day 25, High sensitivity test of C - reactive protein level was high; it indicates that acute inflammation of the arteries of the heart, which may increase the risk of heart attack. In an aging population, sepsis is more common due to weakened immune system. A repeat Lumbar puncture was endorsed to evaluate the CSF opening pressure, the patient became unconscious. On day 26-day 29, the patient was emergently intubated and kept on advanced cardiac life support. The outcome was fatal after 30<sup>th</sup> day of treatment and after few hours the patient expired due to sepsis, shock and cardiopulmonary arrest. (Table-1)

## Discussion

*C. neoformans*, inhaled from the environment is the main cause of meningoencephalitis which is the most often experienced indication of cryptococcosis with symptoms as fever, headache, malaise, seizures, vomiting and cranial nerve palsies [16,17]. In our study the patient was presented with headache, fever, neck rigidity and weight loss. *Cryptococcus* may spread to the numerous parts of human body including the lung, bone, CNS, prostate, skin, gastrointestinal tract and eyes [16, 18,19]. Due to non-pharmacological, immunosuppression and chemotherapy and antibacterial / antiviral therapies frequently, the incidence of meningitis increases in enlarging population of high risked immunosuppressed patients [20-22]. In addition, seemingly immuno- competent individuals can acquire this CNS infection with fungi such as *Cryptococcus neoformans* being the commonest infectious agent [23], Sub- Saharan Africa is encountering it with an increasing incidence of diabetes [24] coupled with the low levels of ample glucose control, Owuor and Chege [25] in their case study suggested that for diabetic patients presenting with chronic headache, fever and neurologic deficits, CM have to be considered in the differential diagnosis. Our patient was also suffering from diabetes along with chronic obstructive pulmonary disease.

According to Kiertiburanakul *et al.* [26] the percentage in non-HIV patient with cryptococcal infection including immunosuppressive drug treatment is 41%, Diabetes mellitus 14%, Lupus erythematosus 16% respectively. *Cryptococcus neoformans* can spread to brain and meninges by the circulatory system and in other organs like bone joint and skin it though the dispersion rate is less. It can also spread in non-HIV patients suffering from cushing's syndrome, haematological malignancies. (Leukemia or lymphomas), sarcoidosis, in organ transplantation etc.[27].

In our study the patient was in diabetic state with central nervous system cryptococcal infection during presentation associated with secondary bacterial sepsis, the repeat CSF CALAS and culture were performed at 2 Weeks and 4 weeks duration and were remained positive with no recovery of the patient. According to IDSA 2010 guideline combination of Amphotericin B (0.7-1mg/kg/day) for two weeks and Flucytosine was recommended. The

recommended dose is 100mg/kg/day for cryptococcal meningitis and the same combination for induction therapy is also suggested in non-HIV non transplant host with cerebral cryptococcosis patients for 4 to 6 weeks [23]. We have also followed the same medication and dosage pattern in our patient. Few evidence showed HIV patients cryptococcal infection are still less there are significant variations present in between HIV, non-HIV and non organ transplant patient during Prognosis.

Due to delayed diagnosis mortality rate of HIV patient is 26% and 24% in Organ transplant whereas in case of non-HIV non-organ transplant patient is 35% [20]. In predominantly diabetic, non-HIV, non-organ transplant patient the occurrence of cryptococcal meningitis is increased. The noticeable point is that reduced levels of adequate glucose control are detected in diabetic patients having any type of treatment [28, 29].

Some factors such as advanced age (over 60 yr) and chronic or organ failure are associated with increased mortality rate [30]. Sensitivity and specificity of India ink staining are 70.5% and 100% respectively [23]. A previous study reported CALAS (Serum Cryptococcal Latex Agglutination) titres are 87% sensitive for HIV negative patients and 95% sensitive for Cryptococcal meningitis patient [31]. Our study represented a non-HIV, immunocompromised patients with shock with cardiopulmonary arrest, with positive india ink and fungal culture respectively. Patient was treated with Fluconazole, Amphotericine B and Flucytosine. The high evidence of suspicion for probable Cryptococcus infection is obligatory not only in HIV positive but also in immunocompromised /immunocompotent patients. More research is required to address the potential risk factors and treatment modalities.

### **Conclusion**

Cryptococcal meningitis must be investigated in the discriminational diagnosis for all individuals, including Non-HIV patients, presenting with complaints of chronic headache and fever. A non-HIV patient requires a longer duration of combination therapy.

### **Acknowledgment**

We are thankful to all teaching and technical staff of Department of Microbiology, Dr. Ram Manohar Lohia Institute of Medical Sciences and Hospital, Lucknow for their help and valuable constant support.

### **Declaration of Patient consent:**

The authors certify that they have obtained consent from the patient. In the consent form the approval of the patient has been taken for his clinical information to be reported in the journal. The patient understood that his personal identity like name and initials will not be disclosed in this case report though the anonymity cannot be assured.

### Financial Support and Sponsorship:

The study is supported by Department of Science and Technology (WOS-A) scheme, New Delhi, India.

### Conflicts of Interest:

There are no conflicts of interest.

### References

- [1] Harmian D. Sittambalam, Md, Heidi Hanna, Md, Justin Martello, Md & Dimitra Mitsani, Md (2012) Cryptococcus infection in a non-HIV patient: a case report, *Journal of Community Hospital Internal Medicine Perspectives*, 2:3, 19254, DOI: 10.3402/jchimp.v2i3.19254.
- [2] (<http://www.usrds.org/default.aspx>)
- [3] Fisher JF, Valencia-Rey PA, Davis WB. Pulmonary cryptococcosis in the immunocompetent patient-many questions, some answers. *Open Forum Infect Dis* 2016; 3: ofw167.
- [4] G. D. Brown, D. W. Denning, N. A. R. Gow, S. M. Levitz, M. G. Netea and T. C. White, "Hidden killers: human fungal infections," *Science Translational Medicine*, vol. 4, no. 165, Article ID 165rv13, 2012.
- [5] Rajasingham R, Smith RM, Park BJ, Jarvis JN, Govender NP, Chiller TM, et al. Global burden of disease of HIV-associated cryptococcal meningitis: An updated analysis. *Lancet Infect Dis* 2017; 17: 873-881.
- [6] Estelle Pasquier, John Kunda, Pierre De Beaudrap, Angela Loyse, Elvis Temfack, Sile F. Molloy, Thomas S. Harrison and Olivier Lortholary. Long-term Mortality and Disability in Cryptococcal Meningitis: A Systematic Literature Review *Clinical Infectious Diseases®* 2018; 66(7): 1122–32.
- [7] Lee KT, Yong KY, Chua HH. Cryptococcal meningitis with pulmonary cryptococcoma in an immunocompetent patient: A case report. *Asian Pac J Trop Med* 2020; 13(1): 46-48.
- [8] V. Pyrgos, A. E. Seitz, C. A. Steiner, D. R. Prevots, and P. R. Williamson, "Epidemiology of Cryptococcal Meningitis in the US: 1997–2009," *PLoS ONE*, vol. 8, no. 2, Article ID e56269, 2013.
- [9] M. Musabende, C. Mukabatsinda, E. D. Riviello, and O. Ogbuagu, "Concurrent cryptococcal meningitis and disseminated tuberculosis occurring in an immunocompetent male," *BMJ Case Reports*, vol. 2016, 2016.
- [10] K. S. S. Han, A. Bekker, S. Greeff, and D. R. Perkins, "Cryptococcus meningitis and skin lesions in an HIV negative child," *Journal of Clinical Pathology*, vol. 61, no. 10, pp. 1138–1139, 2008.
- [11] Y. Ramkillawan, H. Dawood, and N. Ferreira, "Isolated cryptococcal osteomyelitis in an immune-competent host: a case report," *International Journal of Infectious Diseases*, vol. 17, no. 12, pp. e1229– e1231, 2013.
- [12] P. Singh, D. Joshi, and N. Gangane, "Cryptococcus peritonitis a rare manifestation in HIV positive host: a case report," *Diagnostic Cytopathology*, vol. 39, no. 5, pp. 365–367, 2011.
- [13] B. R. Yehia, M. Eberlein, S. D. Sisson, and D. N. Hager, "Disseminated cryptococcosis with meningitis, peritonitis, and cryptococemia in a HIV-

- negative patient with cirrhosis: a case report,” *Cases Journal*, vol. 2, no. 10, article no. 170, 2009.
- [14] V. L. S. Marques, R. C. Gomes, G. R. Viola *et al.*, “Pulmonary cryptococcosis in childhood systemic lupus erythematosus and Sjogren syndrome overlap: a rare opportunistic infection,” *Lupus*, vol. 22, no. 13, pp. 1409–1412, 2013.
- [15] Sen M, Chatterji T, Singh V, Yadav P, Das A and Mittal V, Cryptococcal meningitis in HIV (AIDS) patients, *Annals of Applied BioSciences*. 2017. 1344
- [16] Nandennavar M, Karpurmath S, Santosh KV, Rojaramani P, Ramakrishna NVS. Cryptococcal meningitis in a human immunodeficiency virus negative patient with follicular lymphoma. *Indian Journal of Medical and Paediatric Oncology : Official Journal of Indian Society of Medical & Paediatric Oncology*. 2014;35(1):118–9. <https://doi.org/10.4103/0971-5851.133739>
- [17] Guo L, Liu L, Liu Y, et al. Characteristics and outcomes of cryptococcal meningitis in HIV seronegative children in Beijing, China, 2002–2013. *BMC Infect Dis*. 2016;16:635. <https://doi.org/10.1186/s12879-016-1964-6>.
- [18] Sciaudone G, Pellino G, Guadagni I, Somma A, D’Armiento FP, Selvaggi F. Disseminated *Cryptococcus neoformans* infection and Crohn’s disease in an immunocompetent patient. *J Crohns Colitis* 2011; 5(1): 60-63
- [19] Kushawaha A, Mobarakai N, Parikh N, Beylinson A. *Cryptococcus neoformans* meningitis in a diabetic patient - the perils of an overzealous immune response: a case report. *Cases Journal*. 2009;2:209. <https://doi.org/10.1186/1757-1626-2-209>
- [20] Pappas PG. Therapy of cryptococcal meningitis in non-HIV-infected patients. *Curr Infect Dis Rep* 2001; 3: 365-70.
- [21] Byrnes EJ 3<sup>rd</sup>, Bartlett KH, Perfect JR, Heitman J. *Cryptococcus gattii*: An emerging fungal pathogen infecting humans and animals. *Microbes Infect* 2011; 13: 895-907.
- [22] Gottfredsson M, Perfect J R, *Fungal Meningitis 2000*, *Seminars in Neurology*; 20: 3
- [23] Perfect JR, Dismukes WE, Dromer F, Goldman DL, Graybill JR, Hamill RJ, Harrison TS, Larsen RA, Lortholary O, Nguyen MH, Pappas PG, Powderly WG, Singh N, Sobel JD and Sorrell TC, *Clinical Practice Guidelines for the Management of Cryptococcal Disease: 2010 Update by the Infectious Diseases Society of America Clinical Infectious Diseases* 2010; 50: 291-322.
- [24] Hall V, Thomsen RW, Henriksen O, Lohse N. Diabetes in sub Saharan Africa 1999-2011: epidemiology and public health implications. A systematic review. *BMC Public Health*. 2011; 11: 564. <https://doi.org/10.1186/1471-2458-11-564>.
- [25] Owuor OH , P Chege. Cryptococcal meningitis in a HIV negative newly diagnosed diabetic patient: a Case report. *BMC Infectious Diseases*. 2019; 19:5
- [26] Kiertiburanakul S, Wirojtananugoon S, Prachartam R, Sungkanuparph Cryptococcosis in human immunodeficiency virus-negative patients. *Int J Infect Dis* 2006; 10: 72-8.
- [27] S. A. Howell, K.C. Hazen, and M.E. Brandt, “Candida, Cryptococcus, and other yeasts of medical importance,” in *Manual of Clinical Microbiology*, J.H. Jorgensen and M.A. Pfaller, Eds., pp. 1984-2014, ASM Press,

- Washington DC, USA, 2015.
- [28] Majaliwa ES, *et al.* Survey on acute and chronic complications in children and adolescents with type 1 diabetes at Muhimbili National Hospital in Dar Es Salaam, Tanzania. *Diabetes Care.* 2007; 30(9): 2187–92. <https://doi.org/10.2337/dc07-0594>.
- [29] MOH. Cameroon Burden of Diabetes Project (Cambod): Baseline Survey Report. Ministry of Health, Cameroon; 2004.
- [30] Pappas PG, Perfect JR, Cloud GA, Larsen RA, Pankey GA, Lancaster DJ, Henderson H, *et al.* Cryptococcosis in human immunodeficiency virus-negative patients in the era of effective azole therapy. *Clin Infect Dis.* 2001; 33(5): 690-699.
- [31] Chau, T.T., N.H. Mai, N.H. Phu, H.D. Nghia and L.V. Choung *et al.*, 2010. A prospective descriptive study of cryptococcal meningitis in HIV uninfected patients in Vietnam- high prevalence of *Cryptococcus neoformans* var *grubii* in the absence of underlying disease. *Bmc. Infect. Dis.*, 10:199-199. DOI: 10.1186/1471-2334-10-199.

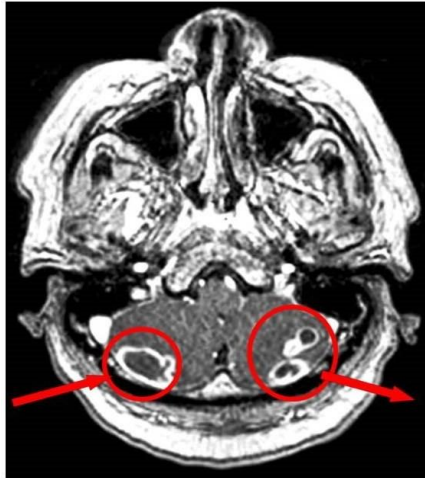**Figures**

Figure 1: Multiple ring-enhancing lesions of the inferior cerebellum with four discrete lesions

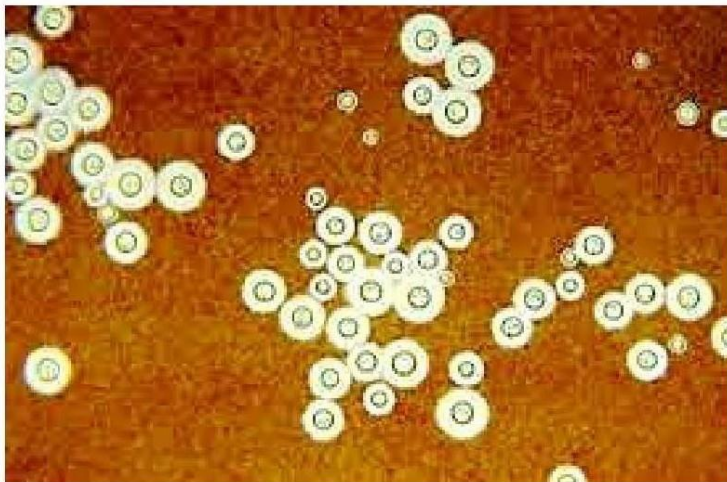


Figure 2: India ink preparation showing encapsulated budding yeast cells of *C. neoformans*

5662



Figure 3: Creamy color colonies of *C. neoformans* on Sabouraud's dextrose agar

### Supplementary File

Table: Treatment of cryptococcal infection in Non-HIV patient

Days	Complaints	Laboratory Investigations (If suggested any)	Findings	Treatment	Patient Condition (stable, Improved, Worsen)
Day 1	Severe Headache and Fever			Inj. Dexa4mg TDS Inj. Monocef 29m IV BD InjPan 40mg Inj Enptoin 100mg	
Day 2	Severe sepsis, Decreased urination, Breathing problem	Procalcitonin (PCT) C-Reactive protein		Ceftriaxan 2 gm, Azithromycin 500 mg IV per day	
Day 3- Day 6	Headache, Fever	CSF Sugar CSF Protein India Ink Fungal Culture  CT Scan	0.08mg/dl 243.8mg/dl 4-7 $\mu$ m rounded budding yeast cells with capsule. On Sabouraud dextrose Agar showed creamy, white, mucoid colonies.  Brain edema	Liposomal Amphotericine B 350 mg IV Flucytosine 100 mg/kg/day  IV Dexamethasol 4mg every 6 hrs	Mild Improvement
Day 7 to Day 10	Weakness and Lethargy	Erythrocyte count Leukocyte count Platelet count Hemoglobin Creatinine Serum Urea Serum Pottasium	2.07x10 <sup>6</sup> / $\mu$ l 13.78x10 <sup>3</sup> / $\mu$ l 136 x10 <sup>3</sup> / $\mu$ l 6.5 gm/dl 1.09mg/dl 53mg/dl 2.05mmol/L	Liposomal Amphotericine B 350 mg IV Flucytosine 100 mg/kg/day IV Dexamethasol 4mg every 6 hrs	Mild Improvement
Day	Fever ,	Serum Glucose	298 mg/dl	Liposomal	Mild

11 to Day 14	Inactive	CSF Sugar CSF Protein	5.0 mg/dl 116mg/dl	Amphotericine B 350 mg IV Flucytosine 100 mg/kg/day IV Dexamethasol 4mg every 6 hrs	Improvement
Day 15- Day 19	Headache	MRI CSF Analysis (CALAS CULTURE)	Leptomengal enhancement CALAS +ve (Titre 1:32) Positive	Fluconazole (1200 mg daily) + Flucytosine (100mg/kg/day)+ Amphotericine B (1.0 mg/kg/day)	Worsen
Day 20 day25	Heart attack			Azithromycin 500 mg IV Inj Enptoin 100mg Liposomal Amphotericine B 350 mg IV	Unconscious
Day 30	Cardio Pulmonary Arrest			Azithromycin 500 mg IV Inj Enptoin 100mg Liposomal Amphotericine B 350 mg IV	Expired