

How to Cite:

Zegyer, E. A. K., & Mutlag, A. M. (2022). Histological and chronological study of myostatin (MSTN) role on muscles growth in domestic broiler chicken. *International Journal of Health Sciences*, 6(S3), 2415–2432. <https://doi.org/10.53730/ijhs.v6nS3.6053>

Histological and chronological study of myostatin (MSTN) role on muscles growth in domestic broiler chicken

Esraa Abdul Khaliq Zegyer

Department of Pathological Analyses, College of Science, Wasit University, Wasit-Iraq

Ali Mahdi Mutlag

Department of Pathological Analyses, College of Science, Wasit University, Wasit-Iraq

Abstract--Chicken meat have a low-cholesterol levels, low-fat with a high unsaturation amount of fatty acids, which moreover be considered as functional foods, which provide bioactive ingredients with advantageous effects on human health like vitamins and antioxidants. Therefore, this project was designed to focusing on the relationship between increased the growth curve of skeletal muscles and the role of Myostatin (MSTN) in local domestic broiler chicken. The 50 birds of male domestic broiler chicken were collected from commercial field of Al -Kut, and according ages, the birds were divided into five groups (1day, 8 day, 15 day, 22day, and 30day). The samples of skeletal muscles were taken from the breast and leg areas. All samples were exposed to histological investigation by H&E stains, as well as immunohistochemical technique by a primary and secondary antibody of MSTN through paraffin-embedded sections. Histological results apparent a general structure of skeletal muscles at different ages through synchronous growth development of chicken. Immunohistochemical investigation appeared the different attribution of MSTN reactive in the skeletal muscle sections at sequence ages of chicken. Surface blots analysis of MSTN in skeletal muscle at the five experimental stages was (3.096, 10.049, 12.927, 18.453, 22.744) respectively. In conclusion, the skeletal muscle mass their structure connective tissue was developed with progress age. The skeletal muscle at first age has the weakly levels of MSTN accumulation within their fiber and this ratio gradually increase during aging.

Keywords---skeletal muscle, myostatin (MSTN), immunohistochemistry, broiler chicken.

Introduction

Over the older few years, meat production and marketplace have undergone numerous negative events that have weakened the image of this important food product from the customer's standpoint [1]. The meat products at most is relatively unfavorable due to their content in sodium, cholesterol, saturated fatty acids and fat that can be interested in most widespread diseases of Western societies similar cancer and diabetes mellitus and cardiovascular diseases [2]. Through previous years, worldwide poultry meat manufacture and consumption have increased quickly and, in several parts of the world, individual consumption of poultry meat will remain to grow [3]. Regarding nutritional characteristics, chick meat healthy fit the current consumer demand for a low-cholesterol levels meat, low-fat meat with a high unsaturation amount of fatty acids and low sodium levels. Poultry meat may moreover be considered as "functional foods", which deliver bioactive ingredients with advantageous effects on human health like vitamins, antioxidants, and conjugated linoleic acid [4].

Chicken growth is well defined as a sigmoid curve with a primary exponential development phase, a middle phase, and last phase of inhibited growth that comprises of a gradual reduction in the development rate following an asymptotic rise in the body weight [5]. The advantage of this growth model is that it depends on parameters of physiological prominence, leading to significant genotype comparisons. If genetic difference in pectoralis muscles yield of broiler chickens may be illuminated by differences in size and of amount the muscle cells (myofibers), one approach for completing higher breast muscle expansion could be to increase the amount of myofibers. Infact, slim weight of animals has been revealed to be related to the number of cells in their skeletal muscles, as described for double-muscled cattle, which have almost twice as many myofibers of mammals as different cattle [6] and for quicker growing like pigs [7,41,50].

As a outcome of selection for enlarged body weight and due to achievements in the field of rearing and feeding, the modern broilers farming are 3-4 times heavier (including thigh muscles and breast muscle) as compared with farming chickens of the laying category. Simultaneously, the time of poultry farming has been reduced to 35-42 days [8]. This growing require for chicken meat has resulted in force on breeders, nutritionists and chicken farmer to proliferation the growth rate of birds and size of breast. Earlier, chickens and turkeys and broiler chicken are marketed in around half the time and at nearly twice the body weight compared to ten years ago [9]. Skeletal muscle includes the largest percentage of animal mass. Understanding the mechanisms that control muscle growth has important agricultural implications. One of the objectives of the poultry manufacturing has been to select animals for improved growth rate and increased skeletal muscle mass until maintaining meat quality. For broiler chickens breeders this maximization rate of growth has focused on slim carcass development especially area for the breast muscles, the most valuable portion of the carcass [10].

Muscle cell proliferation, relocation, adhesion, and fusion are procedures involved with the formation of multinucleated muscle fibers (myotubes) that will more differentiate to the mature muscle fibers. This process of muscle fiber

growth is nearly complete at the period of hatch. Through post hatch, the skeletal muscle fiber growth occurs when muscle fiber enlargement by way of the hypertrophy, this process results from the staffing of satellite cell nuclei [11]. Hyperplasia and hypertrophy of muscle fibers are regulated by outward factors to the cell, which include the extracellular matrix and extrinsic elements include growth factors. The growth factors include hepatocyte growth factor, fibroblast growth factor2 (FGF2), insulin like growth factor, transforming growth factor- β and myostatin [12].

Myostatin (MSTN) is a protein manufactured and released by muscle cell that acts on a negative regulator of striated muscle growth [13]. Myostatin is a transforming growth factor-b (TGF-b) and growth/differentiation factor-8 (GDF-8), consider family member that is necessary for proper regulation of striated skeletal muscle mass [14]. Myostatin inhibits muscular growth through cellular differentiation of increasing somites during embryonic period and growth of myofibrillar cells through adult stages in animals [15, 16]. MSTN regulates muscle fibre growth [14], and muscle growth by regulating myosatellite cells activation and regeneration [17]. In broiler chicken (*Gallus gallus domesticus*), myostatin haplotypes were described to be related with body weight [18]. Between two breeds of chickens, Daweishan mini chickens (DMC) and Avian broiler (AB), the myostatin expression is associated to regulation of muscle development and body growth, using two various regulatory mechanisms that switch among 30 and 60 days of age. In Avian broiler, the higher myostatin expression detected in the leg muscle contrasted to breast muscle recommends that leg muscle growth rates are influence more by myostatin (MSTN) than skeletal muscle growth rates of breast area [13].

Aim of the study

This project aims to focusing on the role and relationship between myostatin and histological features of skeletal muscles development in broiler chicken through limitation breeding period.

Materials and Methods

Experimental design

The fifty birds of male domestic broiler chicken were collected from commercial field of Al -Kut, and according ages, the birds were divided into five groups (1day, 8 day, 15 day, 22day, and 30day) 10 birds for each group. All experimental birds were anesthetized and deadened with chloroform.

Samples collection

The skeletal muscle specimens from the breast and leg muscles were fixed in 10% neutral formalin, then muscle specimens were carry to fallow routine histological stapes: dehydration by progressively concentration of ethanol alcohol (70%, 80%, 90% and 100%), previously these specimens were cleared by xylene. The specimens were infiltrated and embedded in paraffin wax. The prepared

blocks were cut longitudinal and cross section by microtome in thickness (6 μ m), and then were stained with hematoxylin and eosin stain [19].

Immunohistochemistry technique

The immunohistochemistry process was implemented by using polyclonal antibody to myostatin (MSTN). This practice was used to detect the (MSTN) in the skeletal muscles sections. This technique was contained the reagents preparation which included the citrate buffer solution pH 6.0, Phosphate buffer saline (PBS) with pH 7.2, DAB reagent and Primary antibody (MSTN) was used at a dilution 1:500. Briefly, sections from embedded skeletal muscles were dewaxed, and antigen retrieval was done. Subsequently, sections were raised with protein blocking solution and then incubated with (MSTN) primary antibody. Followed by the slides were principal washed with PBS and later with distilled water through times. A few drops of DAB chromogenic reagent were added to the tissue sections and then slides were incubated with H&E. Then, slides were washed with distilled water and mounted with DPX mounting medium. Finally, the slides examined through light microscope by the use of different amplifications power (4X, 10X, 20X, 40X and 100X), and resulting sections were photographed using digital camera. The intensity of (MSTN) was measured using Image J program, as well as statistical analysis for data of histological sections intensity was performed by the t-test at a significance level of $p \leq 0.01$.

Results and Discussion

The histological study

The histological results of skeletal muscles were implemented by using hematoxylin and eosin stains for appearing the general structure in the skeletal muscles prepared from breast and leg areas at different ages through growth development of broiler chicken.

At 1 day age, the histological investigation of current work by (H&E) showed that the structure of skeletal muscles of broiler chicken essentially similar to mammalian skeletal muscle. Microscopically, the skeletal muscle was a relative homogeneity in the view, have several types of muscles fibers preserved by cells of connective tissue and nerves and blood supply (Figure1). Longitudinal section showed the single muscle fiber as long, cylindrical shape, non-branched, multinucleated, with a light and dark cross striation (Figure 2). On the other hand, cross section examinations of muscle fibers of breast and leg muscles showed the diameters of muscle fibers were small, and appeared single muscle fiber multifaceted or polygonal designed cell with lateral location myonuclei, bounded by thin layer of connective tissue called endomysium, in addition the perimysium was C.T layer that gathers skeletal muscle fibers in bundles or fascicles (Figure 3). These results compatible with that have been described in detail previously in broilers and Silkies chickens [20] and in broiler chicken and pigeons [21].

At 8 day age, histological analysis showed the overall structure of a single skeletal muscle of broiler chicken in this stage was developed. Within breast and

lags muscles, the endomysium and perimysium of muscular fascicles which were thicker than comparable to the previous age (1 day old) (Figure 4). The muscle fiber and connective tissue of broiler chicken have natural evolution, as well obtainable all circumstances fittings for poultry hatching and farming includes good nutrition and health condition which have sustainable role in normal evolve to all tissues. These observations were comparable to the previous description [20] who determined differences in the morphological and histological structure of skeletal fibers of leg and breast muscles of slow-growing hubbard chickens and silkies chickens. Whereas [22] showed that an improved temperature of hatching lead to an increased amount of fibers with a greater diameter in the skeletal muscles in breast area of broiler chickens.

At 15 day age, in both breast and legs area, the microscopically preview showed the growth rate observed for males in this age was approximation 20% higher than previous age (8 days). The cross section by (H&E) stains shown skeletal muscle fiber more regular and its diameter was thicker with relativity increase in this broiler age (Figure 5). This observation was like to the experiment conducted via Sobolewska *et al.* [23] who referred in broiler chickens, a more heavy increase of skeletal muscle fiber diameters was detected between 8 and 21 days of rearing. In addition, the character of skeletal muscle fibers is appointed genetically and is typical of especial hybrids and breeds [24].

At 22 day age, the cross sections treated with (H&E) showed the thicker and polygonal skeletal muscle fiber with clearly extracellular space between muscles fibers (Figure 6). The longitudinal section showed clear multinucleated, cylindrical shape with visible dark and light striations compare with that appeared at previous ages (Figure 7). In addition, the endomysium and perimysium were progressing comparison with this age (Figure 8). These result was similar with that some authors mentioned the development growth curve of skeletal muscle fibers, of commercial broiler chickens at 22 days [25] and breast and legs broiler chicken (Hubbard JA 957) at 21 days [20].

At, last stage of experiment (**30 day age**), the histological examinations of older birds sections were appeared the skeletal muscle reached to higher developed stage in their structure than younger birds. The longitudinal sections showed the skeletal muscle fibers tight interconnection with each another with few extracellular spaces between cylindrical muscle fibers, and compare with that observed at 22 day age (Figure 9). The present findings were completely identical to the results of [26], increased perimysium layer with aged can be illustrated by growing both quantity of intramuscular C.T and adipose tissue. On the other hand, the previous studies [27] demonstrated that this increasing may be related with rise differentiation of satellite cells (muscle stem cells) by its pass into alternative pathways to create the fibroblastic and adipogenic cells. Therefore, all elements of connective tissue which including the fibroblast, elastic fibers, collagen fibers, and ground substances will be increased gradually with progression age of broiler chicken.

In accordance with [28], the rapid-growing chickens are characterized via a larger thickness of muscle fibers compared to the birds with a slow- growth rate. The increased length and diameter of muscle fibers may be because of intensive

selection, and variations appearing in the size and form of muscle fibers [29]. There are several factors that contribute to variations in the character of muscle fibers, these including: age [30], sex [31], strain or breed [32], and physical activity [33].

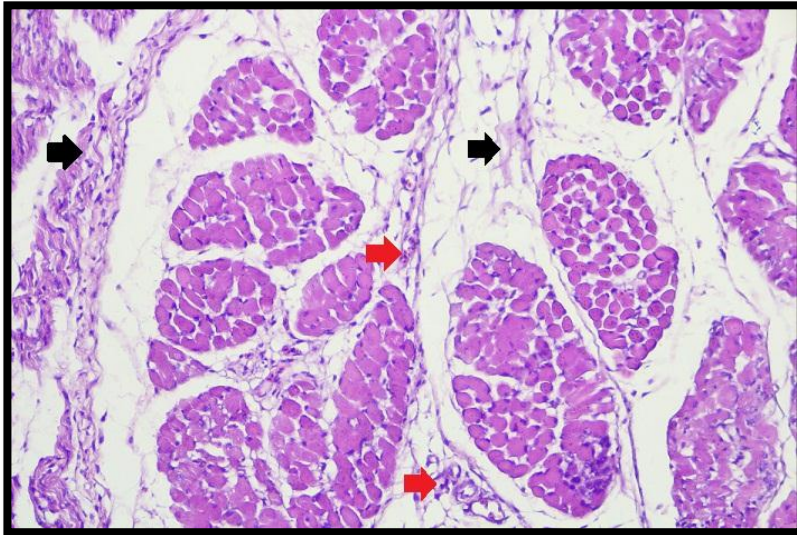


Figure 1. Photomicrograph showing a general histological structure of the skeletal muscles of breast area in broiler chicken (at 1 day age) preserved by cells of connective tissue (black arrows) and nerves and blood supply (red arrows) (H&E stain 200X)

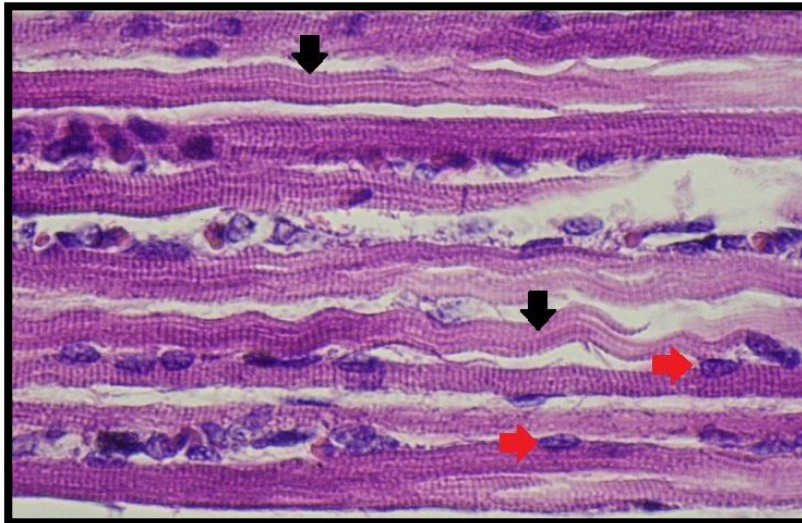


Figure 2. Photomicrograph showing Longitudinal section the skeletal muscles of leg area(at 1 day age) showed the single muscle fiber as long, cylindrical shape, non-branched, multinucleated(red arrows), with a light and dark cross striation(black arrows). (hematoxylin and eosin [H&E] stain -400 x)

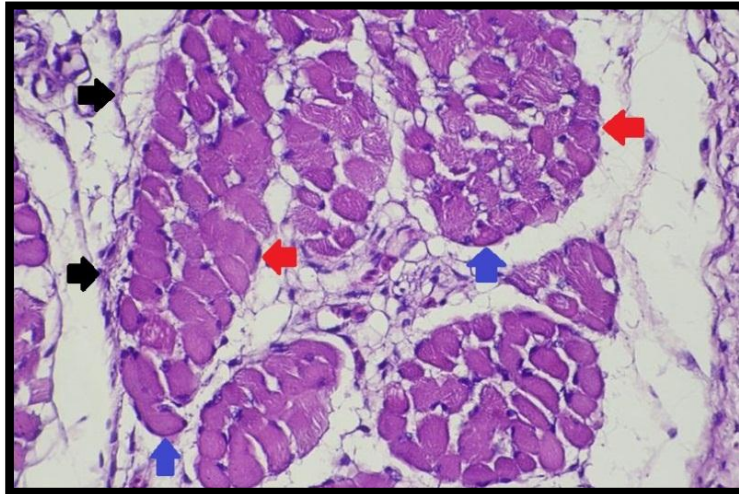


Figure 3. Photomicrograph showing cross section the skeletal muscles of breast area (at 1 day age) the appear single muscle fiber multifaceted or polygonal designed cell with lateral location myonuclei (red arrows), bounded by thin layer of C.T called endomysium (blue arrows), in addition the perimysium (black arrows) that gathers skeletal muscle fascicles (H&E stain 400X)

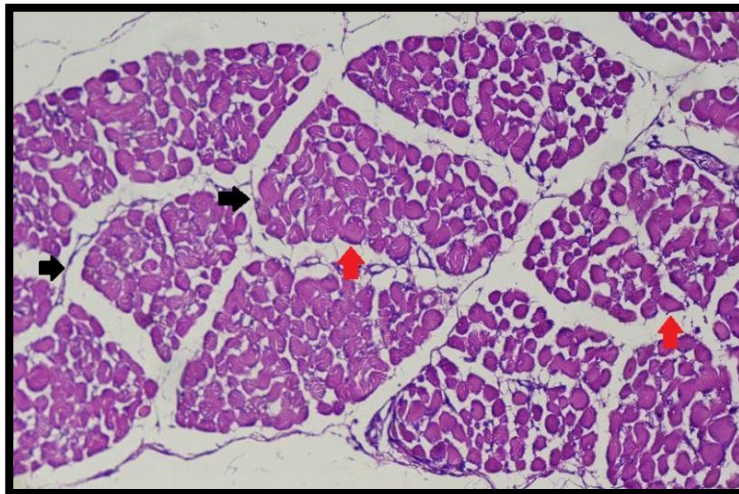


Figure 4. Photomicrograph showing the cross section of skeletal muscles of breast area of male broiler (at 8 day age), the connective tissue envelope including the endomysium (red arrows) around the muscle fibers and premysium (black arrows) of muscular fascicles (H&E stain 200 X)

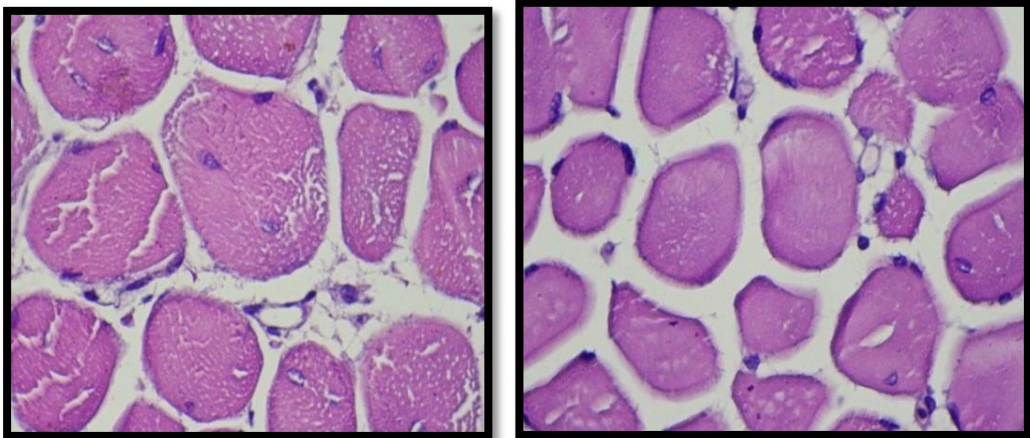


Figure 5. Photomicrograph showing the cross section of skeletal muscle fiber of (A) breast and (B) leg areas (at 15 day age) more regular and its diameter was thicker with relatively increase in broiler age (H&E stain -1000X)

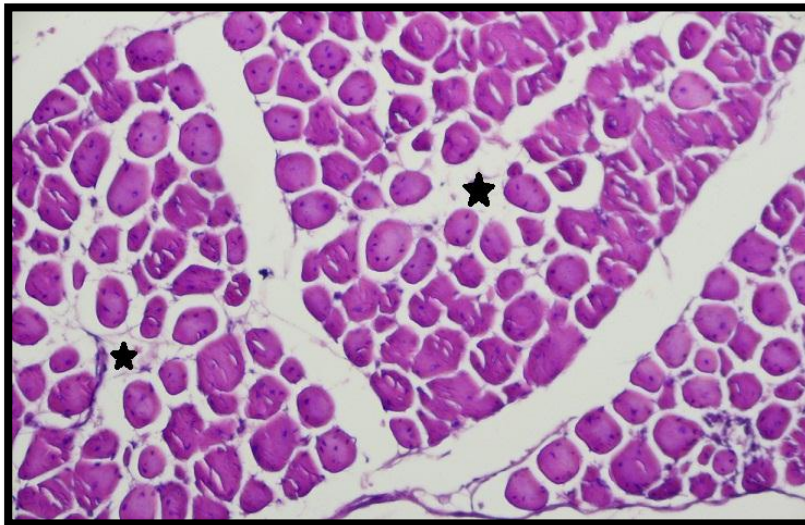

Figure 6. Photomicrograph showing the cross section of skeletal muscle fiber of breast area at 22 day age the thicker and polygonal skeletal muscle fiber with clearly extracellular space (star) between fibers (H&E stain-200X).

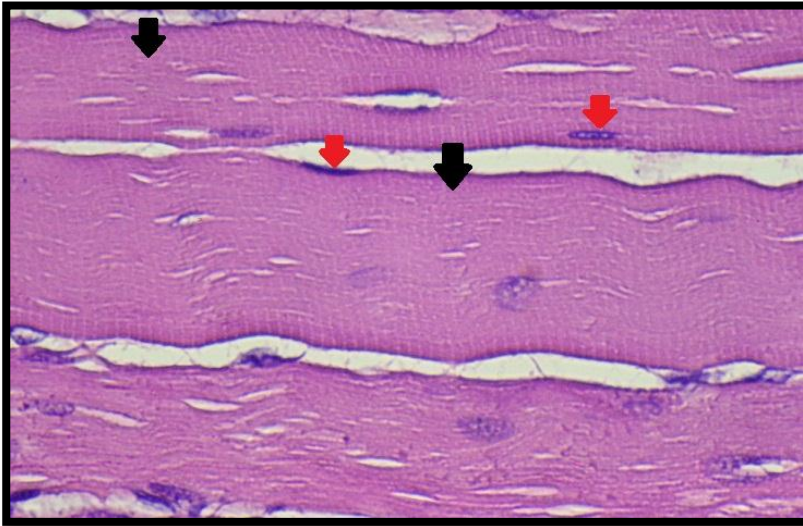


Figure 7. Photomicrograph showing the longitudinal section of muscle fiber of leg area at 22 day age, clear multinucleated (red arrows), and cylindrical shape with dark and light striations (black arrows) (H&E stain -1000X)

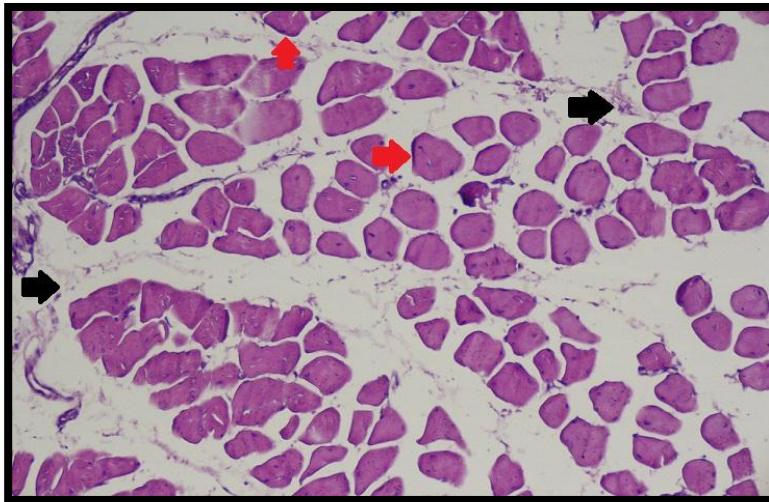


Figure 8. Photomicrograph showing the cross section of skeletal muscle of leg area at 22 day age, the endomysium (red arrows) and perimysium (black arrows) are progressing (H&E stain -200X)

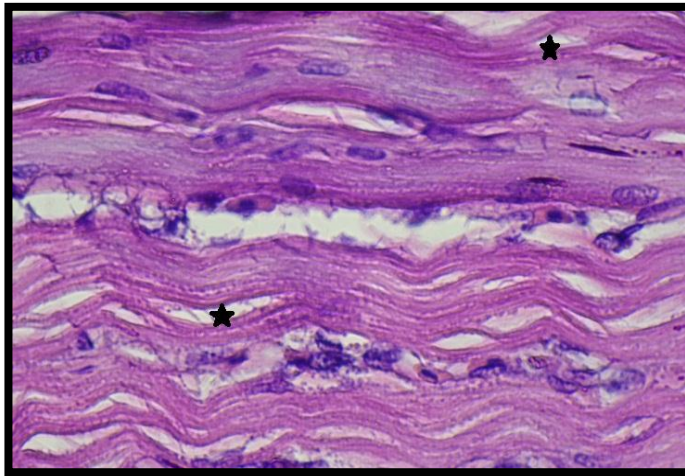


Figure 9. Photomicrograph showing the longitudinal sections of skeletal muscle fibers of leg area at 30 day age, tight interconnection with each another with few extracellular spaces between muscle fibers (H&E stain 1000X)

The immunohistochemical study

The result of immunohistochemical technique by using polyclonal primary antibody for the myostatin (MSTN) shown weekly immunoreactivity scattered within differentiated skeletal muscle fibers of both breast and leg area of broiler chicken **at 1 day age old** (Figure 10A). The occurrence of MSTN immunoreactivity the 1st day was estimated as (3.096) of (Figure 10 B). **At 8 and 15 day age**, immunohistochemical practice showed remarkable increase in myostatin immunoreactivity (Figures 11A, 12 A), and this reactive was more distinctness in the skeletal muscle fibers of breast muscles. The occurrences of MSTN immunoreactivity at these stages were estimated respectively (10.049, 12.927) of (Figures 11B, 12 B) (Chart 1).

With progress age, **at 22 and 30 day** old of broiler chicken, the immunohistochemical technique with primary antibody (MSTN) was shown widespread immunoreactivity scattered within thought the plasma membrane and sarcoplasmic of skeletal muscle fibers in breast and leg areas of broiler chicken (Figures 13A, 14 A). The amount of (MSTN) in these skeletal muscles was progressively increasing compare with previous ages, and the attribution of (MSTN) in skeletal muscle tissues at 22 and 30 ages old was enumerated as (18.453, 22.744) of (Figures 13B, 14 B) respectively (Chart 1).

The results revealed that *MSTN* factor was decreased at 1day, afterwards the level of this factor was significantly increased gradually at 7 day until 30 day age. Our data demonstrate that growing of myostatin-immunoreactive protein concentrations in the skeletal muscle cross-sections were accompaniment to increase in the body growth, weight gain, and proliferation thickness of muscle fibers. Technically, this investigation was comparable to study of [34] who mentioned to expression of *MSTN* in muscular and glandular stomach, liver, lung, kidney, pectoralis muscle, heart, spleen through different old stages of domestic

pigeon. In pectoralis muscle fiber, his results revealed that *MSTN* expression was significantly decreased from 1 day through 7 postnatal days. After that, there was successive increase abundance up to 28 day. As a negative controller of skeletal muscle mass, the myostatin was firstly thought to be limitedly expressed in the muscle [35]. Subsequently, many studies had shown that the myostatin expression pattern was species-specific. Some authors reported that myostatin could be identified in most tissues of fish [36], in the skeletal muscle, spleen, and heart of Indian goat breeds [37].

The results of present work showed a unique tissue appearance pattern of broiler chicken that there was a prominent distribution of myostatin in breast and legs muscle. Furthermore the *MSTN* proportion in breast muscle was higher than that in other legs muscle. These findings were consistent with the recently previous studies [34] showed that the myostatin expression had the more abundance in breast muscle of pigeon. During the initial stage post-hatching, the expression of myostatin in breast muscle increased through age and had a significant positive correlation with skeletal muscle fiber cross-sectional region. There was an inter-relationship among myostatin and the myogenic regulatory factors (myogenin, MyoD, MRF and Myf5) in the regulation of differentiation and proliferation of myogenic precursor cells [38]. The top level of *MyoG* expression at 7 day post-hatching suggested that the cells were getting the appropriate signals to differentiate into mature skeletal muscle [39]. In addition, myostatin expression level stayed at a relatively low status through the first week post-hatching of birds. As in the determination of Deveaux *et al.*, [40], the decrease of myostatin transcripts might occur sequentially to the myogenic regulatory factors (like Myf5 down-regulation and /or *MyoG* up-regulation) during terminal differentiation. It appeared that myostatin have a critical role in myogenic differentiation via inhibiting the levels of myogenic regulatory factors.

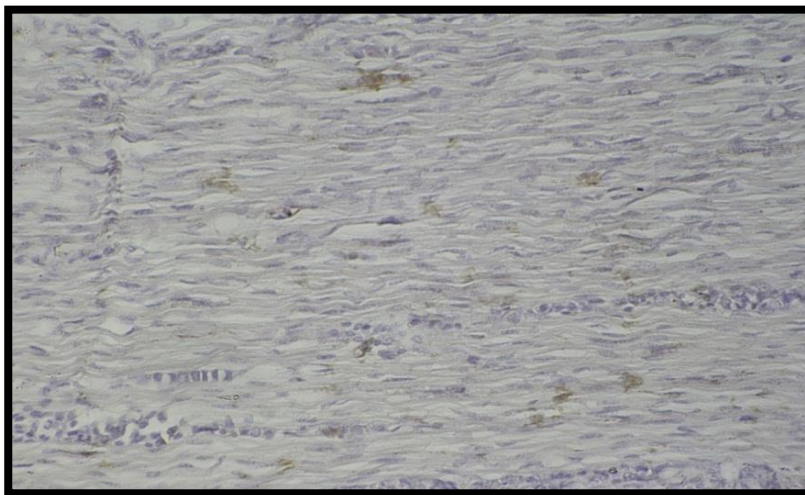


Figure 10. Photomicrograph of skeletal muscle fibers of breast area showing MSTN immunoreactivity scattered skeletal muscle fibers at 1 day of age (Immunohistochemical Technique 200X)

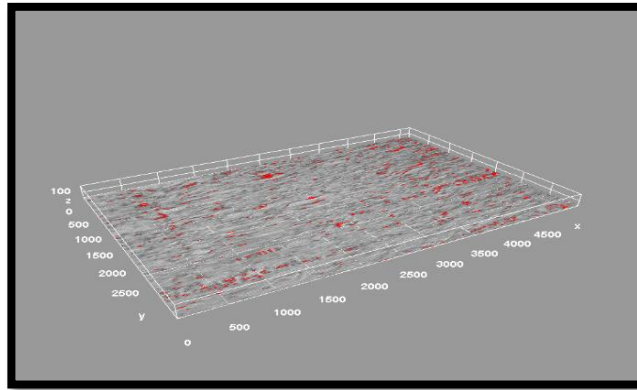


Figure 10. B: Surface plot of skeletal muscle fibers of breast area showing the percentage of MSTN in skeletal muscle fibers at 1 day of age

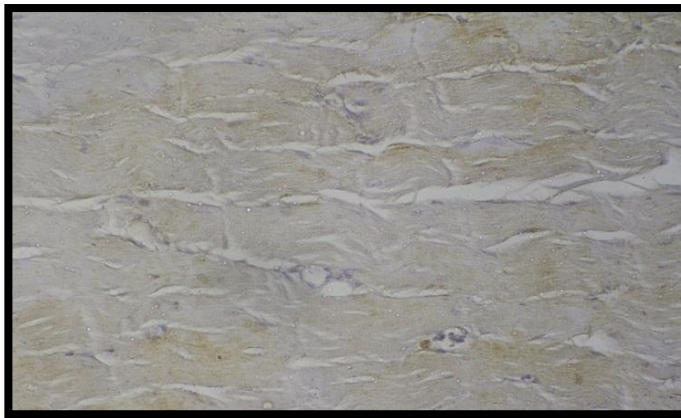


Figure 11. A: Photomicrograph of skeletal muscle fibers of breast area showing remarkable increase in myostatin immunoreactivity at 8 days of age (Immunohistochemical Technique 200X)

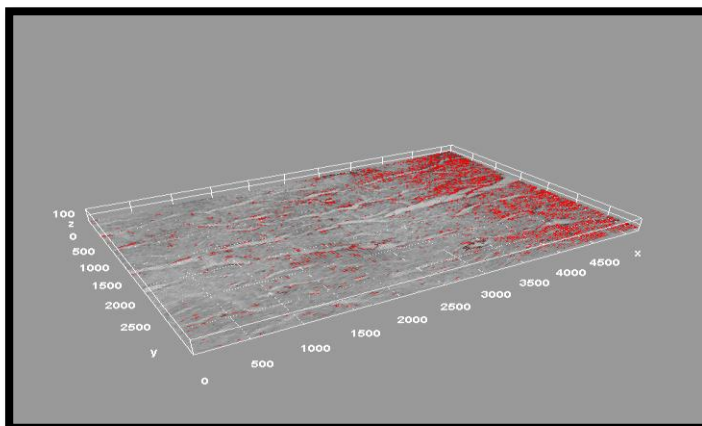


Figure 11. B: Surface plot of skeletal muscle fibers of breast area showing the percentage of MSTN in skeletal muscle fibers at 8 day of age

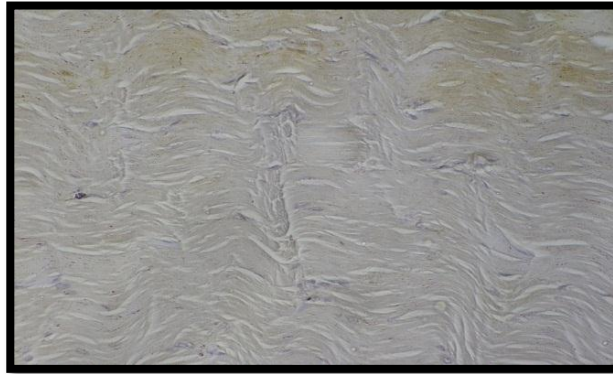


Figure 12. A: Photomicrograph of skeletal muscle fibers of breast area showing remarkable increase in myostatin immunoreactivity at 15 days of age (Immunohistochemical Technique 200X)

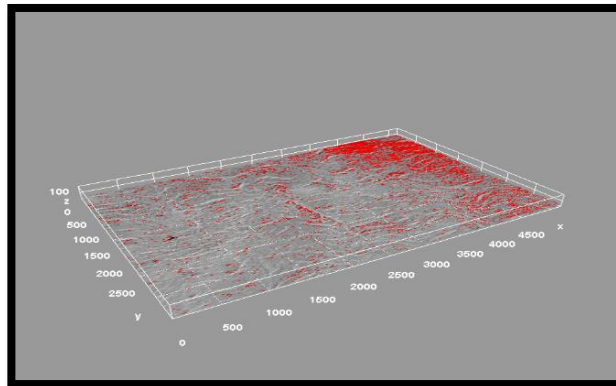


Figure 12. B: Surface plot of skeletal muscle fibers of breast area showing the percentage of MSTN in skeletal muscle fibers at 15 day of age

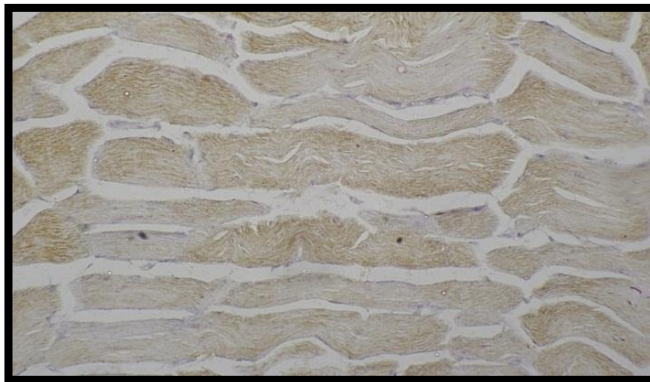

Figure 13. A: Photomicrograph of skeletal muscle fibers of breast area showing widespread MSTN immunoreactivity scattered of skeletal muscle fibers at 22 days of age (Immunohistochemical Technique 200X)

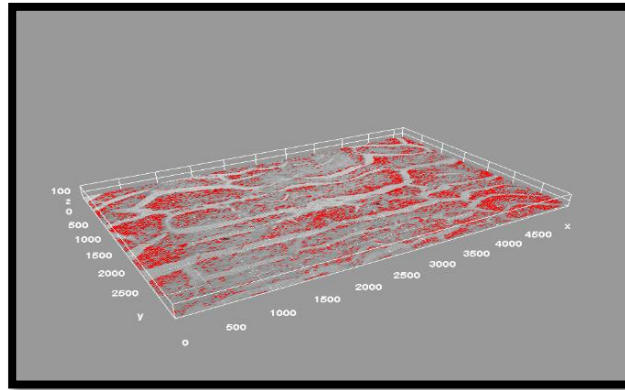


Figure 13. B: Surface plot of skeletal muscle fibers of breast area showing the percentage of MSTN in skeletal muscle fibers at 22 day of age



Figure 14. A: Photomicrograph of skeletal muscle fibers of breast area showing widespread MSTN immunoreactivity scattered of skeletal muscle fibers at 30 days of age (Immunohistochemical Technique 200X)

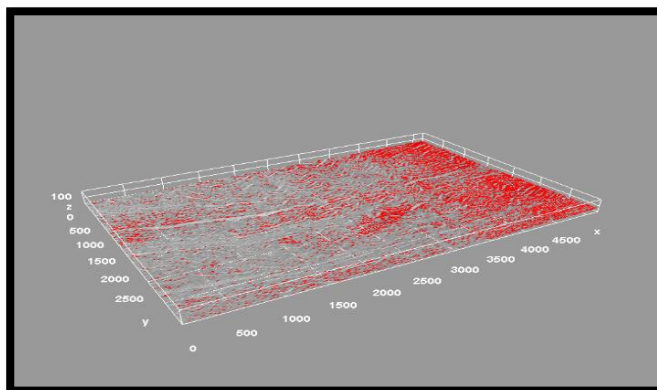


Figure 14. B: Surface plot of skeletal muscle fibers of breast area showing the percentage of MSTN in skeletal muscle fibers at 30 day of age

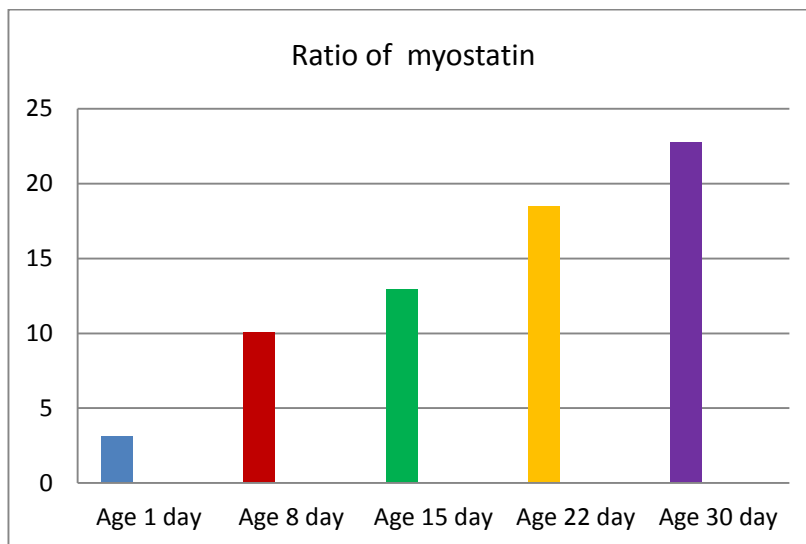


Chart 1. The ratio of myostatin occurrence at different ages of broiler chicken (1day, 8day, 15 day, 22 day, and 30 day)

Conclusions

The general construction skeletal muscle progressively develops with sequences period of poultry farming. Whoever the skeletal muscle fibers diameter and its connective tissue and adipose tissue increased with chicken's age, which leads to proliferation muscle mass. The muscles of young chickens recorded lowermost rate of myostatin which synchronization with primary skeletal muscle growth. The rate this factor increasing with ageing and developed skeletal muscles mass, wherefore the ratio of myostatin has direct proportion with the skeletal muscle fiber enlargement or hypertrophy.

References

1. Toldrá, F.; Reig, M. (2011). Innovations for healthier processed meats. *Trends Food Sci. Technol.*, 22, 517–522.
2. Micha, R.; Wallace, S.K.; Mozaffarian, D. (2010). Red and processed meat consumption and risk of incident coronary heart disease, stroke and diabetes mellitus. A systematic review and meta-analysis. *Circulation*, 121, 2271–2283.
3. Cavani, C.; Petracci, M.; Trocino, A.; Xiccato, G. (2009). Advances in research on poultry and rabbit meat quality. *Ital. J. Anim. Sci.*, 8, 741–750.
4. Givens, D.I. (2009). Animal nutrition and lipids in animal products and their contribution to human intake and health. *Nutrients*, 1, 71–82.
5. Aguilar, C., Friedli, C., & Canas, R. (1983). The growth curve of animals. *Agricultural Systems*, 10(3), 133-147.
6. Swatland, H. J., and N. M. Kiefer. (1974). Fetal development of the doubled muscled condition in Cattle. *J. Anim. Sci.* 38:752–757.
7. Dwyer, C. M., J. M. Fletcher, and N. C. Stickland. (1993). Muscle cellularity and postnatal growth in the pig. *J. Anim. Sci.* 71:3339–3343.

8. Klont R. E., Eikelenboom, Brocks I. (1998). Muscle fibre type and meat quality. *Proc.*, 44th ICoMST: 98-105.
9. Barbut, S., Sosnicki, A. A., Lonergan, S. M., Knapp, T., Ciobanu, D. C., Gatliffe, L. J., & Wilson, E. W. (2008). Progress in reducing the pale, soft and exudative (PSE) problem in pork and poultry meat. *Meat science*, 79(1), 46-63.
10. Swartz, D. R., S.-S. Lim, and T. Faseel, and M. L. Greaser. (1994). Mechanisms of myofibril assembly. *Reciprocal Meat Conf. Proc.* 47:141-153.
11. Velleman, S. G. (2007). Muscle development in the embryo and hatchling. *Poultry science*, 86(5), 1050-1054.
12. Allen, R. E., and D. E. Goll. (2003). Cellular and developmental biology of skeletal muscle as related to muscle growth. Pages 148-169 in *Biology of Growth of Domestic Animals*. Colin Scanes, ed. Iowa State Press, Ames).
13. Dou, T., Li, Z., Wang, K., Liu, L., Rong, H., Xu, Z., & Jia, J. (2018). Regulation of myostatin expression is associated with growth and muscle development in commercial broiler and DMC muscle. *Molecular biology reports*, 45(4), 511-522.
14. McPherron, A. C., A. M. Lawler, and S. J. Lee. (1997). Regulation of skeletal muscle mass in mice by a new TGF- β superfamily member. *Nature*. 387:83-90.
15. Lee, S. J. & McPherron, A. C. (2001). Regulation of myostatin activity and muscle growth. *Proc Natl Acad Sci (USA)* 98, 9306-9311.
16. Hickford, J. G. H., Forrest, R. H., Zhou, H., Fang, Q., Han, J., Frampton, C. M., & Horrell, A. L. (2010). Polymorphisms in the ovine myostatin gene (MSTN) and their association with growth and carcass traits in New Zealand Romney sheep. *Animal genetics*, 41(1), 64-72.
17. McCroskery S, Thomas M, Maxwell L, Sharma M, Kambadur M (2003). Myostatin negatively regulates satellite cell activation and self-renewal. *J Cell Biol.*162:1135-1147.
18. Bhattacharya, T. K., & Chatterjee, R. N. (2013). Polymorphism of the myostatin gene and its association with growth traits in chicken. *Poultry science*, 92(4), 910-915.
19. Suvarna, K. S., Layton, C., & Bancroft, J. D. (2018). Bancroft's theory and practice of histological techniques E-Book. Elsevier Health Sciences.
20. Lukasiewicz, M., Mroczek-Sosnowska, N. A. T. A. L. I. A., Wnuk, A. G. N. I. E. S. Z. K. A., Kamaszewski, M., Adamek, D. O. B. R. O. C. H. N. A., Tarasewicz, L., ... & Niemiec, J. (2013). Histological profile of breast and leg muscles of Silkies chickens and of slow-growing Hubbard JA 957 broiler. *Annals of Warsaw University of Life Sciences-SGGW. Animal Science*, 52.
21. Umar, A.A; Jibril, M., Atabo SM.; Danmaigoro, A. and Ekeolu, OK. (2020). Gross and Histological Studies of Muscles of Flight in Some Avian Species. *Arch. Anim. Poult. Sci.* Volume 1(4) , 52- 57.
22. Dankowiakowska A., Sobolewska A., Bogucka J., Walasik K., Elminowska-Wenda G. Kozłowska I., Bednarczyk M., (2012). Zróżnicowanie grubości włókien mięśniowych kurcząt 1-dniowych stymulowanych Temperature podczas inkubacji. *Proc. XXIV Międzynarodowe Sympozjum Drobiarskie PO WPSA*, 22-24.
23. Sobolewska, A., Elminowska-Wenda, G., Walasik, K., Bogucka, J., Sławińska, A., Szczerba, A., & Żmuda-Trzebiatowska, M. (2011). Increase in thickness of the pectoral muscle fibers in meat-type chicken between 1st and 35th day of

- fattening. In XXIII International Poultry Symposium PB WPSA. Poznań (pp. 13-15).
24. Bereta, A., & Eckert, R. (2010). Profil histologiczny mięśni ma ścisły związek z jakością mięsa wieprzowego. *Wiadomości Zootechniczne*, 4(48).
 25. Scheuermann, G. N., Bilgili, S. F., Hess, J. B., & Mulvaney, D. R. (2003). Breast muscle development in commercial broiler chickens. *Poultry Science*, 82(10), 1648-1658.
 26. Csapo, R., Malis, V., Sinha, U., Du, J., & Sinha, S. (2014). Age-associated differences in triceps surae muscle composition and strength—an MRI-based cross-sectional comparison of contractile, adipose and connective tissue. *BMC musculoskeletal disorders*, 15(1), 1-11.
 27. García-Prat, L., Sousa-Victor, P., & Muñoz-Cánoves, P. (2013). Functional dysregulation of stem cells during aging: a focus on skeletal muscle stem cells. *The FEBS journal*, 280(17), 4051-4062.
 28. Dransfield E, Sosnicki AA. (1999). Relationship between muscle growth and poultry meat quality. *Poult Sci* 78:743-746.
 29. Bogucka, J., & Kapelanski, W. (2004). Histopathological changes in longissimus lumborum muscle of Polish Landrace and crossbred Stamboek and Torhyb pigs. *Animal Science Papers and Reports. Supplement*, 22(3).
 30. Čandek-Potokar, M., Žlender, B., Lefaucheur, L., & Bonneau, M. (1998). Effects of age and/or weight at slaughter on longissimus dorsi muscle: Biochemical traits and sensory quality in pigs. *Meat science*, 48(3-4), 287-300.
 31. Ozawa, S., Mitsuhashi, T., Mitsumoto, M., Matsumoto, S., Itoh, N., Itagaki, K., ... & Dohgo, T. (2000). The characteristics of muscle fiber types of longissimus thoracis muscle and their influences on the quantity and quality of meat from Japanese Black steers. *Meat Science*, 54(1), 65-70.
 32. Ryu, Y. C., Choi, Y. M., Lee, S. H., Shin, H. G., Choe, J. H., Kim, J. M., ... & Kim, B. C. (2008). Comparing the histochemical characteristics and meat quality traits of different pig breeds. *Meat science*, 80(2), 363-369.
 33. Jurie, C., Picard, B., & Geay, Y. (1999). Changes in the metabolic and contractile characteristics of muscle in male cattle between 10 and 16 months of age. *The Histochemical Journal*, 31(2), 117-122.
 34. Liu, H. H., Mao, H. G., Dong, X. Y., Cao, H. Y., Liu, K., & Yin, Z. Z. (2019). Expression of MSTN gene and its correlation with pectoralis muscle fiber traits in the domestic pigeons (*Columba livia*). *Poultry science*, 98(11), 5265-5271.
 35. Ahad, A. W., M. Andrabi, S. A. Beigh, R. A. Bhat, and R. A. Shah. (2017). Applications of myostatin (MSTN) gene in the livestock animals and humans: A review. *Int. J. Curr. Microbiol. App. Sci.* 6:1807–1811.
 36. Gabillard, J., P. R. Biga, P. Rescan, and I. Seiliez. (2013). Revisiting the paradigm of myostatin in vertebrates: insights from fishes. *Gen. Comp. Endocrinol.* 194:45–54.
 37. Singh, S. P., P. Kumari, R. Kumar, M. Negi, S. K. Sharma, M. Gangwar, S. Kumar, and A. Mitra. (2014). Molecular characterization and phylogeny based analysis of complete coding sequence of myostatin (MSTN) gene in Indian goat breeds. *Small. Ruminant. Res.* 116:100–110.
 38. Manceau, M., J. Gros, K. Savage, V. Thome, A. McPherron, B. Paterson, and C. Marcelle. (2008). Myostatin promotes the terminal differentiation of embryonic muscle progenitors. *Genes. Dev.* 22:668–681

39. Velleman, S. G., C. S. Coy, and D. A. Emmerson. (2014). Effect of the timing of post-hatch feed restrictions on broiler breast muscle development and muscle transcriptional regulatory factor gene expression. *Poult. Sci.* 93:1484–1494.
40. Deveaux, V., B. Picard, J. Bouley, and I. Cassar-Malek. (2003). Location of myostatin expression during bovine myogenesis in vivo and in vitro. *Reprod. Nutr. Dev.* 43:527–542.
41. Saleh, M. M., Jalil, A. T., Abdulkereem, R. A., & Suleiman, A. A. (2020). Evaluation of Immunoglobulins, CD4/CD8 T Lymphocyte Ratio and Interleukin-6 in COVID-19 Patients. *TURKISH JOURNAL of IMMUNOLOGY*, 8(3), 129-134. <https://doi.org/10.25002/tji.2020.1347>
42. Turki Jalil, A., Hussain Dilfy, S., Oudah Meza, S., Aravindhyan, S., M Kadhim, M., & M Aljeboree, A. (2021). CuO/ZrO₂ nanocomposites: facile synthesis, characterization and photocatalytic degradation of tetracycline antibiotic. *Journal of Nanostructures*. <https://doi.org/10.22052/JNS.2021.02.014>
43. Sarjito, Elveny, M., Jalil, A., Davarpanah, A., Alfakeer, M., Awadh Bahajjaj, A. & Ouladsmame, M. (2021). CFD-based simulation to reduce greenhouse gas emissions from industrial plants. *International Journal of Chemical Reactor Engineering*, 20210063. <https://doi.org/10.1515/ijcre-2021-0063>
44. Marofi, F., Rahman, H. S., Al-Obaidi, Z. M. J., Jalil, A. T., Abdelbasset, W. K., Suksatan, W., ... & Jarahian, M. (2021). Novel CAR T therapy is a ray of hope in the treatment of seriously ill AML patients. *Stem Cell Research & Therapy*, 12(1), 1-23. <https://doi.org/10.1186/s13287-021-02420-8>
45. Jalil, A. T., Shanshool, M. T., Dilfy, S. H., Saleh, M. M., & Suleiman, A. A. (2022). HEMATOLOGICAL AND SEROLOGICAL PARAMETERS FOR DETECTION OF COVID-19. *Journal of Microbiology, Biotechnology and Food Sciences*, e4229. <https://doi.org/10.15414/jmbfs.4229>
46. Vakili-Samiani, S., Jalil, A. T., Abdelbasset, W. K., Yumashev, A. V., Karpisheh, V., Jalali, P., ... & Jadidi-Niaragh, F. (2021). Targeting Wee1 kinase as a therapeutic approach in Hematological Malignancies. *DNA repair*, 103203. <https://doi.org/10.1016/j.dnarep.2021.103203>
47. NGAFWAN, N., RASYID, H., ABOOD, E. S., ABDELBASSET, W. K., AL-SHAWI, S. G., BOKOV, D., & JALIL, A. T. (2021). Study on novel fluorescent carbon nanomaterials in food analysis. *Food Science and Technology*. <https://doi.org/10.1590/fst.37821>
48. Marofi, F., Abdul-Rasheed, O. F., Rahman, H. S., Budi, H. S., Jalil, A. T., Yumashev, A. V., ... & Jarahian, M. (2021). CAR-NK cell in cancer immunotherapy; A promising frontier. *Cancer Science*, 112(9), 3427. <https://doi.org/10.1111/cas.14993>
49. Abosooda, M., Wajdy, J. M., Hussein, E. A., Jalil, A. T., Kadhim, M. M., Abdullah, M. M., ... & Almashhadani, H. A. (2021). Role of vitamin C in the protection of the gum and implants in the human body: theoretical and experimental studies. *International Journal of Corrosion and Scale Inhibition*, 10(3), 1213-1229. <https://dx.doi.org/10.17675/2305-6894-2021-10-3-22>
50. Jumintono, J., Alkubaisy, S., Yáñez Silva, D., Singh, K., Turki Jalil, A., Mutia Syarifah, S., ... & Derkho, M. (2021). Effect of Cystamine on Sperm and Antioxidant Parameters of Ram Semen Stored at 4° C for 50 Hours. *Archives of Razi Institute*, 76(4), 923-931. <https://dx.doi.org/10.22092/ari.2021.355901.1735>