

**How to Cite:**

Yaseen, S. M., Al-Samarai, F. R., & Hasan, H. F. (2022). Histopathological and reproductive effect of tamsulosin and finasteride on induced Benign prostate hyperplasia in mice. *International Journal of Health Sciences*, 6(S1), 6076–6085. <https://doi.org/10.53730/ijhs.v6nS1.6062>

## **Histopathological and reproductive effect of tamsulosin and finasteride on induced Benign prostate hyperplasia in mice**

**Shukur Mahmood Yaseen**

Medical Biology and Anatomy Department, Faculty of Medicine, Diyala University, Iraq.

**Firas R. Al-Samarai**

Department of Veterinary Public Health, College of Veterinary Medicine, University of Baghdad, Iraq.

**Huda F. Hasan**

Department of Physiology and Pharmacology, College of Veterinary Medicine, University of Baghdad, Iraq.

**Abstract**---The prostate hyperplasia (BPH) was induced in male mice by subcutaneous injection of testosterone propionate (20 mg/kg) for 30 days. Fifty mice were divided equally into five groups, the first group (G1) was (negative control group), and the second group (G2) was (positive Control group) induced BPH previously and inoculated orally distilled water. The third group (G3) was induced BPH and treated orally with tamsulosin (0.156mg /kg), the fourth group (G4) was induced BPH and treated orally with Finasteride (1.495 mg /kg) and finally, the fifth (G5) was induced BPH and treated orally with a combination of tamsulosin and finasteride (0.0825, 0.7475) mg/kg respectively. The histopathological results showed prostate hyperplasia and abnormal proliferation of the epithelial and stromal cells with inflammation cells accompanying stenosis of acini in G2. Whereas showed a decrease in hyperplasia, and epithelial layer thickness in G3 and G4. Furthermore, prostate shrinkage and the glandular cavities trended towards the normal approach of the prostate in G5. The testosterone levels in G2 showed a significant increase ( $P<0.05$ ) as compared to other treated groups with a more significant decrease in G4 compared to other treated groups. the sperm motility% and count $\times 10^6$  showed a significant decrease ( $P<0.05$ ), with a significant increase in the sperm dead% and abnormality% in G2 as compared with all other treated groups, whilst showing a significant increase in motility% and count $\times 10^6$  and a decrease in the dead%, abnormality% in G5 when compared with all other treated groups. Concluded that the Combination dose was

highly competent and more effective in BPH treatment by minimizing the side effect of each drug by decreasing the dose of each one. Besides, the beneficial activity was due to the synergistic interaction drugs that promoted effects to decreasing symptoms of BPH.

**Keywords**--BPH, tamsulosin, finasteride, their Combination, Histopathological Changes, testosterone, and Sperm Count %.

## **Introduction**

Benign prostatic hyperplasia (BPH) is a common andrological disease among elderly males. characterized by histological proliferation of the epithelial cells in the transitional zone of the prostate which leads to lower urinary tract symptoms (LUTS), and constriction of the urethra {Fano et al., 2017}. Commonly, testicular hormones and aging are important elements leading to the genesis and development of BPH {Atawia et al., 2013}. BPH was attributed to a highly prevalent and costly condition that mostly affects older animals worldwide. (Hollingsworth and Wilt, 2014).

Alpha-blockers such as Tamsulosin and 5 $\alpha$ -reductase inhibitors such as finasteride are currently used for the medical management of BPH. The effect of alpha-blocker treatment initiates more rapidly than finasteride {Ishizuka et al., 2002}. However, these drugs had several systemic side effects such as dizziness, drowsiness, weakness, nausea, nasal congestion, rhinitis, allergies, diarrhea, and reduce fertility rate {Dahm et al., 2017}. Furthermore, finasteride was confirmed to reduce prostate cancer risk and decrease the prostate size by inhibiting the formation of the active androgen DHT metabolite {Gravas and Oelke, 2010}. Combination therapies are commonly applied to treat prostate size and symptoms simultaneously {Strand et al., 2017}. However, the combination between tamsulosin and finasteride effectively reduces symptoms of irritation and obstruction in BPH than is monotherapy. {Wang et al., 2019}. The aim of the current study was to investigate the role of Combination tamsulosin and finasteride in treating BPH by minimizing the side effect of each drug by decreasing prostate hyperplasia and infertility.

## **Methods and Materials**

### **Experiment design**

Fifty adult males of Swiss albino mice (Balb/c) strain, the ages were (7-8) weeks old and the weight was ranged (24 – 25 gm), mice were provided by the Iraqi Center of the Cancer Research in Baghdad at a period of 21 October 2020. Where they were bred and housed under the standard animal house in Lab Animals house from Medical College – Diyala University, they have been reared under an appropriate environment the temperature was ranged from 22- 26°C, with air-condition and a humidity-controlled between 45% - 55%, in light: dark cycle 12: 12-hour. the mice had food standards (pellets) and water (ad libitum). After the end of induction of BPH, the mice were divided into five groups and the period of treatment was 30 days, the treatment was given orally by stomach tube: (G1): ten

mice without induced BPH and without any treatment. (Negative control group). (G2): ten mice will be induced with BPH previously and inoculated with distilled water only. (Positive Control group). (G3): ten mice were induced with BPH and treated with a tamsulosin dose (0.156mg /kg). (G4): ten mice were induced BPH and treated with Finasteride dose (1.495 mg /kg). (G5): ten mice were induced BPH and treated with a Combination of Tamsulosin and Finasteride dose (0.0825, 0.7475) mg /kg respectively.

### **Prostate Histopathological Preparation**

After the end of the period of treatment, the histopathological examination of the mice prostate was conducted. The prostate histopathological examination procedure was made according to the standard operation procedure of Lab Iraqi Ministry of Health, 2013, mice were anesthetized with Diethyl ether inhalation and then sacrificed, the prostate samples were taken through anatomical process then placed in formalin solution 10% fixation, immediately for 24 hours prior steps of the examination, The histopathological examination of the mice prostate was done in Al-Secor laboratories in Diyala -Iraq.

### **Measurement of testosterone concentration in the serum:**

The determination of the levels of testosterone in mice serum was using an Enzyme-Linked Immune Sorbent Assay (ELISA) kit according to the manufacturer's instructions (Calbiotech, TE187S. 1935 Cordell Ct., CA92020), The absorbance was measured at 450 nm / 15 minutes, The concentration of testosterone in ng/ml was demonstrated by using a microplate ELISA reader (Bio-Rad Laboratories, Inc.), to obtain concentration Values expressed per mL.

### **Determination of the Sperms Function Count:**

The total Sperm count in seminal specimens, dependent on the collection of semen for the epididymis was isolated and placed in a Petri dish containing 1ml of PBS, which was measured by using a hemocytometer (Neuberg Type) chamber. The hemocytometer was filled with 50 µl of a sperm suspension by micropipette and covered by a cover slide. The sperms were counted in squares of red blood cells by using a light microscope x40. Estimation of sperm was made according to the following formula {Silverberg and Turner, 2012}.

### **Statistical analysis:**

The data were analyzed using one-way ANOVA and the least significant differences post hoc test were used to assess the significant differences among groups (SAS 2010).

## **Results**

### **Histopathological changes**

After ending the period of induction and treatment, the histopathological sections were taken in the current study, the sectioned tissue of induced BPH in mice after 30 days, showed prostate hyperplasia and abnormal proliferation of the epithelial

and stromal cells with inflammation cells. as well as, in after a period of treatment of 30 days was revealed severe hyperplasia of epithelial lining acini led to stenosis of acini, noticed the attached pappli project to another side as in figure (1,2). While G3 showed a decrease in hyperplasia, epithelial layer thickness, and proliferation of epithelial, stromal cells. as well, as less hyperplastic changes with few inflammatory cells close to normal as in figure (3). In addition, G4, showed a mild decrease in hyperplasia and the epithelial layer thickness, proliferation of epithelial and stromal cells, with a slight decrease in inflammatory cells, as in figure (4). Finally, G5, showed shrinkage of prostate size with a marked increase in density of the fibromuscular matrix and the glandular cavities trended towards the normal approach of prostate and were varying degrees of relief on prostatic epithelium hyperplasia and thickness of the epithelium and stromal cells, close to normal with less hyperplastic changes. as in figure (5).

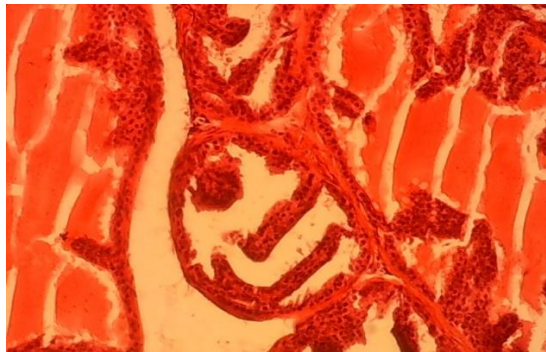


Figure (1): The sectioned tissue of induced BPH, showed changes in the lumen of prostate cells by growth (hyperplasia) and abnormal proliferation of the epithelial and stromal cells with inflammation cell, E &H (100X).

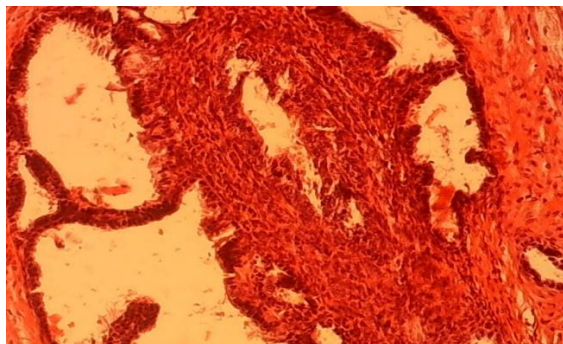


Figure (2): The sectioned tissue of induced BPH and treatment, showed severe ever hyperplasia of epithelial lining acini leading to stenosis of acini, and noticed the attached pappli project to another side. (H and E X100).

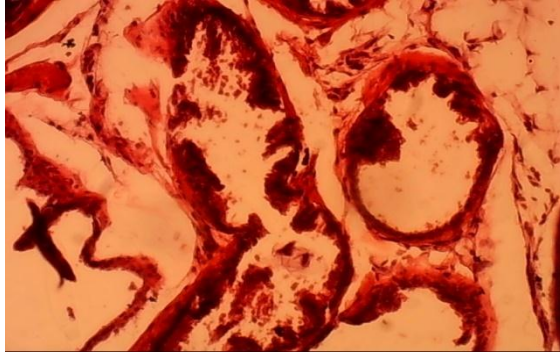


Figure (3): After treatment with tamsulosin, showed a decrease in hyperplasia, epithelial layer thickness, and proliferation of epithelial, stromal cells, E &H (100X).

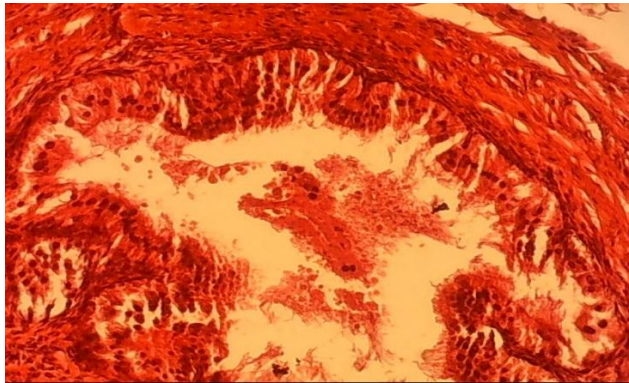


Figure (4): After treatment with finasteride, showed mildly decreased in hyperplasia and the epithelial layer thickness, proliferation of epithelial and stromal cells, with a slight decrease in inflammatory cells, E &H (100X).

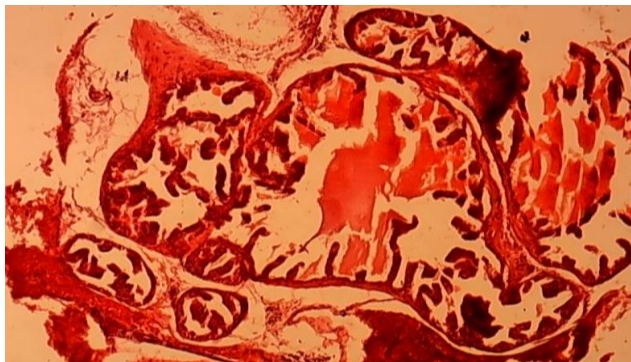


Figure (5): After treatment tamsulosin with finasteride, showed shrinkage of prostate size with a marked increase in density of the fibromuscular matrix, E &H (100X).

### Serum Testosterone(ng/ml) level:

Testosterone(ng/ml) were shown in table (1). the testosterone level of G2 was a significant increase ( $P<0.05$ ) in mean values ( $15.14\pm 1.03$ ) as compared with all other treated groups, the testosterone levels in G3 showed a significant increase ( $11.54\pm 0.86$ ) as compared with G1, G4, and G5. Whereas the testosterone levels in the G4 showed a more significant decrease ( $4.80\pm 0.88$ ) as compared with the other treated groups, as well as the G5 showed no significant difference ( $6.30\pm 0.46$ ) when compared with a G1.

Table 1:  
Effect of Tamsulosin, Finasteride, and their Combination on Serum Testosterone(ng/ml) of mice-induced BHP

Groups	Testosterone (ng/ml)
G1	$6.20\pm 0.41c$
G2	$15.14\pm 1.03a$
G3	$11.54\pm 0.86b$
G4	$4.80\pm 0.88d$
G5	$6.30\pm 0.46c$
LSD	1.40

\*Means with a different small letter in the same column are significantly different ( $P<0.05$ ),

### Sperm function count (Motility %, Dead %, Sperm Abnormality% and Sperm Concentration $\times 10^6$ )

The Sperm Motility% and Count $\times 10^6$  of the G2 showed a significant decrease ( $P<0.05$ ) and revealed a significant increase of the Sperm Dead% and Abnormality% as compared with all other treated groups, whereas, Motility% and Count $\times 10^6$  of G3 showed a significant increase ( $P<0.05$ ) as compared with G4 with a significant decrease as compared with G1 and G5, while Dead%, Abnormality% of G3 showed a significant decrease as compared with G2 with a significant increase as compared with G1, and G5. Motility% and Count $\times 10^6$  of the G5 showed a significant increase ( $P<0.05$ ) when compared with all other treated groups, while the Dead%, Abnormality% of G5 showed a significant decrease when compared with G2, G3 and no significant with G1. were shown in table (2).

Table 2  
Effect of Tamsulosin, Finasteride and their combination on Sperm function count of mice induced BHP

Group	Motility%	Dead%	Abnormality%	Count $\times 10^6$
G1	$77.60\pm 2.35a$	$12.00\pm 1.00c$	$11.00\pm 0.83c$	$20.00\pm 0.83a$
G2	$28.80\pm 1.85c$	$47.60\pm 1.07a$	$26.40\pm 2.35a$	$11.40\pm 0.81c$
G3	$62.60\pm 2.50b$	$20.20\pm 1.15b$	$19.20\pm 0.66b$	$15.00\pm 0.83bc$

G4	37.60±2.50d	31.20±2.45a	24.00±1.51a	13.40±1.20c
G5	72.60±2.50a	13.80±0.96c	12.80±0.66c	20.40±0.92a
LSD	6.95	4.27	4.05	2.76

\*Means with a different small letter in the same column are significantly different ( $P < 0.05$ ).

## Discussion

After the end period of treatment, the positive group revealed severe hyperplasia of epithelial lining leading to stenosis of acini, with extensive stroma and unremarkable fibro-muscular matrix, this finding agreed with {Mbaka et al., 2017}, the increases in cells numbers may be regarded to proliferation epithelial and stromal cells {Cunha et al., 2019}. Tamsulosin treated exhibited marked changes in prostate histopathology, such as decreased hyperplasia, and epithelial layer thickness with few inflammatory cells close to normal {Roehrborn, and Rosen 2008}. Finasteride exhibited marked an improvement in histo-architecture of prostatic tissue, which may be attributed to the stromal cell associated with the ability to inhibition of the 5 $\alpha$ -reductase type 2 expression {Hwangbo et al., 2018}. In addition to constituting the DHT secretion when enzyme within the stromal cell was the key androgenic amplification step {Roehrborn, and Rosen 2008}. Furthermore, the increased serum testosterone in the positive group may be regarded as the effect BPH had on the ability the stimulation of prostate gland and stimulation of cholesterol which is considered the precursor for the pregnenolone pathway leading to stimulation production of progesterone from testes and then converted to 17- hydroxyl progesterone that played an important role in the synthesis of androgens, especially testosterone, as well as, increase secretion of 5 alpha-reductase lead to increase testosterone hormone {Carson and Rittmaster, 2003}. Besides, the induction of BPH by testosterone promotes the stimulation of 5 $\alpha$ -reductase found mainly within the stromal and epithelial cells which converted testosterone into a potent androgen {Mbaka, et al., 2019}. The slight decrease of testosterone in the tamsulosin referred to the effects of a drug on reduced serum testosterone and gonadotropic concentrations by affecting steroid-forming enzymes in the testes or its inhibitory properties on the adrenergic {Kohistani et al., 2020}. the ability of finasteride in decreasing the levels of steroid hormones, by inhibition of 5 $\alpha$ -reductase activity led to reducing testosterone {Traish et al., 2015}. The combination of tamsulosin with finasteride showed a significant decrease in testosterone levels, because of the efficiency of Combination drugs in inhibiting the proliferation of prostatic cells by the synergistic effect of a combination {Odusanya, et al., 2017}.

The sperm function counts of the induced BPH resulted in a significant decrease in motility and sperms concentration, as well as a significantly increased in the dead sperms and sperms abnormality {Dzulsuhaimi et al., 2017}. This result can be attributed to BPH being increased prostatic oxidative stress, hormonal imbalance, and then sperms damage {Flores et al., 2017}. Tamsulosin caused an increase in motility, and sperm concentration, with a significant decrease in dead sperm, and sperm abnormality, these results may be regarded as to leading improved nearly normal levels of testosterone {Mokhtari and Shariati, 2007}. Whereas Finasteride caused a significant decrease in motility, and sperm concentration with an increase significantly in dead and sperm abnormality,

these findings agreed with {Chiba et al., 2011; Askar, 2017}. Moreover, finasteride was a synthetic inhibitor of 5 $\alpha$ -reductase and acted by blocking its enzymatic action resulting in erectile dysfunction, loss of libido, and poor sperm quality, such as oligospermia {Angrimani et al., 2020}. Combination treatment caused a more significant increase in motility, and sperm concentration, and a decrease significantly in dead, sperm abnormality, by providing a powerful and preferable therapeutic effect in treating BPH with less incidence of sexual side effects {Zhou et al., 2019}.

## Conclusion

In combination of tamsulosin with finasteride was more effective and competent in the treatment of BPH than only tamsulosin or finasteride alone due to the synergistic action by using the new formula of combination to minimize the side effects of each drug by decreasing the dose of each one.

## References

- Atawia, Reem T.; Mariane G. Tadros; Amani E. Khalif; Hisham A. Mosli, and Ashraf B. Abdel-Naim. (2013). "Role of the Phytoestrogenic, pro-Apoptotic and Anti-Oxidative Properties of Silymarin in Inhibiting Experimental Benign Prostatic Hyperplasia in Rats." *Toxicology Letters* 219 (2): 160–69. <https://doi.org/10.1016/j.toxlet.2013.03.002>.
- Askar, S. J. (2017). Role of aqueous extract of *Crocus sativus* to improvement of sexual dysfunctions induced by imipramine in male mice. *The Iraqi Journal of Veterinary Medicine*, 41(1), 92–97. <https://doi.org/10.30539/iraqijvm.v41i1.88>.
- Angrimani, Daniel S.R.; Luana C. Bicudo; Nuria Llamas Luceño; Bruno R. Rui; Matheus F. Silva; João D.A. Losano; Bart Leeman's; Ann Van Soom; and Camila I. Vannucchi (2020). Does Finasteride Treatment for Benign Prostatic Hyperplasia Influence Sperm DNA Integrity in Dogs? *Basic and Clinical Andrology* 30 (1): 1–8. <https://doi.org/10.1186/s12610-020-00108-2>.
- Benjamin O Odusanya ; Kehinde H Tijani; Emmanuel A Jeje ; Moses A Ogunjimi ; and Rufus W Ojewola (2017). Short-term Effect of Tamsulosin and Finasteride Monotherapy and their Combination on Nigerian Men with Benign Prostatic Hyperplasia. *Niger J Surg. Jan-Jun; 23(1): 5–10*.
- Carson, Culley, and Roger Rittmaster. (2003). "The Role of Dihydrotestosterone in Benign Prostatic Hyperplasia." *Urology. Elsevier Inc.* [https://doi.org/10.1016/S0090-4295\(03\)00045-1](https://doi.org/10.1016/S0090-4295(03)00045-1).
- Chiba, Koji; Kohei Yamaguchi; Fuping Li; Makoto Ando; and Masato Fujisawa. (2011). "Finasteride-Associated Male Infertility." *Fertility and Sterility* 95 (5): 1786.e9-1786.e11. <https://doi.org/10.1016/j.fertnstert.2010.12.001>.
- Cunha de Medeiros, P; Samelo, R. R ; Silva, A. P. G ; da Silva Araujo Santiago, M ; Duarte, F. A; de Castro, Í. B; and Perobelli, J. E. (2019). Prepubertal exposure to low doses of sodium arsenite impairs spermatogenesis and epididymal histophysiology in rats. *Environmental Toxicology*, 34(1), 83–91.
- Dahm, Philipp; Michelle Brasure; Roderick MacDonald; Carin M. Olson; Victoria A. Nelson; Howard A. Fink; Bruce Rwabasonga; Michael C. Risk; and Timothy J. Wilt. (2017). Comparative Effectiveness of Newer Medications for Lower Urinary Tract Symptoms Attributed to Benign Prostatic Hyperplasia: A

- Systematic Review and Meta-Analysis. *European Urology* 71 (4). <https://doi.org/10.1016/j.eururo.2016.09.032>.
- Daud, Dzulsuhaimi; Nur Faza Mohd Fekery; and Noorain Hashim. (2017). Reproductive Health of Rats with Benign Prostatic Hyperplasia Following Cosmos Caudatus Ethanolic Extract Consumption. *Journal of Applied Pharmaceutical Science* 7 (6): 202–5. <https://doi.org/10.7324/JAPS.2017.70630>.
- Fano, Diego ; Cinthya Vásquez-Velásquez ; Cynthia Gonzales-Castañeda ; Emanuel Guajardo-Correa ; Pedro A. Orihuela ; and Gustavo F. Gonzales. (2017). “N-Butanol and Aqueous Fractions of Red Maca Methanolic Extract Exerts Opposite Effects on Androgen and Oestrogens Receptors (Alpha and Beta) in Rats with Testosterone-Induced Benign Prostatic Hyperplasia.” *Evidence-Based Complementary and Alternative Medicine* 2017. <https://doi.org/10.1155/2017/9124240>.
- Flores, RB; DSR Angrimani; BR Rui; MM Brito; RA Abreu; and CI Vannucchi. (2017). “The Influence of Benign Prostatic Hyperplasia on Sperm Morphological Features and Sperm DNA Integrity in Dogs.” *Reproduction in Domestic Animals* 52 (April). <https://doi.org/10.1111/rda.12817>.
- Gravas, Stavros; and Matthias Oelke. (2010). “Current Status of 5 $\alpha$ -Reductase Inhibitors in the Management of Lower Urinary Tract Symptoms and BPH.” *World Journal of Urology* 28 (1): 9–15. <https://doi.org/10.1007/s00345-009-0493-y>
- Hollingsworth, John M; and Timothy J. Wilt. (2014). “Lower Urinary Tract Symptoms in Men.” *BMJ* (Online). *BMJ Publishing Group*. <https://doi.org/10.1136/bmj.g4474>.
- Hyun Hwangbo; Da He Kwon; Eun Ok Choi ; Min Yeong Kim ; Kyu Im Ahn ; Seon Yeong Ji1 ; Jong Sik Kim ; Kyung-Il Kim ; No-Jin Park ; Bum Hoi Kim ; Gi-Young Kim ; Su-Hyun Hong ; Cheol Park ; Ji-Suk Jeong ; and Yung Hyun Choi1. (2018). Corni Fructus attenuates testosterone-induced benign prostatic hyperplasia by suppressing 5 $\alpha$ -reductase and androgen receptor expression in rats. *Nutrition Research and Practice* 2018;12(5):378-386 ©2018 The Korean Nutrition Society and the Korean Society of Community Nutrition.
- Ishizuka, Osamu; Osamu Nishizawa; Yoshihiko Hirao; and Shinichi Ohshima. (2002). “Evidence-Based Meta-Analysis of Pharmacotherapy for Benign Prostatic Hypertrophy.” *International Journal of Urology* 9 (11): 607–12. <https://doi.org/10.1046/j.1442-2042.2002.00539.x>.
- Mbaka, Godwin; Charles Anunobi; Samson Ogunsina; and Daniel Osiagwu. (2017). “Histomorphological Changes in Induced Benign Prostatic Hyperplasia with Exogenous Testosterone and Estradiol in Adult Male Rats Treated with Aqueous Ethanol Extract of Secamone Afzelii.” *Egyptian Journal of Basic and Applied Sciences* 4 (1): 15–21. <https://doi.org/10.1016/j.ejbas.2016.11.003>.
- Mbaka, Godwin; Steve Ogbonna; Adeola Sulaiman; and Daniel Osiagwu. (2019). “Histomorphological Effects of the Oil Extract of Sphenocentrum Jollyanum Seed on Benign Prostatic Hyperplasia Induced by Exogenous Testosterone and Estradiol in Adult Wistar Rats.” *Avicenna Journal of Phytomedicine* 9 (1): 21–33. <https://doi.org/10.22038/ajp.2018.24039.1882>.
- Mokhtari, M.; M. Shariati; and J. Amiri. (2007). “Effects of Tamsulosin on Serum Testosterone and Gonadotropins Concentration in Adult Male Rats.” *Journal of Rafsanjan University of Medical Sciences* 6 (1): 1–6. <http://journal.rums.ac.ir/article-1-282-en.html>.

- Roehrborn, Claus G.; and Raymond C. Rosen. (2008). "Medical Therapy Options for Aging Men with Benign Prostatic Hyperplasia: Focus on Alfuzosin 10 Mg Once Daily." *Clinical Interventions in Aging*. Dove Press. <https://doi.org/10.2147/cia.s3635>.
- Silverberg, Kaylen M.; and Tom Turner. 2012. "Evaluation of Sperm." In Textbook of Assisted Reproductive Techniques, Volume One: *Laboratory Perspectives*. Informa Healthcare. <https://doi.org/10.3109/9781841849713.004>.
- Strand, Douglas W.; Daniel N. Costa ; Franto Francis; William A. Ricke ; and Claus G. Roehrborn. (2017). "Targeting Phenotypic Heterogeneity in Benign Prostatic Hyperplasia." *Differentiation*. Elsevier Ltd. <https://doi.org/10.1016/j.diff.2017.07.005>.
- Traish, Abdulmageed M.; Karim Sultan Haider; Gheorghe Doros; and Ahmad Haider (2015). Finasteride, Not Tamsulosin, Increases Severity of Erectile Dysfunction and Decreases Testosterone Levels in Men with Benign Prostatic Hyperplasia. *Hormone Molecular Biology and Clinical Investigation* 23 (3). <https://doi.org/10.1515/hmbci-2015-0015>.
- Wang, Xiaolong; Yiming Wang ; Christian Gratzke ; Christian Sterr ; Qingfeng Yu ; Bingsheng Li ; Frank Strittmatter ; et al. (2019). "Ghrelin Aggravates Prostate Enlargement in Rats with Testosterone-Induced Benign Prostatic Hyperplasia, Stromal Cell Proliferation, and Smooth Muscle Contraction in Human Prostate Tissues." *Oxidative Medicine and Cellular Longevity* 2019 (November). <https://doi.org/10.1155/2019/4748312>.
- Yegane Kohestani; Bentolhoda Kohestani; Zahra Shirmohamadi; and Masoumeh Faghani, (2020): Effect of tamsulosin on testis histopathology and serum hormones in adult rats: Experimental study. *Int J Reprod Biomed*. 2020 Jul; 18(7): 531–538.. doi: 10.18502/ijrm.v13i7.7370
- Zhou, Zhongbao; Yuanshan Cui; Jitao Wu; Rui Ding; Tong Cai; and Zhenli Gao. (2019). "Meta-Analysis of the Efficacy and Safety of Combination of Tamsulosin plus Dutasteride Compared with Tamsulosin Monotherapy in Treating Benign Prostatic Hyperplasia." *BMC Urology* 19 (1). <https://doi.org/10.1186/s12894-019-0446-8>.