

**How to Cite:**

Parakh, K., Kothari, S., Daga, P., Harsha, G. V. D., Sarda, R., & Tamrakar, A. (2021). Lesion sterilization and tissue repair therapy using GAM antibiotic paste: A series of cases. *International Journal of Health Sciences*, 5(S2), 453–458.  
<https://doi.org/10.53730/ijhs.v5nS2.6189>

## **Lesion sterilization and tissue repair therapy using GAM antibiotic paste: A series of cases**

**Keyura Parakh**

Associate Professor, Department of Pedodontics and Preventive Dentistry, Chhattisgarh Dental College and Research Institute, Rajnandgaon, Chhattisgarh

**Sonal Kothari**

Associate Professor, Department of Pedodontics and Preventive Dentistry, Pacific Dental College and Research Center, Udaipur, Rajasthan

**Pragya Daga**

Associate Professor, Department of Pedodontics and Preventive Dentistry, Kusum Devi Sunderlal Dugar Jain Dental College and Hospital, Kolkata, West Bengal

**Harsha G. V. D.**

Associate Professor, Department of Orthodontics & Dentofacial Orthopaedics, Vishnu Dental College, Bhimavaram, Andhra Pradesh

**Rasna Sarda**

Associate Professor, Department of Pedodontics and Preventive Dentistry, Chhattisgarh Dental College and Research Institute, Rajnandgaon, Chhattisgarh

**Abhishek Tamrakar**

Associate Professor, Department of Pedodontics and Preventive Dentistry, Chhattisgarh Dental College and Research Institute, Rajnandgaon, Chhattisgarh

**Abstract**--Despite the efforts to prevent dental caries among children, premature loss of primary teeth due to pulp and periapical diseases is a common problem. The effect of this premature loss on the development of dentition is a matter of great interest. Importantly, the primary teeth are considered as natural space maintainers and therefore should be retained until their natural exfoliation. Based on these issues and concerns, the concept of “Lesion sterilization and tissue repair (LSTR)” therapy proposed by the Cariology Research Unit of the Niigata University School of Dentistry, would be preferable to current endodontic treatments.

**Keywords**---LSTR, lesion sterilization, tissue repair, GAM antibiotic paste.

## **Introduction**

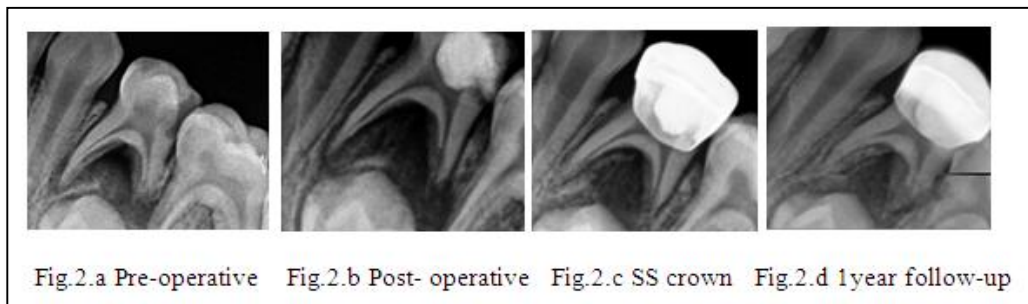
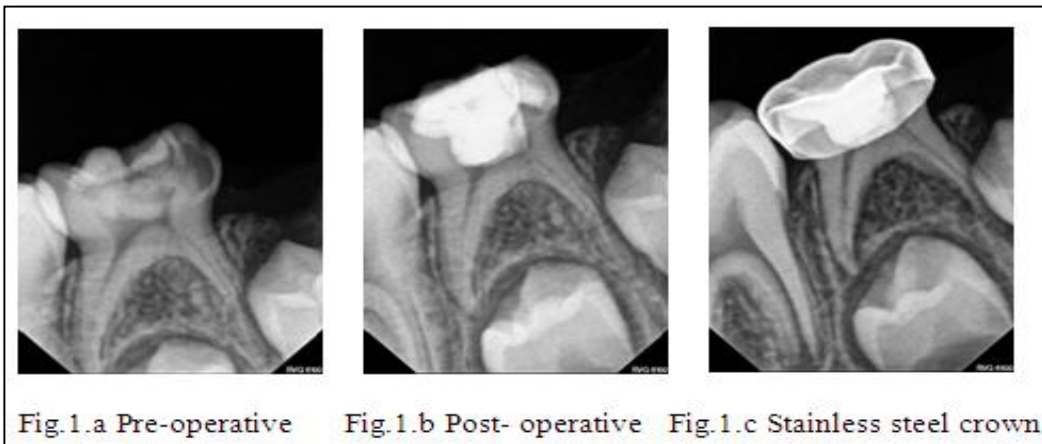
Lesion Sterilization and Tissue Repair therapy employs the use of a mixture of antibacterial drugs for disinfection of oral infectious lesions, including dentinal, pulpal and periapical pathologies. Repair of damaged tissue can be expected if the lesions are disinfected. Dental infections are polymicrobial in nature. Therefore, it becomes necessary to prescribe combination of more than one antibiotic, to ensure that all causative agents are targeted effectively. This also promotes tissue regeneration with the help of host's natural tissue recovering process. In the following cases a combination of Gentamycin, Amoxicillin and Metronidazole (GAM antibiotic paste) is used to ensure complete eradication of all pathogenic microorganisms in pulpal and periapical lesions.

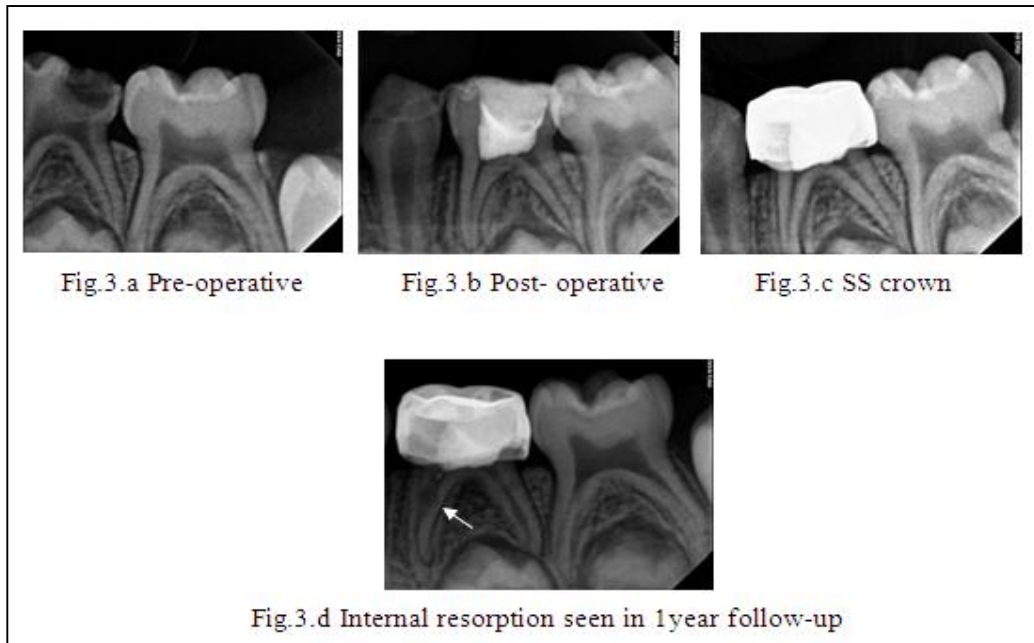
## **Case reports**

**Case 1:** A 6-year-old boy visited our clinic along with his parents with the chief complaint of pain in lower right back tooth region of the jaw. The pain was severe and aggravated on chewing. Patient took over-the-counter medication for pain relief before visiting the clinic. On clinical examination it was seen that mandibular right deciduous second molar (85) was deeply carious. Radiographically, the carious lesion was extending till the pulp horns with no/minimum furcation involvement (Fig.1.a). The patient was explained about the GAM-LSTR therapy and treatment was performed in the same visit. First inferior alveolar nerve block was given. Once the tooth was anesthetized all the carious dentine was excavated with the help of spoon excavator and with a large round bur. Access to the pulp chamber was achieved making sure all the overhanging edges were eliminated. Next, the coronal pulp tissue was removed using a sterile sharp spoon excavator and the cavity was irrigated with saline. Haemorrhage was controlled by applying sterile cotton pellet moistened with saline against the pulp stumps and maintained for 1 minute. The cavity was then dried with further application of cotton pellets. The GAM antibiotic paste was placed at the root canal orifices followed by GIC restoration (Fig.1.b). After 15 days, the tooth was restored with stainless steel crown cemented with luting glass ionomer cement (Fig.1.c). On further follow-ups the patient showed no signs of any pain and swelling, making the procedure a success.

**Case 2:** There was another case where mandibular left deciduous first molar (74) was carious with furcation involvement as was seen in radiograph (Fig.2.a). The treatment advised was pulpectomy but the patient was not cooperative hence, GAM-LSTR therapy was planned for the case. The tooth was anesthetized and access opening was done. After the removal of all the coronal pulp and irrigation of the cavity GAM antibiotic paste was placed at the canal orifices and pulpal floor. Then the tooth was restored with glass ionomer cement (Fig.2.b) followed by stainless steel crown after 15 days. The case was followed up for 1 year and it was found that all the clinical signs and symptoms were relieved and radiographically the furcation radiolucency also healed.

**Case 3:** Another case of pulp therapy that came to our clinic was again of mandibular left deciduous first molar (74). The tooth was carious with dentin and pulpal involvement (Fig.3.a). The child was very young and timid. Also, the parents wanted to get the treatment done in one single visit. The procedure of pulpectomy as well as GAM-LSTR therapy was explained to them along with all the pros and cons. Parents opted for GAM-LSTR therapy. The procedure of non-instrumentation endodontic treatment (NIET) using GAM antibiotic paste was performed (Fig.3.b) and stainless-steel crown was cemented after 15 days (Fig.3.c). All the clinical signs and symptoms were relieved and during the follow-ups also no complain of any pain and swelling was noticed. Although, during the follow-up procedure internal resorption was seen in mesial root of the same tooth radiographically (Fig.3.d).





### Discussion

In the quest for providing optimal dental care, the age-old maxim of 'prevention is better than cure' holds true. In this endeavour, the Pedodontists are more evenly poised to carry the mantle of providing the required services. One of the approaches is preservation of primary dentition, provided that it can be restored to function and remain free from disease. An intact tooth successfully disinfected and with a restored clinical crown is a superior space maintainer than an appliance.

Another challenge that a Pedodontist faces is behaviour management of uncooperative children. LSTR is a boon for this major issue as it is a simple procedure and requires less chair side time by reducing the need for multiple visits. LSTR or Non-instrumental Endodontics Treatment (NIET) endodontic treatments are new biologic approaches in the treatment of carious lesions with or without pulp and periapical involvement using antibiotics. GAM antibiotic paste eliminates causative bacteria from lesions, and after sterilization the lesions are repaired and/or regenerated by the host's natural tissue recovery process. An inflamed pulp, even the spontaneous pain recovers after LSTR treatment. In the above-mentioned cases we did not perform any biomechanical preparation as done in conventional pulpectomies. This prevented the unnecessary enlargement of root canals and irritation to periapical tissues, especially in teeth with root resorption.

Cases 1 and 2 showed both clinical and radiographic success, whereas case 3 showed only clinical success as internal resorption was seen radiographically by the end of one year follow-up. Previous investigators have also reported increase in radiolucency and internal resorption as the most frequent post-operative

radiological failures observed in primary molars after LSTR. Prabhakar et al. and Pinky et al. noted increase in bone loss in five teeth and two teeth out of 30 and 20 teeth respectively. Trairatvorakul and Detsomboonrat reported total 38 failure cases when observed for 24 months. Out of these failures, six teeth showed static radiolucency, 26 teeth showed increase in radiolucency and six teeth showed internal resorption. Parakh and Shetty reported a 93.33% clinical success and 73.33% radiographic success in cases with no periapical and furcation involvement using non-instrumentation GAM-LSTR technique. Also, it was found that cases with periapical and furcation involvement showed 100% clinical success but the radiographic success was about 86.67%.

The findings of internal resorption could be a result of an inflammatory response of the residual pulp. The GAM medicament can produce an inflammatory reaction which may be due to vascular changes in the pulp involving the formation of granulation tissue with an accompanying metaplasia of connective tissue and macrophages to form osteoclast-like multinucleated giant odontoclasts. Internal resorption seen in our cases may have resulted from coronal pulp amputation without gentle technique, heat generation at the tip of the bur, pressure from placing the medicament, incomplete pulp amputation, or residual inflamed pulp tissue.

The high antibacterial effectiveness of GAM antibiotic paste and non-instrumentation technique makes LSTR more suitable in cases of poor prognosis. Another clinical advantage of GAM-LSTR is less chair time. Nevertheless, similarly to the root canal materials, we would not advocate this in a child at risk of infective endocarditis. Also, the potential sequelae of this treatment should be considered such as the risk of damage to the successor or cyst formation if a focus of chronic infection is left. However, further clinical and histological studies with longer follow-ups till the period of tooth exfoliation are advocated to ascertain the efficacy of this novel treatment modality.

## **Conclusion**

Hence it can be concluded that the technique of LSTR using GAM antibiotic paste requires more studies as only few cases have been done using GAM. Also, it helps to preserve the primary tooth until its exfoliation, reducing the need for unnecessary extraction and placement of a space maintainer.

## **References**

- Hoshino E. Sterilization of carious lesions by drugs. *J Jap Assoc Dent Sci* 1990; 9:32-37.
- Shetty et al. Antibacterial property of allopathic medicine versus phyto medicine: An in vitro study. *Int J Curr Microbiol App Sci* 2015; 4(2):896-902
- Belanger GK. Pulp therapy for the primary dentition. In: Pinkham JR, editor. *Pediatric Dentistry Philadelphia, PA, USA: Saunders; 1988. P. 257-67.*
- Takushige T, Cruz EV, Asgor MA, Hoshino E. Endodontic treatment of primary teeth using a combination of antibacterial drugs. *Int Endod J* 2004; 37:132-38.

- Prabhakar AR, Sridevi E, Raju OS, Satish V. Endodontic treatment of primary teeth using combination of antibacterial drugs: An *in vivo* study. J Indian Soc PedodPrev Dent 2008;26 Suppl1:S5-10
- Pinky C, Shashibhushan KK, Subbareddy VV. Endodontic treatment of necrosed primary teeth using two different combinations of antibacterial drugs: An *in vivo* study. J Ind Soc PedodPrev Dent 2011;29:121-27.
- Trairatvorakul C, Detsomboonrat P. Success rates of a mixture of ciprofloxacin, metronidazole, and minocycline antibiotics used in the non-instrumentation endodontic treatment of mandibular primary molars with carious pulpal involvement. Int J Paediatr Dent 2012;22:217-27
- Parakh K, Shetty RM. Evaluation of paste containing gentamicin, amoxicillin and metronidazole in endodontic treatment of primary molars *in vivo*. Chin J Dent Res 2019; 22:57-64.
- Tronstad L. Root resorption - etiology, terminology and clinical manifestations. Endod Dent Traumatol 1988; 4:241-52.
- Wedenberg C, Lindskog S. Experimental internal resorption in monkey teeth. Endod Dent Traumatol 1985; 1:221-27.
- Agarwal M, Das UM, Vishwanath D. A comparative evaluation of non-instrumentation endodontic techniques with conventional ZOE pulpectomy in deciduous molars: An *in vivo* study. World J Dent 2011; 2(3):187-92