

**How to Cite:**

Jabber, E. Y., Al janabi, O. H. K., & Al-khafaji, Z. A. (2022). Isolation and identification of *Aspergillus fumigatus* from Immunocompromised patients in AL- Najaf Province. *International Journal of Health Sciences*, 6(S1), 5689–5703. <https://doi.org/10.53730/ijhs.v6nS1.6240>

# Isolation and identification of *Aspergillus fumigatus* from immunocompromised patients in AL- Najaf Province

**Ehab Y. Jabber**

Dept. Biology, Faculty of science, Kufa University, Najaf, Iraq

**Oday H. Kadhim Al janabi**

Dept. Microbiology, Faculty of Medicine, Babylon University, Babylon, Iraq

**Zaytoon A. Al-khafaji**

Dept. Microbiology, Faculty of Medicine, Babylon University, Babylon, Iraq

**Abstract**--The present study was conducted to isolation and identification of *Aspergillus fumigatus*. Isolated from immunocompromised patients with (Diabetes, Cancer) by different identification methods including direct examination, laboratory culture and electron microscopy. During the period from (July to September 2016), a total of 50 swab were collected from immunocompromised patients with attending to the in AL- Sadder Medical City (the Center for Diabetes and Endocrinology) and (Euphrates middle Center for cancer diseases). In AL-Najaf Governorate, the samples were collected as following: 30 swab from the eyes of cancer patients who were suffering from prostate, leukemia, stomach and intestines cancer, also 20 swabs from the ears of diabetic patients. The percentage of female to male was as following, 29 females (58%) males and 21 (42%). In this study, the results show that the incidence of aspergillosis in women was higher than the male. The results of the present study reveal that the prevalence of aspergillosis from patient with cancer was more than diabetes patients which was 18 (66.66%) and 9 (33.33%), respectively. When culturing ears & eyes samples on the primary isolation media Sabouroud dextrose agar (SDA) and the secondary media on other potato dextrose agar (PDA), T.e results reveal the presence of 27 isolates belong to genus *Aspergillus fumigatus* which are 13 female and 5 male cancer patients, 5 females and 4 males of diabetic patients.

**Keywords**--Immunocompromised patients, *Aspergillus fumigatus*, Aspergillosis, saprophytic fungus, Otomycosis.

## Introduction

*Aspergillus* is a large genus composed of more than 180 accepted anamorphic species [1], *Aspergillus fumigatus* is saprophytic fungus that plays essential role in recycling environmental carbon and nitrogen [2, 3,4]. Its natural ecological niche is the soil, where in it survives and grows on organic debris. Although this species is not the most prevalent fungus in the world, it is considered one of the most ubiquitous of those with air borne conidia [5, 6, and 7]. It speculates abundantly, with every conidial head producing thousands of conidia. The conidia released into the atmosphere have a diameter small enough (2 to 3  $\mu$ m) to reach the lung alveoli [8, 9]. *Aspergillus fumigatus* does not have an elaborate mechanism for releasing its conidia into the air; dissemination simply relies on disturbances of the environment and strong air currents. Once the conidia are in the air, their small size makes them buoyant, tending to keep them airborne both indoors and outdoors. Environmental surveys indicate that all humans will inhale at least several hundred *A. fumigatus* conidia per day [10, 11, and 12]. Identification of *Fumigatus* is based predominantly upon the morphology of the conidia and conidiophores. The organism is characterized by greenish late conidia, 2.5 to 3  $\mu$ m in diameter, produced in chains basipetally from greenish phialid, 6-8 by 2-3  $\mu$ m in size. A few isolates of *Aspergillus fumigatus* are pigmentless and produce white conidia [13].

The study of immunocompromised patients is a condition where the mechanism of host defenders is impaired (weakened or absent) by primary (congenital) or secondary (acquired) causes [14]. The importance of fungal infections is still growing due to the following reasons [15]: (1) The mycoses are produced by fungi that are widely distributed in the environment and, therefore, very difficult to eradicate. (2) The clinical manifestation of disease caused by fungal infection can be highly variable. (3) Diagnosis of these diseases can be problematic because of the difficulty of interpreting the very different clinical pictures in individuals in the presence of colonization, infection and/or disease. (4) So far, there are no vaccines available against these diseases. (5) Treatment is problematic: compared to the antibacterial, the number of antifungal drugs available at present is very small and with much greater difficulty in production.

Otomycosis or fungal otitis externa has typically been described as a fungal infection of the external auditory canal with infrequent complications involving the middle ear. Although rarely life threatening, the disease is a challenging and frustrating entity for both patients and otolaryngologists as it frequently requires long-term treatment and follow-up. Despite this, there could be recurrences.

Otomycosis is one of the common conditions encountered in a general otolaryngology clinic setting and its prevalence has been quoted to range from 9% [16] to 27.2% [17,18] among patients who present with signs and symptoms of otitis externa and up to 30% [4-6] in patients with discharging ears. It is worldwide in distribution with a higher prevalence in the hot, humid, and dusty areas of the tropics and subtropics [17, 18, 19, 20]. Overview of the literature reveals otomycosis to be a common medical problem in India [21, 22].

Fungi can either be the primary pathogen or be superimposed on bacterial infections. Most patients suffering from early otomycosis complain of severe itching, which often progresses to pain, hearing loss, and often leading to tympanic [22–23].

In recent years, opportunistic fungal infections have gained greater importance in human medicine, perhaps because of the increasing number of immunocompromised patients [24]. However, such fungi may also produce infection in immunocompetent hosts [25]. In immunocompromised patients, treatment of otomycosis should be vigorous to prevent complications such as hearing loss and invasive temporal bone infection [26,27]. An immunocompromised host is more susceptible to otomycosis. Patients with diabetes, lymphoma, or AIDS and patients undergoing or receiving chemotherapy or radiation therapy are at increased risk for potential complications for otomycosis [28].

Fungal infection of the cornea (keratomycosis, mycotic keratitis or fungal keratitis) was described for the first time in Germany in the year 1879.

Factors such as corticosteroid use, the penetration of pathogens, and the popularization of topical antibiotics, which create an environment of lower competition among microorganisms on the ocular surface, are suggested as key factors for such increase. Despite the emergence of new drugs, cure remains difficult in many cases. Compared to antibacterial, antifungals have a lower efficacy due to their mechanism of action (usually fungistatic, with fungicidal action being dose dependent), lower tissue penetration, and the indolent nature of the infection [29].

Electron Microscopes are scientific instruments that use a beam of highly energetic electrons to examine objects on a very fine scale. This examination can yield information about the topography (surface features of an object), morphology (shape and size of the particles making up the object), composition (the elements and compounds that the object is composed of and the relative amounts of them) and crystallographic information (how the atoms are arranged in the object). Electron Microscopes were developed due to the limitations of light microscopes that are limited by the physics of light to 500x or 1000x magnification and a resolution of 0.2 micrometers.

The Transmission Electron Microscope (TEM) was the first type of Electron Microscope to be developed and is patterned exactly on the Light Transmission Microscope except that a focused beam of electrons of light to "see through" the specimen.

Electrons in scanning electron microscopy penetrate into the sample within a small depth, so that it is suitable for surface topology, for every kind of samples. It can also be used for chemical composition of the sample's surface since the brightness of the image formed by back scattered electrons is increasing with the atomic number of the elements. This means that regions of the sample consisting of light elements (low atomic numbers) appear dark on the screen and heavy elements appear bright. Back scattered electrons are used to form diffraction images, called EBSD, that describe the crystallographic structure of the sample. In SEM, X-rays are collected to contribute in Energy Dispersive X-ray Analysis (EDX or EDS),

which is used to the topography of the chemical composition of the sample consequently. SEM is only used for surface images and both resolution and crystallographic information are limited (because they are only referred to the surface). Other constraints are firstly that the samples must be conductive, so non-conductive materials are carbon-coated and secondly, that material with atomic number smaller than the carbon are not detected with SEM [30].

### **Aim of the study**

Isolate and identify of *Aspergillus fumigatus* from ear and eye of immunocompromised patients based on traditional method (Macroscopic and Microscopic features) and measurement dimensions of *Aspergillus fumigatus* by electron microscope.

### **Materials and Methods**

#### **Equipment's and apparatus**

The equipment's and apparatus were used throughout the study are listed in table 2-1:

Table 2-1  
Equipment's and apparatus used in the present study

Equipment & Apparatuses	Manufacture's country
Autoclave	Harayma (Japan)
Bunsen burner	Iraqi
Camera	Canon –Japan
Conical flasks	BBL- USA
Disposable Petri dishes	BBL- USA
Gloves TG medical	(Malaysia)
Hood	Lab TECH
Incubator	Memmert , Germany
Light microscope	Olympus (Japan)
Refrigerator	Concord , Italy
Sensitive balance	Sartorius (Germany)
Slides & cover slides	BBL- USA
Sterile cotton swabs	Himedia(India)
Sterile syringes	Iraqi
Water distiller	GFL(Germany)
Electron microscope	Germany

#### **mChemical and Biological Materials**

The chemical and biological materials that used throughout them study were summarize in table 2-2:

Table 2-2  
The Biological and Chemical Materials were used in the present study

Materials	Manufacture's country
Chloramphenicol	Iraq
Normal saline	Haidylena (Egypt)
Lacto phenol cotton blue	Himedia – India

### Culture media

The following culture media in the table 2-3 were used for proceeding of experiments and tests in this study:-

Table 2-3  
The Culture media were used in the present study

Potato Dextrose Agar(PDA)	Himedia – India
Sabouraud's dextrose Agar(SDA)	Himedia – India

### Methods

#### Patients

A total of 27 specimens were collected from 50 samples the randomly recruited immunocompromised patients, aged between (5 years old - above 65 years old)with history of aspergillosis, during the period from (July to September 2016).All specimens were collected from in AL-Sadder Medical City (The center for Diabetes and Endocrinology) and (Euphrates middle Center for cancer diseases) in AL- Najaf governorate. Informational were recorded from all patients using a private data.

#### Specimens collection

The specimens were taken by sterilized cotton swabs from ears and eyes. They were sub cultured on Potato dextrose agar (PDA) was performed and incubated at 25°C for 1-5 days for visible growth of *A. Fumigatus* colonies. Other *A. fumigatus* were discarded as a negative.

#### Preparation of culture media

All culture media listed in (2.1.2) were prepared according to the instruction of manufactures fixed on the container. They were sterilized by autoclave at 15 psi/inch<sup>2</sup> in 121 C° for 15 min.

#### ***Sabouraud's dextrose agar (SDA) with chloramphenicol***

This medium agar was prepared according to the manufacturer's instructions by suspending 65 gm. of SDA powder in 1000 ml of distilled water, final pH was adjusted to 6.8 and then were added 250 mg / L from Chloramphenicol antibiotic prior to autoclaved [31] This medium was used for cultivating pathogenic and

commensal fungi and yeasts, Chloramphenicol is a broad-spectrum antibiotic inhibitory to a wide range of Gram-negative and Gram-positive bacteria.

### ***Potato dextrose agar (PDA) with chloramphenicol***

Potato dextrose agar was prepared according to the manufacturer's instructions by suspending 39 gm. of PDA powder in 1000 ml of distilled water final pH was adjusted to 6.8 and then were added 250 mg / L from Chloramphenicol antibiotic prior to autoclaved [31].

### **Preparation of Stains and Solution**

#### ***Cotton blue***

This stain was stored in sterile dark bottle; it is used to staining hypha & conidia [32].

#### **Identification of *Aspergillus fumigatus* isolates**

*Aspergillus fumigatus* isolates were identified depending on the morphological

Features on culture medium and electron microscope as them following:

#### **Colonial morphology**

All isolates were grown on Sabouraud dextrose agar, they plates were incubated at 25C° for 1-5 days.to isolate pure *Aspergillus fumigatus* colonies to examine their shape,size,color and consistence *Aspergillus* dependence highest color .

#### **Microscopic Examination**

A portion of colonies removed from the culture, placed on a slide with lacto phenol cotton blue, and tested under the light microscope [33].And *Aspergillus fumigatus* were streaked in the Sabouraud dextrose agar (SDA) plate and incubated at 25C° for 5 days, before proceeding to the exam by electron microscope.

### **Results**

#### **Patients**

The present study included collection 27 specimen's infection from 50 samples the randomly recruited immunocompromised patients. From in AL- Sadder Medical City (the Center for Diabetes and Endocrinology) and (Euphrates middle Center for cancer diseases) .In AL-Najaf Governorate. The specimens were included: - cancer was more than diabetes patients, which was 18 (66.66%), and 9 (33.33%), respectively. Were collected from females29 (58%) males and 21 (42%). as shows in table (4-1).

Invasive external otitis typically occurs in elderly diabetic patients [34,35] .Fungal pathogens ,mostly *Aspergillus* occurs in immunocompromised patients, usually with profound and long-lasting neutropenia or under long-term steroid therapy

[36] as well as in patients with uncontrolled diabetes mellitus[37]. *A. fumigatus* is the leading cause of death in patients with the Chronic granulomatous disease (CGD), although patients usually succumb to aspergillosis only under conditions of heavy inoculate or following treatment with immunosuppressive drugs [38]. This fungus grows best man aerobically .The Primary sites of fungal infection are respiratory tract, external auditory canal, asopharynx, cornea, gastrointestinal tract and occasionally the skin. Opportunistic fungal infections usually occur in immune-compromised patients, but can infect healthy individuals as well [39-42]. *Aspergillus fumigatus* most often encountered in among immune-compromised patients[40] *Aspergillus* species continue to be an important cause of life threatening infection in immunocompromised patients [41]. Fungal infection is an important cause of morbidity and mortality in immunocompromised pediatric cancer patients [42].

The risk of fungal infection in patients with cancer is also a function of the balance between the integrity of host defense mechanisms and the intensity of exposure to potentially pathogenic microorganisms in the host's environment (especially hospital pathogens) [43]. In addition, the use of wide spectrum antibiotics, treatment with corticosteroids and cytostatic substances, and invasive surgical procedures often predispose children to the development of fungal infections [44]. Opportunistic fungal infections are gaining greater importance in human medicine as a result of possibly huge number of immunocompromised patients[45]. In immunocompromised patients ,is important that the treatment of otomycosis be vigorous, to minimize complications such as hearing loss , tympanic membrane perforations [46]. General cellular immunity is reduced in situations such as diabetes, steroid administration, HIV infection, chemotherapy and malignancy .This makes an immunocompromised host susceptible to fungal infections. Normal bacterial flora is one of the host defense mechanism against fungal infections .This mechanism is altered in patient patients using antibiotics ear drops and cause otomycosis [47] Ear cleaning habits may also contribute to pathogenesis [48].

*Aspergillus* is considered a primary colonizer of the ear canal [49]. *Aspergillus* is the most commonly reported isolate in otomycosis across the world, followed by *Candida* [50] *Aspergillus* is known to cause endogenous endophthalmitis in the immunocompromised and less commonly the immunocompetent. Exogenous *Aspergillus* endophthalmitis is even rarer, considered the most common form of post-operative fungal endophthalmitis [51 ] Approximately 1 in 8 otitis external infections are fungal in origin. Approximately 90% of these are caused by *Aspergillus* spp. [52].

*Aspergillus fumigatus* is responsible for more human and animal diseases than other molds even though their conidia are usually outnumbered by spores of other mold species in inhaled air, suggesting that *Aspergillus fumigatus* has special properties that enable it to colonize the lungs of it hosts [53]. *Aspergillus* species are frequent causes of invasive fungal infections in immunocompromised patients; they are also associated with allergic Broncho pulmonary diseases, mycotic keratitis, otomycosis and nasal sinusitis [54]

Table (3-1)  
Number and percentage of specimens of immunocompromised patients with Aspergillosis

Immunocompromised state		No .positive
Cancer	Diabetes	
18 (66.66%)	9 (33.33%)	27(100%)

### Collection and identification of Aspergillus isolation

Out of 50 specimens of all study subjected only 27% yielded growth of *Aspergillus fumigatus* isolates and considered as positive specimens which were used in the phenotypic diagnosis .In briefly they were Two groups of patients were included: 30 (60%) isolates from cancer patients from eyes and 20 (40%) isolates from diabetes from ears , represented 29 (58%) from females and 21(42%) from males (table 1). *Aspergillus* were isolated and screened from 27 samples collected from cases of different diseases, and it was identified by morphological characteristics including color of the colony and growth pattern on culture media . Some of the microscopic characteristics examined under the light microscope & scanning electron microscope.

Imunocompromised patients, any fungus present in the environment may be potentially pathogenic. *Aspergillus* and *Candida* spp. are the main organisms isolated most frequently from immunocompromised patients [55] .As show in table ( 3-1)

The genus of *Aspergillus* easily identified by its characteristic conidiophore, but species identification and differentiation is complex, for it is traditionally based on a range of morphological features. Macro morphological features which are considered include conidial and mycelia color , colony diameter ,colony reverse color, production of exudates. Micromorphology characterization is mainly dependent on serration, shape and size of vesicle, conidia and stipe morphology [56,57]

Table 3- 1  
Distribution of fungi isolates according to patients

Nature of Infection	Cancer patients				Diabetes patients				Total
	Positive		Negative		positive		negative		
	Male	Female	Male	Female	Male	Female	Male	Female	
Eye	5	13	5	7	-	-	-	-	30
Ear	-	-	-	-	4	5	7	4	20
Total	18		12		9		11		50
	30				20				

### **Identification of *Aspergillus fumigatus* isolates:- including Morphological and culturing features**

All collected swabs were cultured on SDA microscopy and cultural methods remain commonly used and essential tools for identification of *Aspergillus*. The colonies of *Aspergillus fumigatus* appear in

#### **Macroscopic Appearance:**

- 1) Growth rate is rapid and the texture of colonies varies from wooly to 5day.
- 2) Surface colony color is smoky gray – green and the reverse is yellow.
- 3) Color of very mature colonies turn to slate gray while typical colonies may remain white with slight condition.

#### **Microscopic Appearance:**

- 1) Conidial heads are in the form of compact columns.
- 2) Conidiophores are smooth-walled, often tinted greenish, up to 300  $\mu\text{m}$  long, and terminate in dome – shaped vesicle with a diameter of 20-30  $\mu\text{m}$  long.
- 3) Hyphae are septate and hyaline.
- 4) The phialides are uniseriate with size ranging from 5 - 10 x 2 – 3  $\mu\text{m}$ .
- 5) Conidia are ground to sub-globes, smooth to finely roughened, and with diameter size of 2 – 3.5  $\mu\text{m}$ . [58]. As shown in Figure (3-1).



Figure (3-1) the colony of *Aspergillus fumigatus* growth on (SDA) (at 25°C for 7 days)

#### **Microscopic Features**

Microscopic characteristics for the identification were color and length of conidiophore and conidial heads, stipe, vesicles shape and serration, conidia size, shape and roughness and phialides length and breadth of *Aspergillus* [58]. Environmental surveys indicate that all humans inhale at least several under *Aspergillus fumigatus* conidia per day for most patients. Therefore, disease occurs predominantly in the lungs, although dissemination to virtually any organ occurs

in the most severely predisposed [10,11] as shown in Figure (3-2). The globes conidia that were finely rough and green in color [59].

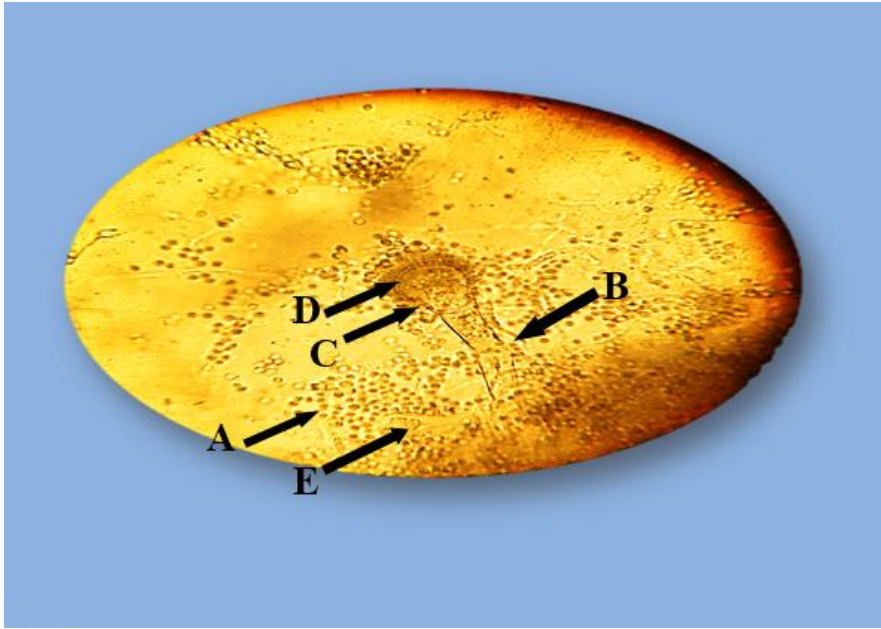
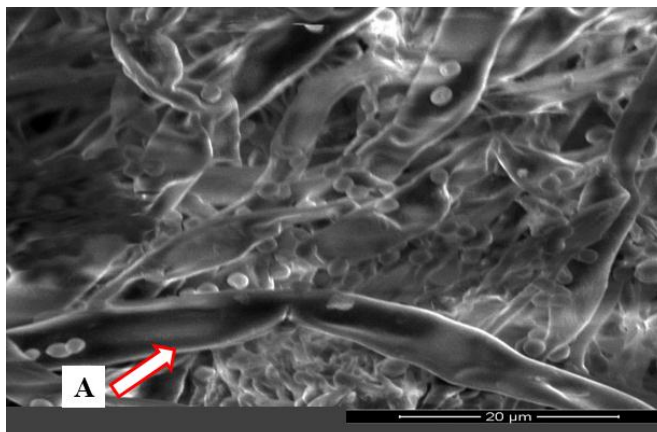


Figure (3-2) Micrographs showing light microscopic structures of *Aspergillus. Fumigatus* A- conidia B- conidiophore C- vesicle D- phialides E-hypha and all stained with lacto phenol (40x)

### Diagnosis by scanning electron microscopy

#### Morphology diagnosis of *Aspergillus fumigatus* isolates

In this study the specimens were examined using scanning electron microscope, were used to diagnosis and described morphology of *Aspergillus fumigatus*, the results was shown in Figure (3-3) .



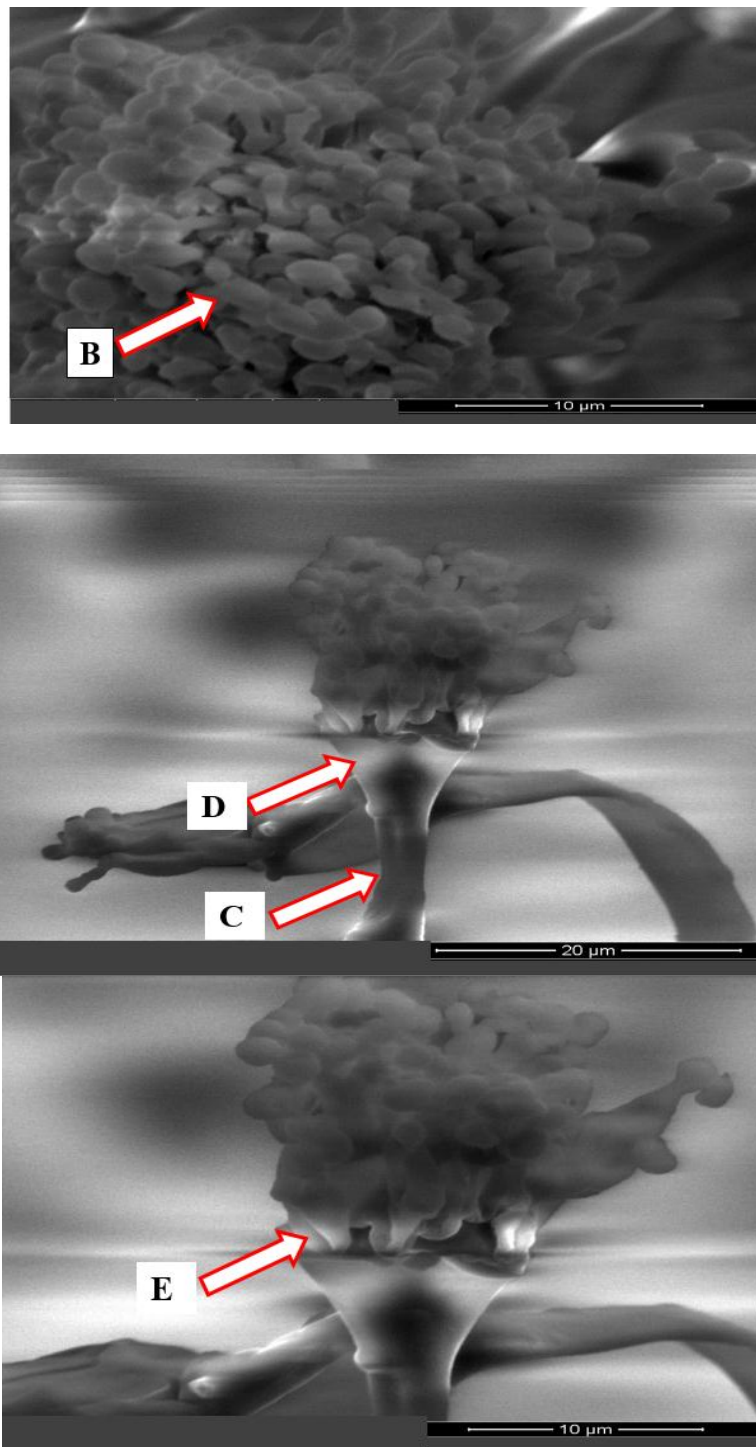


Figure (3-3) Micrographs showing scanning electron microscopic structure's of *Aspergillus fumigatus* A- hypha B- conidia C- conidiophor D-vesicle E- phialides



### Conclusions

The results showed that the incidence of aspergillosis in women was higher than the man , patients with cancer was more than diabetes patients., most common symptoms in patients with ear infection was pruritus and redness in patients with eye infection and the infection of *A. fumigatus* is most commonly in elderly patients than young patients.

### Acknowledgments

Praise be to Almighty Allah Who gave me power and motivation to finish this work.

**Conflict of interest:** The authors declare that they have no conflict of interest.

**Author contributions:** authors contributed equally to the work and having jointly supervised the work.

### References

1. Pitt, J.I., Samson, R.A., Frisvad, J.C. (2000). In: Integration of Modern Taxonomic Methods for Penicillium and Aspergillus Classification (Eds. RA Samson and JI Pitt), Hardwood Academic Publishers, Reading, UK, 9- 50
2. Haines, J. (1995). Aspergillus in compost: straw man or fatal flaw. *Biocycle* 6:32-35.
3. Pitt, J. I. (1994). The current role of Aspergillus and Penicillium in human and animal health. *J. Med. Vet. Mycol.* S1:17-32.
4. Vanden Bossche, H.;Mackenzie, D. W. R. and Cauwenbergh ,G. (1988). *Aspergillus and aspergillosis*. Plenum Press, New York, N.Y
5. Mullins, J.; Harvey,R. and Seaton,A.( 1976). Sources and incidence of airborne *Aspergillus fumigatus* (Fres). *Clin. Allergy* 6:209-217.
6. Mullins, J.; Hutcheson, P. and Slavin,R. G.( 1984). *Aspergillus fumigatus* spore concentrations in outside air: Cardiff and St. Louis compared. *Clin. Allergy* 14:251-254.
7. Nolard, N. (1994). Les liens entre les risques d'aspergillose et la contamination de l'environnement. *Revue de la litte´rature. Pathol. Biol.* 43:706-710.

8. Raper, K. B., and Fennell, D. (1965). *Aspergillus fumigatus* group, p. 238–268. In K. B. Raper and D. I. Fennell (ed.), *The genus Aspergillus*. The William & Wilkins Co., Baltimore, Md.
9. Samson, R. A., and Van Reenen-Hoekstra, E. S. (1988). *Introduction to food-borne fungi*. Centraalbureau voor Schimmelcultures, Baarn, Delft, The Netherlands.
10. Chazalet, V.; Debeaupuis, J. P. J.; Sarfati, J.; Lortholary, P.; Ribaud, P.; Shah, M.; Cornet, H. Vu.; Thien, E.; Gluckman, G.; Brückner, and Latge J. P. (1998). Molecular typing of environmental and patient isolates of *Aspergillus fumigatus* from various hospital settings. *J. Clin. Microbiol.* 36:1494–1500.
11. Goodley, J. M.; Clayton, Y. M. and Hay, R. J. (1994). Environmental sampling for aspergilli during building construction on a hospital site. *J. Hosp. Infect.* 26:27–35.
12. Hospenthal, D. R.; Kwon-Chung, K. J. and Bennett, J. E. (1998). Concentrations of airborne *Aspergillus* compared to the incidence of invasive aspergillosis: lack of correlation. *Med. Mycol.* 36:165–168.
13. Sarfati, J.; Diaquin, M.; J. P.; Paris, S. and Latge, J. P. . Unpublished data.
14. Chakraborty, p. (1995). *A text book of microbiology*, new center book agency Ltd. India.
15. Blanco, J. L. and Garcia, M. E. (2008). Immune response to fungal infections. *Vet Immunol Immunopathol.* 15: 47-70.
16. Mugliston, T. and O'Donoghue, G. (1985). "Otomycosis—a continuing problem," *Journal of Laryngology and Otology*, 99(4): 327–333.
17. Pontes, Z. B. V. D. S.; Silva, A. D. F.; Lima, E. D. O. *et al.*, "Otomycosis: a retrospective study," *Brazilian Journal of Otorhinolaryngology*, vol. 75, no.
18. Fasunla, J.; Ibekwe, T. and Onakoya, P. (2008). "Otomycosis in western Nigeria," *Mycoses.* 51 (1):67–70.
19. Pradhan, B.; Ratna Tuladhar, N. and Man Amatya, R. (2003) "Prevalence of otomycosis in outpatient department of otolaryngology in Tribhuvan University Teaching Hospital, Kathmandu, Nepal," *Annals of Otolaryngology, Rhinology and Laryngology.* 112(4): 384–387.
20. Munguia, R. and Daniel, S. J. (2008). "Otopical antifungals and otomycosis: a review," *International Journal of Pediatric Otorhinolaryngology.* 72(4): 453–459.
21. Kaur, R.; Mittal, N.; Kakkar, M.; Aggarwal, A. K. and Mathur, M. D. (2000). "Otomycosis: a clinicomycologic study," *Ear, Nose and Throat Journal*, 79 (8): 606–609.
22. Viswanatha, B.; Sumatha, D. and Vijayashree, M. S. (2012). "Otomycosis in immunocompetent and immunocompromised patients: comparative study and literature review," *Ear, Nose & Throat Journal*, 91: 114–121.
23. Stern, J. C. and Lucente, F. E. (1988). "Otomycosis," *Ear, Nose and Throat Journal.* 67 (11): 804–810.
24. Viswanatha, B. *et al.* (2012). Otomycosis in immunocompetent and immunocompromised patients; comparative study and literature review, *ENT Journal Mar*; 91(3):114-21.
25. Carney, AS. Otitis externa and otomycosis. In: Gleason MJ, Jones NS, Clarke R, et al. (eds). (2008) *Scott-Brown's Otolaryngology, Head and Neck Surgery*, vol 3, 7th edn. London: Hodder Arnold Publishers;3351-7.

26. Rama Kumar, K. (1984). Silent perforation of tympanic membrane and otomycosis. *Indian Journal of Otolaryngology and Head and Neck Surgery*.36(4):161-2.
27. Rutt, A. and Sataloff, R. T. (2008). Aspergillus otomycosis in an immunocompromised patient. *ENT J*.87(II):622-3.
28. Abad, JC.; Foster, CS. (1996). Fungal keratitis. *Int'l Ophthalmol Clin*.36: 1-15.
29. Bennett, J. (2007). Agentes antimicrobianos, agentes antifúngicos. In: Brunton L, editor. Goodman & Gilman: as bases farmacológicas da terapêutica. 11a ed. Rio de Janeiro: McGraw-Hill; c. 1103-17.
30. William R. Herguth, President, Guy Nadeau. Applications of Scanning Electron Microscopy and Energy Dispersive Spectroscopy (SEM/EDS) To Practical Tribology Problems. Senior Technical Associate Herguth Laboratories, Inc.
31. Chapin, K.C. and Murray, P. (1999). Media in: Murray, P.R.; Baron, E.J.; Tenover, F.C. and Tenover, F.C. and Tenover, F.C. and Tenover, F.C. Manual of Clinical Microbiology, 7<sup>th</sup> Edition. Philadelphia. p:1687-1707.
32. Kwon-chung, K. J. and Bennett, J. (1992). medical mycology. Lea and Febiger Philadelphia. London.
33. McGregor, J.A.; French, J.I. and Jone, W. (1992). Association of cervico vaginal infection with increased vaginal fluid phosphates activity. *Am. J. Obst Gyn*.167:1588-1594.
34. Doroghazi and Robert, M. (1981). "Invasive external otitis: report of 21 cases and review of the literature." *The American journal of medicine* 71.4 :603-614.
35. Grandis.; Jennifer Rubin ; Barton, F. ; Branstetter, IV., and Victor, L. Yu. (2004). "The changing face of malignant (necrotising) external otitis: clinical, radiological, and anatomic correlations." *The Lancet infectious diseases* 4.1 .34.
36. Latgé, J. P. (1999). *Aspergillus fumigatus* and aspergillosis. *Clin. Microbiol. Rev.* 12:310-350.
37. Gupta and Smita,. (2007). "Infections in diabetes mellitus and hyperglycemia." *Infectious disease clinics of North America*. 21:3 617-638.
38. Gallin, J. I., and Zarembek, K.. (2007). Lessons about the pathogenesis and management of aspergillosis from studies in chronic granulomatous disease. *Trans. Am. Clin. Climatol. Assoc.* 118:175-185.
39. Washburn, R.G. ; Kennedy, DW.; Begley, MG. and Bennett, JE. (1988). Chronic fungal sinusitis in apparently normal hosts. *Medicine (Baltimore)*.67: 231-247.
40. Milroy, CM.; Blanshard, J.; Slucas and Michaels, L. (1989). *J clin pathol* 142:123-127.
41. Young, RC.; Bennet, JE. And Vogel, CL. (1970). Aspergillosis: The spectrum of the disease in 98 patients *Medicine (Baltimore)*. 49: 147-173.
42. Fraser, RS. (1993). Pulmonary aspergillosis: Pathologic and pathogenic features. *Pathol Annu.* 28: 231-277.
43. Patterson and Thomas, F. (2016). "Practice guidelines for the diagnosis and management of aspergillosis: 2016 update by the Infectious Diseases Society of America." *Clinical Infectious Diseases* 63.4: e1-e60.
44. Oh, Y.W.; Effmann, E.L. and Godwin, J.D. (2000). Pulmonary infections in immunocompromised hosts: the importance of correlating the conventional radiologic appearance with the clinical setting. *Radiology*.217: 647-56.

45. Vento, S. and Cainelli, F. (2003). Infections in patients with cancer undergoing chemotherapy: aetiology, prevention, and treatment .Lancet. Oncol. 4: 595-604.
46. Lopez, S.; J.B.; Coto, C.D. and Fernandez, C.B. (2002). Neonatal sepsis of nosocomial origin: an epidemiological study from the Grupo de Hospitales Castrillo. J. Perinat. Med.30: 149-157.
47. Jadhav, VJ.;Pai, M. and Mishra, GS. (2003).Etiological significance of *Candida albicans* in otitis externa. Mycopathologica.156:313–315.
48. Rutt, AL and Sataloff, RT. (2008). *Aspergillus* otomycosis in an immunocompromised patient. Ear Nose Throat journal. 87(11):622–623.
49. Thrasher, RD. and Kingdom ,TT. (2003).Fungal infections of the head and neck: an update. Otolaryngol Cli N Am.36:577–594.
50. Yassin, A. Maher, A. and Mowad, MK. (1978).Otomycosis: A survey in the eastern province of Saudi Arabia. Journal of laryngology and otology. 92:869–876.
51. Jia, X.; Liang ,Q.; Chi, F. and Cao ,W. (2012). "Otomycosis in Shanghai: aetiology, clinical features and therapy " Mycoses, 55: 404–409.
52. Pontes, Z. B. V. D. S. ; Silva, A. D. F ; Lima ,E. D. O and *et al.*(2009). "Otomycosis: a retrospective study," Brazilian Journal of Otorhinolaryngology, 75(3): 367–370.
53. Pradhan, B. ; Ratna Tuladhar ,N. and Man Amatya ,R.(2003)."Prevalence of otomycosis in outpatient department of otolaryngology in Tribhuvan University Teaching Hospital, Kathmandu, Nepal," Annals of Otolaryngology, Rhinology and Laryngology, 112(4) :384–387.
54. Munguia ,R. and Daniel ,S. J.( 2008) ."Ototopical antifungals and otomycosis: a review," International Journal of Pediatric Otorhinolaryngology, 72(4) :453–459.
55. Pfaller, MA. and Diekema, DJ. (2004). Rare and emerging opportunistic fungal pathogens: concern for resistance beyond *Candida albicans* and *Aspergillus fumigatus*. J Clin Microbiol. 42:4419–31.
56. Klich, M.A. (2002). Identification of common *Aspergillus* species, CBS, Netherlands.
57. Rodrigues, P.;Soares, C.; Kozakiewicz1, Z.; Paterson, R.R.M.; Lima, N. and Venâncio, A. (2007). Identification and characterization of *Aspergillus flavus* and aflatoxins. Communicating Current Research and Educational Topics and Trends in Applied Microbiology (A. Méndez\_-Vilas (Ed.): 527-534.
58. Diba, K.; Kordbacheh, P.; Mirhendi ,S.H.; Rezaie, S. and Mahmoudi,M. (2007). Identification of *Aspergillus* species using morphological characters. Pak. J. Med. Sci., 23: 867-872. Rev. 12:310–350.
59. Johnson, EM. and Borman, AM.(2010). The importance of conventional methods: microscopy and culture. In: Pascualotto A, editor. *Aspergeukaryotic Cellilolysis: from diagnosis to prevention*. New York: Springer: 55–73.