

How to Cite:

Alenazi, A. (2022). Migration of dental implant towards maxillary sinus: Case reports and an overview. *International Journal of Health Sciences*, 6(S3), 3419–3430.
<https://doi.org/10.53730/ijhs.v6nS3.6488>

Migration of dental implant towards maxillary sinus: Case reports and an overview

Adel Alenazi

Department of Maxillofacial Surgery and Diagnostic Sciences, College of Dentistry, Prince Sattam Bin Abdulaziz University, P.O.Box: 173, Al-Kharj 11942, Saudi Arabia. Telephone: 00966-11-5886226
Email: a.alenazi@psau.edu.sa

Abstract---Placing a dental implant in the maxillary posterior region is a challenge to a dentist because of its proximity to the maxillary sinus and decreased height of bone in this region. The surgical approaches for instilling a dental implant are thus associated with complications, of which migration of the implant into pneumatized sinus can also occur. Though this type of displacement is an accidental occurrence and can occur either intra-operatively or post-operatively, but a dentist should be adequately prepared if such a situation arises. These two (02) case reports and an overview will focus on the migration of dental implants toward the maxillary sinus with its probable causes, clinical findings, diagnosis, associated complications, and management.

Keywords---dental implant, maxillary sinus, migration.

Introduction

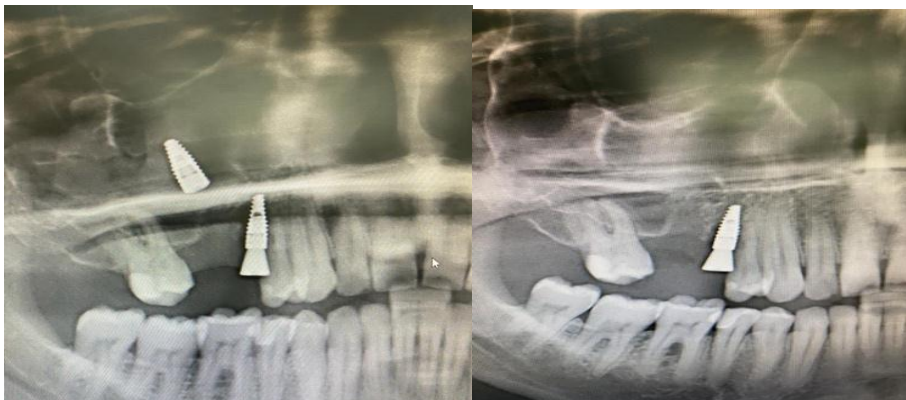
The quality of a life of a patient has been greatly enhanced by the introduction of dental implants as they impart a great functional improvement and aesthetics, especially in an edentulous patient. It has emerged as a successful treatment modality with a huge impact on the overall life of dental patients. ⁽¹⁾ Though it is a highly successful treatment option, it has its own risks and complications associated with it. Dental implants are placed in both jaws but putting a dental implant in the maxilla can be more overwhelming owing to the more chances of complications occurring and being a challenging site of surgery for oral surgeons. ⁽²⁾ Because of the peculiar location of the maxillary sinus, any surgical procedure or prosthesis placed in the maxillary posterior region can get complicated by displacement into the maxillary sinus. Any root fragment, a complete tooth, a dental surgical instrument, and even a dental implant in the maxillary posterior area can get displaced into the maxillary sinus. This could happen mainly due to improper surgical procedure, deficient bone in the region, sinus

pneumatization, any previous sinus pathology causing weakening of the crystal bone, or movements caused by the patient during the procedure. ⁽³⁾

Implants can get destabilized in this region chiefly because of the reduced density of bone and accelerated resorption of bone. The process of healing may also be accompanied by the loss of bone at the margins, which can push the dental implant accidentally into the maxillary sinus. ⁽⁴⁾ Another reason could be placing a dental implant in this region by approaching through crest into the inferior quality of remaining bone. ⁽³⁾ It has also been observed that an inadequate or wrong planning with insufficient experience of implant surgery in the posterior maxilla can lead to implant migration. ^(5,6) An alternative method of employing dental implants of short size with their placement by approaching through elevation of sinus floor has also been reported as a successful method. ^(7,8) When an implant or any foreign material lands onto the maxillary sinus, it can cause many problems. A migrated implant can lead to infection of the sinus which may be presenting with dentalaltral fistula formation. The infection may also spread to involve adjacent paranasal sinuses.⁽⁹⁾ Not only the dental and medical complications that can arise due to such displacements are problematic but it also brings loss of patient's trust in the dentist. ⁽³⁾ Thus, these migrated implants should be taken out as quickly as possible after diagnosis to avoid further serious problems.

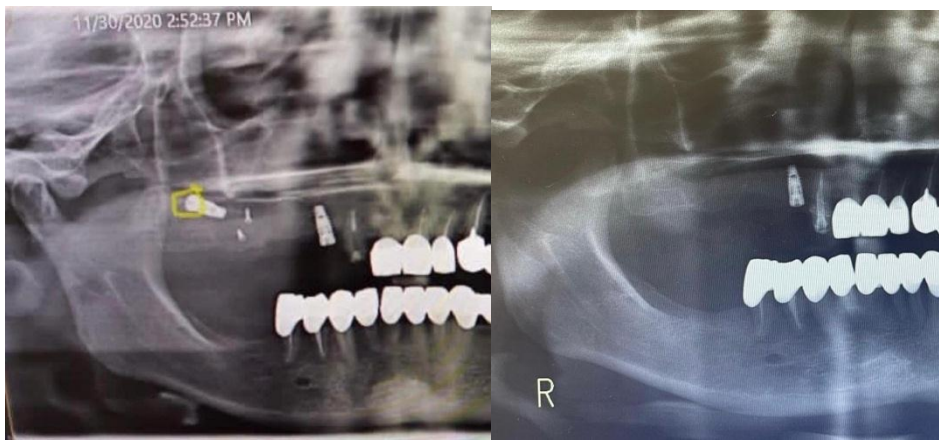
Case 1

A 41-year-old male patient who is medically fit was referred from the prosthodontist to an oral surgery clinic for removal of the displaced implant toward the maxillary sinus. The implants' position was planned digitally by the prosthodontist depending on the Cone Beam Computed Tomography (CBCT). A fully guided implant placement protocol was used to place the implants. After three months from the placement of the implants, the patient presented for the second stage. During the removal of the covering screw before the insertion of the healing abutment, the implant displaced and migrated toward the maxillary sinus. When we received the patient orthopantomography (OPG) and CBCT were done to determine the position of the implant inside the maxillary sinus. Then, the Caldwell-Luc approach was used to remove the implant.



Case 2

65-year-old female patient who is medically fit. She presented to the oral surgery clinic 1 month after sinus lift, implants placement, and bone graft that had been done in a private dental clinic. She was complaining of sinusitis-like symptoms. When we examined the patient and took the required radiographs, we found a floating implant inside the maxillary sinus. We determined the position of the implant inside the maxillary sinus. Then, the Caldwell-Luc approach was used to remove the implant from the maxillary sinus.



Discussion

Knowing the probable causes, complications and the ways to manage a dental implant migration can help in achieving higher implant success and dentist patient trust factor. However, many case reports highlighting such incidences have been published in the literature, but a review of all the aspects of dental implant migration is still lacking. So this overview has been written with an aim to provide insight into the entirety of the migration of dental implants into the maxillary sinus. In-depth knowledge and pre-planning implant surgeries in the maxillary posterior region can help dentists' especially oral surgeons in evading such situations arising in clinical scenarios.

Causes of dental implant migration into the maxillary sinus

Implantation is a successful procedure but can be associated with problems with a reported incidence of complications arising being 5% to 10%.⁽¹⁰⁾ Bouquet et al. reported that iatrogenic substances which get incorporated into the maxillary sinus account for 0.6 - 3.8% of all the material that lands in the sinus.⁽¹¹⁾ Anatomy of the maxillary sinus is the predominant factor that leads to implant displacement during or after its placement. This space lies in close proximity to the maxillary posterior region of the oral cavity and thus any surgical procedure or manipulation required in this area can easily lead to the movement of materials and foreign objects into this cavity. The density of the bone in this region is also low which coupled with a higher rate of resorption of alveolar ridge

bone in this area increases the chances of migration of any root fragment, weakened tooth due to dental caries, or a dental implant into the maxillary sinus.⁽⁴⁾

Insufficient height of bone has been reported as one of the chief reasons for implant migration into the sinus and is thus not indicated for placing implants. The type of bone mainly associated with implant displacement is the Type IV bone of the alveolar region.⁽¹²⁾ Pneumatization of the maxillary sinus could be other factor leading to easy displacement of the dental implant into sinus by causing poor quality of bone and by limiting the available bone for placing dental implant.^(9,13) All these factors in turn can lead to poor stability of dental implant and thus easy perforation of sinus floor.⁽⁴⁾ Lack of enough knowledge of anatomy of maxillary sinus, adequate pre planning of surgery, low prior surgical experience in this area, breaking of Schneiderian membrane, use of extensive pressure or excessive forces during surgery, manipulation of the area in a way leading to formation of oro antral communication during base creation for implant placement are the factors which can lead to cases where dental implants can migrate without any previous graft surgeries.⁽⁶⁾ Contributing causes to the late displacement of implants into the sinus can be any alterations in pressure in the maxillary sinus and nasal cavity, auto-immune conditions causing damage to the bone around placed implants, and decreased occlusal forces below optimum.⁽¹²⁾

Clinical findings in a migrated dental implant into the maxillary sinus

Displaced implants may remain as such in the sinus without causing any clinical signs or symptoms, or may move to adjacent paranasal sinuses, ethmoidal, sphenoidal, and frontal sinuses.⁽¹⁴⁾ Literature has also revealed that displaced implant could come out of the sinus by itself or can cause more serious complications like obstruction of air pathway.⁽¹⁵⁾ If the implant is not expelled off and persists in the maxillary sinus, it may cause inflammation of the mucosal lining of the sinus leading to sinusitis, or may not cause any related signs. Potential complications that can occur in association with the presence of a foreign object can also happen with a dental implant lying as an intruder into the sinus and these may include general discomfort caused by its presence, parenthesis owing to its nearby association with nerve, leading to pain, cellulitis, sinus inflammation and formation of an abscess.^(16, 17)

Even in an asymptomatic patient, displaced implant eventually can cause maxillary sinusitis by impaired ciliary beating of cilia on sinus epithelium and physically obstructing the nasal opening.⁽³⁾ Further complications can arise if an implant has caused sinusitis. If not removed or treated, this implant in the sinus can lead to sinister situations like moving into deep spaces of the head and face region, leading to severe infection of the sinus and adjacent crucial structures, widespread necrosis of tissues, and allergic reaction manifestation by the sinus mucosa and other linings in the region to this foreign body.⁽⁴⁾ Furthermore it may cause insomnia due to associated psychological stress and can create a fear of future dental treatment in these patients. A case has also been reported where migration has led to a negative impact on the patient leading to a loss of the patient's trust in the doctor, which in turn resulted, in a dispute.⁽³⁾

Diagnosis and management

In a symptomatic patient, dentist should be suspicious of dental implant lying in maxillary sinus if patient presents with symptoms of sinus obstruction, sinusitis, pain, discomfort, adverse reaction post-operatively, or any of the associated clinical signs. On the other hand, in the case of asymptomatic patients, the clinical absence of a dental implant from its placed position should alarm the physician. As dental implants placed in the maxillary posterior region have quite a good chance to migrate into the maxillary sinus due to the abovementioned factors, a dentist should immediately take a radiograph to confirm the displacement. The primary mode of diagnosis relies on computed tomography in three-dimensional analysis. Other radiographic interpretations of Orthopantomogram and cephalogram from both frontal and lateral views can also be helpful in identifying the migrated dental implant.⁽¹⁸⁾ Sinusitis associated with a displaced implant into the maxillary sinus and other paranasal sinuses can also be disclosed on 3D Computed tomography. ⁽³⁾

Treatment strategies can be different based on implant migration intraoperatively or post-operatively. Using sufficient suction and water pressure under irrigation with saline and hemostasis, a displaced implant should be tried to be taken out if it has occurred during implant placement surgery. Manual detachment of the implant from the sinus epithelial lining can also be attempted. Without adequate access and view of the displaced implant, an attempt to retrieve it should not be made as it can lead to the pushing of the implant into the underlying tissues. ⁽¹⁷⁾ If it has occurred post-operatively, a patient should be assessed for clinical signs and symptoms. As all the patients do not present with symptoms, so to remove the implant or keep it like that in asymptomatic cases is still an area of discussion amongst surgeons and researchers. Asymptomatic patients can be kept under observation with a coverage of antibiotics and drugs to control inflammation. ⁽³⁾

There is an opinion that displaced implant should be removed in all cases whether symptoms are present or not as if not removed, it can cause ample psychic stress and further complications in later date.^(19,20) Another reason is that any foreign object lying close to a structure such as maxillary sinus with specific anatomy has a tendency to move to other areas through the movement of cilia which may necessitate consistent radiography or computed tomography for constant monitoring. Prompt surgery should be carried out as early as possible if the patient develops the symptoms of an implant in the maxillary sinus. Thus patients can be further reported to related departments like oral surgery or ENT where these displaced implants after confirmed diagnosis can be removed immediately to avoid further complications. ⁽³⁾

As implant may be present in a location away from sinus due to further displacement from its originally migrated site, surgeons should carefully look for dental implants in other positions on a radiograph. If failure to retrieve the dental implant occurs, the area should be sufficiently irrigated and a sterile gauze may be placed over the wound. Further course can be monitored through periodic assessment using regular radiographs or CT scans with keeping the patient on

antibiotics, anti-inflammatory drugs, and analgesics to relieve discomfort. Instructions should be given to the patient to prevent from doing coughing or sneezing severely and anything, which can cause movement of the implant and further problems. ⁽²¹⁻²⁴⁾ Clinical features, presentation, and management of recently reported cases of dental implants migrating towards maxillary sinus are listed in Table 1.

Table 1
Clinical features, presentation and management details of recently reported cases of dental implant displacement towards maxillary sinus.

S. No	Author Name, Year	Number of case/s	Age	Gender	History	Clinical Presentation	Treatment
1	Lourdes Ridauro Ruiz et al, Year - 2009, 21	9	Mean age -56.7	6- male, 3 Female	Displaced implants were observed into maxillary sinus, In most cases accidental displacement occur prior to prosthetic loading, except in 2 cases where it was seen after 4 month	3 patients displayed clinical symptoms like sinusitis others were asymptomatic	Most patient were subjected to surgical treatment
2	Pietro Fusari, Matteo Doto and Matteo Chiaoasco Year - 2013, 9	1	47 year	Male	Dental implant displaced	Pain and Sinusitis	Patient was treated under local anaesthesia and antibiotic course
3	Ibrahim Damiar Year- 2015, 18	1	53 year	Male	Patient had underwent a surgical procedure were eight dental implants were inserted to rehab fully edentulous	No sign and symptoms in patients was detected, Displaced dental implat which had migrated into left maxillary sinus	u n d e r surgery with Caldwell-Luc

					maxilla .		
4	Xiaojun Ding , Qing Wang , Xuehua Guo , Youcheng Yu Year-2015, 22	1	65year	Female	Edentulous patient had undergone implant placement	Root of implant penetrated the maxillary sinus , graft was failed	Oroantral fistula was sealed with mucoperiost eal flap ,Cadwel l Luc surgical procedure under local anesthesia
5	Abubekir Eltas , et al, Year - 2015, 13	1	64 year	Female	Previously diagnosed with slippage of implant into maxillary sinus	Implant was found in oblique position on lateral wall of right maxillary sinus , was seen on thickened mucosa of inferior of maxilla	Treated under intraorally administered local anesthesia by using lateral window surgical technique.

6	So-Hyun Kim , Young-Kyun Kim Year-2017, 3	1 9 Patient s were to reviewed	Ranged from 21 to 27 years ,	1 3 - male af n d 6- fee	16 cases were o i m p l a n t a n d n a s a l displacement , 3 were oft o o t h displacement , ut of 16 ca ses 11 cases were asymptomatic p l u r a l , 8 displayed symptoms	Psychological and n a s a l obstruction were the most common sign and symptoms followed by nasal discharge pain and 1For removal discharge.	Removal of di s placed ma terial were made in 14 patients and 5 were e observed u s i n g antibiotics . For removal majority of cases went u nder surgery with Caldwell- L u c approach u n d e r general anesthesia , A ll o f symptoms disappeared a f t e r removal of d i s p l a c e d material .
---	---	---	---------------------------------------	-----------------------------------	---	---	--

7	Mauro Laureti ,etal. 1 Year- 2017, 2	1	61year	Female	H a d under gone surgery for implant	Sinisitus and presence of foreign body n t o r i g h t maxillary sinus	Implant was removed by Caldwell- L u c procedure under local anaesthesia with later windo wa ccess o f maxillary i n u s a n d antibiotic therapy.
8	Emrah Soylu ,1 Erdem Kilic and Alper Alkan Year – 2018, 23	1	52year	male	D e n t a l i m p l a n t s h a d d e n t a l m i g r a t e d t o s t a y i n g m a x i l l a r y s i n u s	C B C T h o w e d a l a s a l o s t i u m d i m p l a n t w a s f a i l e d , u n d e r o r b i t a l f l o o r i a n d l a t e r a l s i d e o f n a s a l c o n c h a	E n d o s c o p y a p p r o a c h b y N a l a s a l o s t i u m w a s f a i l e d , C a l d w e l l - L u c o p e r a t o n w a s p e r f o r m e d

9	<p>Jorge Toledano-Serrabona, Jordi Cascos-Romero, Carlos Moya Escoda Year - 2020, 24</p>	<p>9 patients were taken</p>	<p>Mean age of 36 years</p>	<p>3 Female, 6 Male</p>	<p>4 patients had upper wisdom teeth displaced into maxillary sinus, 5 patients were palatal roots of 1st and 2nd molar were displaced.</p>	<p>Accidental displacement of teeth toward adjacent anatomical space (maxillary sinus, submandibular space) In 5 patients displaced teeth remained asymptomatic however dental fragments were retrieved, 4 patients showed a maxillary sinusitis</p>	<p>Initially Alveolar ridge was closed, Antibiotic was given to treat infection, teeth were removed by transnasal endoscopy under local anesthesia</p>
---	--	------------------------------	-----------------------------	-------------------------	---	--	--

Conclusion

A favorable outcome has usually been observed in cases treated for dental implant migration into maxillary sinus which prevented any further serious complications. Though such a thing can happen, an adequate knowledge of maxillary posterior region and sinus area, a well-planned surgery before implant placement, sufficient analysis of the residual bone in the region through clinical and radiographic assessment and choosing the right surgical approach whether crystal or lateral approach for dental implant placement accordingly can help dentists and surgeons avoid such situations in clinical settings. A sufficient healing period after dental implant placement can further enhance the success of implant placement in the maxillary posterior region.

Acknowledgement

The author would like to thank the Deanship of Scientific Research, Prince Sattam Bin Abdulaziz University, Al-Kharj, Saudi Arabia for their financial support for this study.

References

1. N. Ferrigno, M. Laureti, S. Fanali, and G. Grippaudo, "A longterm follow-up study of non- submerged ITI implants in the treatment of totally edentulous jaws. Part 1: ten-year life table analysis of a prospective multicenter study with 1286 implants," *Clinical Oral Implants Research*, vol. 13, no. 3, pp. 260–273, 2002.
2. Mauro Laureti, Nicola Ferrigno, Daniele Rosella, Piero Papi, Francesca Mencio, Francesca De Angelis, Giorgio Pompa, and Stefano Di Carlo. Unusual Case of Osseointegrated Dental Implant Migration into Maxillary Sinus Removed 12 Years after Insertion. *Case Reports in Dentistry Volume 2017*, Article ID 9634672, 6 pages.
3. So-Hyun Kim¹ and Young-Kyun Kim^{1,2*} Clinical progress of teeth and implant displaced into the maxillary sinus: retrospective clinical study: retrospective clinical study. *Oral Biology Research*, 2017; December 31, 41(4):207-214
4. Gonzalez-Garca A, Gonzalez-Garca J, Diniz-Freitas M, Garca-Garca A, Bulln P. Accidental displacement and migration of endosseous implants into adjacent craniofacial structures: a review and update. *Med Oral Patol Oral Cir Bucal* 2012;17:769-774. doi: 10.4317/medoral.18032.
5. G.M. Raghoobar and A. Vissink, "Treatment for an endosseous implant migrated into the maxillary sinus not causing maxillary sinusitis: case report," *International Journal of Oral and Maxillofacial Implants*, vol. 18, no. 5, pp. 745–749, 2003.
6. P. Galindo, E. Sanchez-Fernandez, G. Avila, A. Cutando, and J. E. Fernandez, "Migration of implants into the maxillary sinus: two clinical cases," *International Journal of Oral and Maxillofacial Implants*, vol. 20, no. 2, pp. 291–295, 2005.
7. M. L. Arlin, "Short dental implants as a treatment option: results from an observational study in a single private practice," *International Journal of Oral and Maxillofacial Implants*, vol. 21, no. 5, pp. 769–776, 2006.
8. S. Taschieri, S. Corbella, R. Molinari, M. Saita, and M. Del Fabbro, "Short implants in maxillary and mandibular rehabilitations: interim results (6 to 42 months) of a prospective study," *Journal of Oral Implantology*, 2013.
9. Pietro Fusari, Matteo Doto, and Matteo Chiapasco. Removal of a Dental Implant Displaced into the Maxillary Sinus by Means of the Bone Lid Technique. *Case Reports in Dentistry Volume 2013*, Article ID 260707, 5 pages
10. Deas D, Micotowicz J, Mackey S, Moritz A. Implant failure with spontaneous rapid exfoliation: case report. *Implant Dent* 2002; 11:235–242.
11. Bouquet A, Coudert JL, Bourgeois D, Mazoyer JF, Bossard D. Contributions of reformatted computed tomography and panoramic radiography in the localization of third molars relative to the maxillary sinus. *Oral Surg Oral Med Oral Pathol Oral Radiol Endod* 2004;98:342-347. doi:

- 10.1016/j.tripleo.2004.02.082.
12. Guler N, Delilbasi C. Ectopic dental implants in the maxillary sinus. *Quintessence Int.* 2007;38:238–239.
 13. Abubekir Eltas, DDS, PhD1 Serkan Dundar, DDS, PhD2* Seydanur Dengizek Eltas, DDS, PhD1 Oguzhan Altun, DDS, PhD3 Umit Yolcu, DDS, PhD4 Arif Saybak, DDS, PhD. Accidental Displacement of Dental Implants Into Both Maxillary Sinuses During Surgery. *Journal of Oral Implantology.* Vol. XLI/No. Five/2015
 14. Haben CM, Balys R and Frenkiel S. Dental implant migration into the ethmoid sinus. *J Oto- laryngol* 2003; 32: 342-344.
 15. Pagella F, Emanuelli E and Castelnuovo P. Endoscopic extraction of a metal foreign body from the maxillary sinus. *Laryngoscope* 1999; 109: 339-342.
 16. Gao QM, Yang C, Zheng LY, Hu YK. Removal of Long- Term Broken Roots Displaced Into the Maxillary Sinus by Endoscopic Assistant. *J Craniofac Surg* 2016;27:77-80. doi: 10.1097/SCS.0000000000002235.
 17. Kim YK, Lee YJ, Yoon PY, Choi YH, Kim SG. Complication Q&A in dentistry. Seoul: DaehanNarae Publish. 2015. P. 29-30.
 18. İbrahim Damlar. Disappearance of a dental implant after migration into the maxillary sinus: an unusual case. *J Korean Assoc Oral Maxillofac Surg* 2015;41:278-280.
 19. Matti E, Emanuelli E, Pusateri A, Muniz CC, Pagella F. Transnasal Endoscopic Removal of Dental Implants from the Maxillary Sinus. *Int J Oral Maxillofac Implants* 2013;28:905-910. doi: 10.11607/jomi.2894.
 20. Chiapasco M, Felisati G, Maccari A, Borloni R, Gatti F, Di Leo F. The management of complications following displacement of oral implants in the paranasal sinuses: a multicenter clinical report and proposed treatment protocols. *Int J Oral Maxillofac Surg* 2009;38:1273-1278.
 21. Ridaura-Ruiz L, Figueiredo R, Guinot-Moya R, Piñera-Penalva M, Sanchez-Garcés MA, Valmaseda-Castellón E, Gay-Escoda C. Accidental displacement of dental implants into the maxillary sinus: a report of nine cases. *Clin Implant Dent Relat Res.* 2009 Oct;11 Suppl 1:e38-45. doi: 10.1111/j.1708-8208.2009.00175.x. Epub 2009 Apr 23.
 22. Xiaojun Ding, Qing Wang, Xuehua Guo, Youcheng Yu. Displacement of a dental implant into the maxillary sinus after internal sinus floor elevation: report of a case and review of literature. *Int J Clin Exp Med* 2015;8(4):4826-4836.
 23. Emrah Soylu1*, Erdem Kilic2 and Alper Alkan. Migration of a Dental Implant to the Maxillary Sinus Prior to Second Stage Surgery: A Case Report. *J Odontol* 2018, 2:1
 24. Jorge Toledano-Serrabona 1, Jordi Cascos-Romero 2, Cosme Gay-Escoda. Accidental dental displacement into the maxillary sinus during extraction maneuvers: a case series. *Med Oral Patol Oral Cir Bucal.* 2021 Jan 1; 26 (1):e102-7.