

How to Cite:

Singh, J., Kaur, E., Dhiman, S., Kaur, J., Tripathi, H., Sood, A., & Rohatgi, S. (2022). Eye Optics: A Unique Blink in Forensic Identification. *International Journal of Health Sciences*, 6(S3), 4188–4200. <https://doi.org/10.53730/ijhs.v6nS3.6763>

Eye Optics: A Unique Blink in Forensic Identification

Jaskaran Singh

Associate Professor, Department of Forensic Sciences, Chandigarh University, Gharuan, Mohali, Punjab

Email: jaskaransingh630@gmail.com

Ekampreet Kaur

Intern, Regional Testing Forensic Science Laboratory, Toxicology division, Ludhiana, India

Samar Dhiman

Intern, Regional Testing Forensic Science Laboratory, Toxicology division, Ludhiana, India

Jasmeet Kaur

Intern, Regional Testing Forensic Science Laboratory, Toxicology division, Ludhiana, India

Himanshu Tripathi

Additional Director, University Institute of Applied Health Sciences, Chandigarh University, Gharuan, Mohali, Punjab

Abhinav Sood

Senior Research Scholar, Department of Anthropology, Panjab University, Chandigarh, India

Shipra Rohatgi

Faculty, Amity Institute of Forensic Sciences, Amity University, Noida, India

Abstract---Eye is the vital organ of the body and has been an area of interest in forensic scenario, eye can also act as a valuable forensic evidence as it can primarily aid in the postmortem interval estimation, therefore assists in identifying time since death. Moreover, the secretion from eye that is tears and eye wears also play major role in crime investigation. This review has aimed to highlight the scope and breadth of research into the field of forensic ophthalmology. We have discussed the current aspects which are existing in this discipline and also the imperative avenues for future perspectives.

Keywords--forensic ophthalmology, postmortem interval, forensic pathology, biometrics, endoscopy, postmortem eye changes, tears, eyewear.

Introduction

Eye is most consequential sense organ of the body which not only acts as a source of vision but also aids in medico legal purposes. Plenty of work has been done in past, still a vast treasure of knowledge is yet reclining. Human eye is however an imperative tool for medico legal aspects both in ante mortem and post mortem cases.[1]. In the criminal cases, when the investigation is related to glasses and other eyewear, the techniques employed for the same is forensic optometry. The most valuable technique in forensic optometry is the iris identification [2]. Beyond playing a primitive role in life, the eyes also assist in the investigation in the field of forensic pathology [3]. The branch of forensic pathology basically focuses on the examination of the dead body in order to determine the cause as well as manner of death, thus aid in the legal systems. Forensic pathology in association with forensic ophthalmology are seeking keen interest and are main focus of research. [3]. The field of forensic ophthalmology is not restricted to the use of iris in the identification, but other parts of eye also play vital role in forensics. Retina not only provides useful information in life, but it also assists in the examination of post mortem to establish the cause and manner of death. Along with this, it provides clues related to the natural diseases [4].

Eye morphology

The visible characteristics in the individuals such as eye color, skin color which are consequently being expressed as distinct phenotypes are investigated by employing the single nucleotide polymorphism which are located in DNA coding or regulatory coding that cause amino acid substitution modifying the functional characteristics of the translated proteins. The more advanced technologies such as Forensic DNA pheno-typing utilizing SNP aids in providing useful information about the bio-geographical ancestry and externally visible characteristics that lead to the elevation in the accuracy of the information in context with anonymous body and crime scene evidences as the information gathered from STRs become inefficient when it does not match with any criminal profile in the databases because of uniquely comparative nature of examination that require a pair of unknown/reference for the examination. There are instances in the forensic casework in which such a pairs are not available, then the only possibility would be searching a DNA database containing suspects' profiles. There are circumstances that if the DNA evidence can found to be in degraded conditions, the information gathered is not feasible. [5,6]

Genome wise association studies that focus on locating the genes that composite the human traits such as eye color, hair and skin color and other pigment related traits revealed that prediction of the individual's appearance is ameliorated by the information gathered by such studies. These type of studies turn out to be a valuable tool that is very functional in identification of individuals in mass

disasters. [6,7]. Eye color is highly polygenic trait and depends on the presence of the melanin therefore, it shows great color variability shifting from dark shades of brown and black to light blue, through intermediate colors such as grey, hazel, yellow, green and infrequently red and violet. [5,8] The number of melanosomes in the outer layer and the amount of melanin differentiate the patterns of the color in Iris. For example, the number of layers of melanosomes in brown eyes is less than blue eyes. The anterior layers and stroma in an eye hold the melanin and melanocytes in the cytoplasm. The observed eye color is determined by the quantity and quality of melanin in the cytoplasm. [5,8] The various experimental studies unveiled that gene-gene interaction of the HERC2, OCA2, TYR1 is responsible for the eye colors [8]. It has been manifested that the alleles for the brown color have been found to be dominating over blue and green and green leads to blue. The eye appears brown because it holds more melanin and absorbs more visible light and reflects less and as the number of the melanosomes decrease, the eye color becomes lighter and the reflection of visible light is more and absorbance is less. [8]

Irisplex system is one of the first validated developed pheno-typing based tools that utilize six SNPs distributed among the different pigmentation genes, which is successfully able to differentiate brown and blue eyes with more than 90% accuracy. The estimation probability for the blue, brown, green and hazel is basically based on multinomial logistic regression. The iris plex system turns out to be a very significant implement in case of degraded DNA samples as the examination is based on the SNPs. [5-7]. But on the contrary not only this system but other models developed by Hart and Allwood, failed to distinguish between the intermediate colors like hazel, yellow and was not able to differentiate between brown, green and not brown, green eye colors. [5-7]

Shape of eye

In the biometric community the soft biometric modalities which embrace the facial attributes are studied to identify an individual on the basis of morphological analogy of the facial characteristics like eye regions mainly the periocular regions, the peripheral area of an eye that possibly encompasses the eyebrows and eyeball. Traditionally the DNA and Fingerprint's great discriminating power have been exploited very efficiently in much forensic casework for linking the suspect as the origin of the trace and for eliminations of the suspects at the crime scene.

There can be instances where electronic evidences such as CCTV footage and video tapes are the only trace material in the form of evidences at that point DNA and Fingerprints cannot act as a bridge in the preliminary identification of the suspect. In the above mentioned scenario, the soft biometrics like periocular eye region modalities offer great discrimination powers and turn out to be a paramount tool when the aspect of the facial reconstruction is emphasized. Retrospective studies stressed on the fact the eye lid opening, eye shape, caruncle, lashes texture and inter eye distance proffer high accuracy in the identification. The facial identification scientific working group [FISWG] that works soft biometric modalities suggested that list of extensive eye features that can be used for human identification and how the features can be estimated by using the landmarks. [Table1, Figure 1, Table2]

Table 1
Represents the various eye characteristics given by FISWG

Eye characteristic	Descriptive component.
Inter-eye distance	✓ Distance R/L eye
R/L Upper Eyelid	✓ Superior palperal fold ✓ Epicanthic fold ✓ Lashes ✓ Folds
R/L Lower Eyelid	✓ Inferior palperal fold ✓ Infraorbital furrow ✓ Lashes ✓ Folds
R/L Iris	✓ Shape ✓ Shape pupil ✓ Pupil pos., diameter ✓ Position, diameter ✓ Color
R/L Medial canthus	✓ Shape caruncle ✓ Angle inner eye
R/L Lateral canthus	✓ Angle outer eye
R/L Sclera	✓ Blood ✓ color ✓ Defects

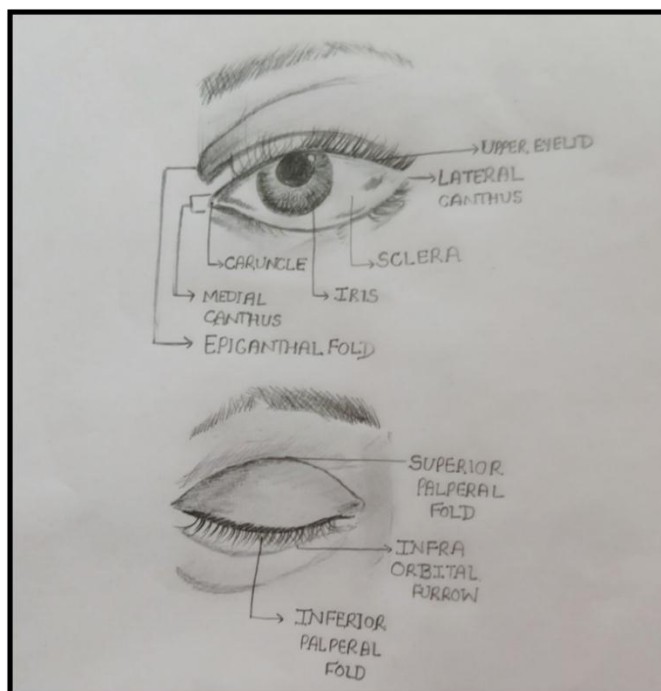


Figure 1. Eye features that can be used for human identification

Table 2
Represents the estimation of eye characteristics by using the landmarks

Estimation of eye characteristics	
Angle of eye	By medial and lateral canthi positions
Inter eye distance	between the right and left medial canthus in
Iris color	Average of the pixels <ul style="list-style-type: none"> • in the fissure opening • in the estimated iris • outside the estimated pupil
Sclera color	Average of the pixels <ul style="list-style-type: none"> • Outside the estimated iris • Fissure opening • Outside the caruncle
Inner angle	<ul style="list-style-type: none"> • Partitioned of fissure shape into Two sets that lie above and below the line segment between the medial and lateral canthus.

Eye: A commendable PMI tool

After the death, there are physical and chemical changes that occur inside the eye and these changes can be measured over time. The postmortem analysis of the eye has the ability to become a crucial benefactor for estimation of postmortem interval. Eye is the only organ of the body that undergoes gradual changes. As compared to the other body organs, PMI of eye is less affected by pathological or environmental factors. The physical changes in eye after death represent the pattern that can direct the investigation to new manner of estimation of PMI. Forensic research generally focuses on the development of methodology that is based on factors that can be examined prior to autopsy, especially during the examination of the crime scene and preliminary inspection of the carcass. One of the major catchy anatomic area is the eye, the availableness of uncomplication to notice ocular parameter that are worthy for the estimation of time since death would permit the utilization of an accessible are for barely invasive operations. The various components of eye allow variety of ways for assessment of the process and time since death estimation. There are numerous investigative elements such as dilation of iris and pupil, clouding of lens, Fundoscopy of retina in order to identify retinal hemorrhage, post mortem ocular examination. Post mortem findings also aid in the identification of condition of visible impairment that may be cause of the death of an individual, for an instance, accidental death or traffic accidents.

Cornea

Transparent avascular tissue present in the eye is called cornea. The orphological changes that occur inside cornea during post mortem interval (PMI) help in the forensic investigation. Loss of corneal reflex after death is used as parameter for

brainstem death[3]. Certain factors are considered for post mortem examination. These are:

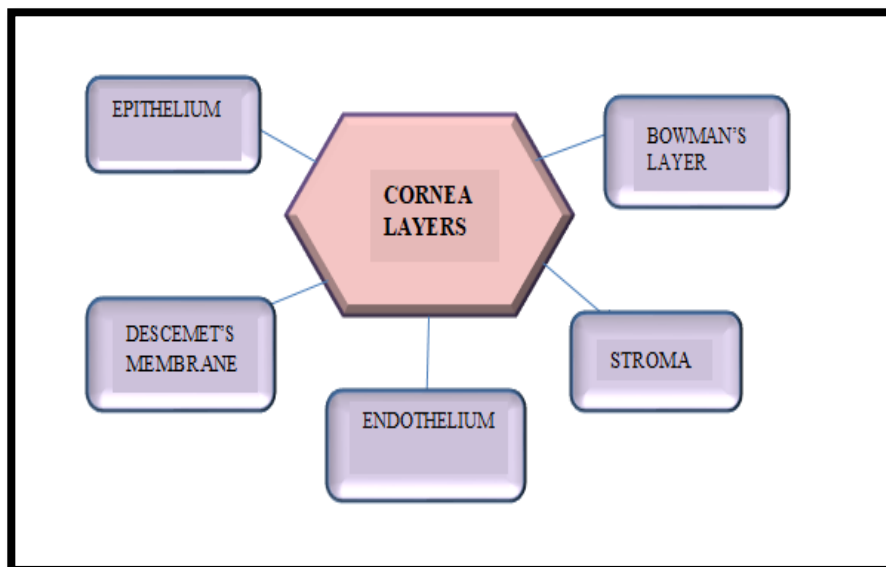
- Corneal opacities
- Corneal thickness

Corneal opacities

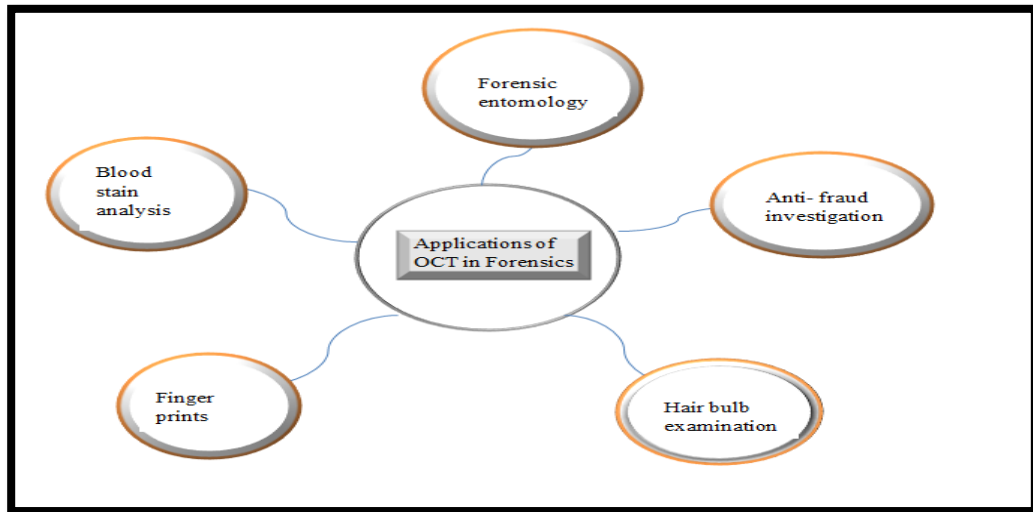
Studies have observed that for 8-12 hour postmortem (hpm), the cornea remains transparent, but there are traces of opacity in some cases between 12 to 18 hpm. Researchers have revealed that there are two variables which are responsible for postmortem changes in corneal transparency, these are; PMI and weather [9]. In contemporary studies, more focus is on the computational image analysis to extract significant features of corneal images and to refine them in order to make conclusion about the time since death. [3,9]. For classifying the identified data, machine learning systems are employed to form and apply algorithms. The disparity in corneal turbidity or transparency has been studied by forensic pathologists. Due to dearth robust data, the use of the computational model is restricted [9].

Corneal thickness

The thickness of cornea depends on the region. There are five layers of cornea.



Corneal thickness can be considered as an important parameter for PMI [9]. Variety of techniques is employed by researchers such as optical coherence tomography (OCT), it has high forensic significance as provides good measurement reliability as well as high resolution scans. Apart from ophthalmology, OCT is used in many other forensic disciplines [10].



Iris and pupil

Dilating and constricting of the pupil the two reactions or the functions performed by iris physiologically. To diagnose the death, the rectifiable loss of brain functioning along with the pupil size is considered as a definite parameter. Reactions and appearance of pupil are used as a parameter to determine death [3]. After death, the iris undergoes numerous changes. Some researchers have found that with the PMI, the color of iris changes within 48 hours of death, blue eyes get transformed into black or brown color. The correlation of size of pupil with PMI and the mechanism is not established adequately. Postmortem changes in the pupil was analyzed by researchers using computation analysis of digital images of iris –pupil regions. During lifespan of an individual, many exogenous substances such as opioids, alcohol etc. can affect eye in numerous ways, these changes include, change in the size of pupil and its reaction towards light. However, these factors may or may no longer be evident of death. [11]. The utilization of pilocarpine eye drops provide appropriate way for eliminating PMI by making use of pupil size. Pupils do not show variation individualistically as the time passes after the death, but for constricting the pupil, pilocarpine drops are used. The reaction of the pupil towards pilocarpine and prostigmine was quite faster and more noticeable [3,9,11]. Researchers have found that the divergence in the pupil-iris ratio after the administration of substances such as acetylcholine and tropicamide were due to the unconstrained postmortem changes in the pupil diameter rather than response towards pharmacological stimuli evaluate PMI must be taken into consideration with ex orbitant wariness because of lack of supporting evidences [9].

Iris as a biometric tool

Another role of iris in forensic medicine is its applicability in the field of biometrics; which is the science of identification of the individual on the basis of one's characteristics. Biometrics is used in law enforcement agencies and it is decisive technique for identification. Apart from iris, other biometric identifiers are

fingerprints, voice, signature, hand and face geometry etc. The iris pattern is unique in every individual and hence, helps in distinguishing any particular individual from others. Moreover, there is difference in pattern between left and right eye, even the identical twins show differentiation in their iris pattern, making it biometrically distinctive. Iris biometric technology is highly employed for access control and even in the identification purposes. Recognition of iris in the corpse results in the deterioration of the algorithm accuracy because of the postmortem changes. [3].

Retina

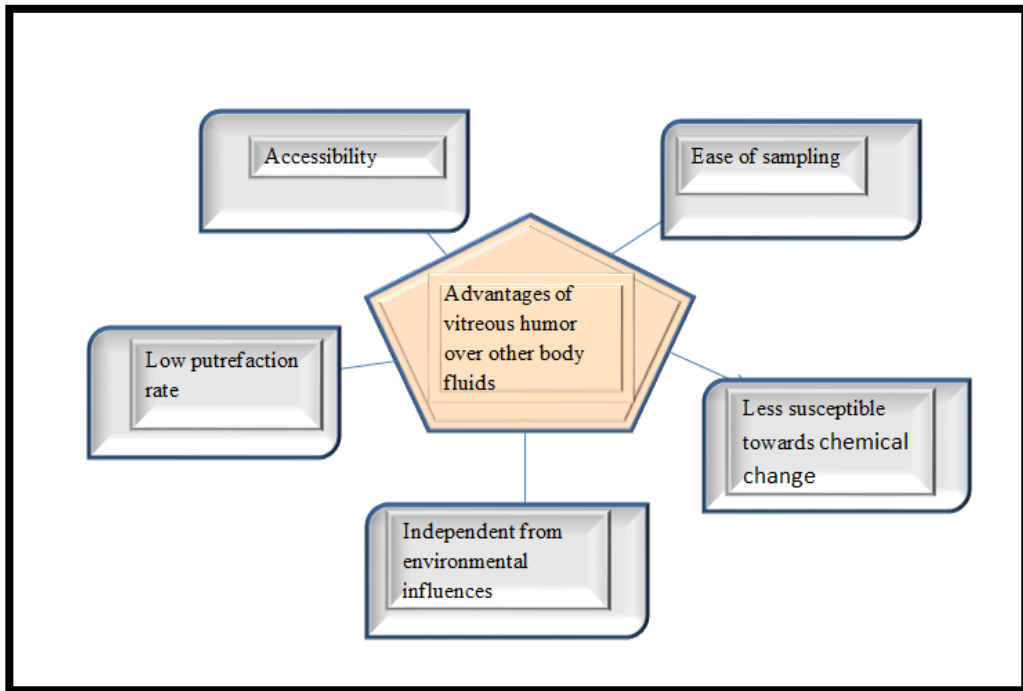
Retina comprises of layers of specialized neurons as well as vascular networks. Retinal vessel segmentation or trucking (kevorkian sign) initiates after death. There is enhancement of pallor inside the retina with the increase of PMI. After the few hours of death, the outline of the dusk becomes hazy. The retinal changes are directly related to the PMI, but it is quite complicated for forensic pathologist to observe these changes and there is high range of subjectivity in this context. Ophthalmoscopy technique is used to identify and examine the post mortem changes in the retinal vessels and it is stated that these changes are due to the cardio circulatory arrest. The segmentation as seen through the ophthalmoscopy begins after 10-15 minutes after death occurs. There is no evidence of investigation of retinal changes through the imaging techniques. Variations in the color have been described in some studies but there is high level of subjectivity. There is not much data available regarding the relationship between the PMI and retinal changes.[4,9,11].

Lens

Lenses are also an important component of human eye and they do change their transparency with the time. The loss of lens transparency during postmortem is the result metabolic processes that take place along with the necrosis process. After the death there is cessation of active transport that causes the accumulation of potassium and later calcium and chloride. The evolving oxidizing agents leads to the attachment and accumulation of proteins, subsequently leading to opacification of lens. All these bio chemical changes direct us towards the possibility of opting lens for assistance in the PMI[3,11].

Vitreous humor

The variations in the concentrations of bio-chemicals during postmortem changes in the vitreous humor act as prominent tool for estimation of PMI. The gel like fluid that fills the eyeball is the vitreous humor. During the PMI, for the biochemical analysis, vitreous humor is utilized over the body fluids.[11]. Vitreous fluid is used as in the death investigations in which the death is related to the ketoacidosis and hypothermia. Vitreous humor is used as an alternative matrix in the forensic toxicology because of its uniqueness, relative isolation from other compartments of the body, secretion and filtrations of materials, due to its limited vascularization, it protects itself from bacterial contamination.



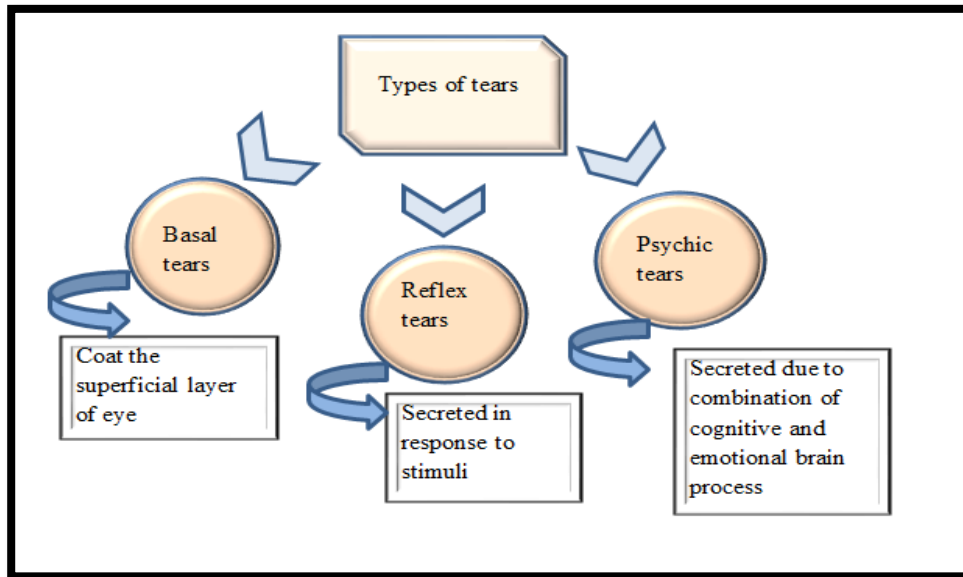
There is insufficient data and dearth of analytical techniques that are developed for the analysis of vitreous humor. There are chances of loss of water from eye with the time since death as well as body storage conditions, which causes the enhancement in the concentration of vitreous humor as well as the analyte. The other parameters that are taken into consideration includes such as immersion in water etc. various chemical are also analyzed in order to know and examine their change with increased PMI. These chemicals are potassium, urea, glucose, sodium etc.[3,11]

Tears as forensic evidence

Body fluids play a vital role in the investigation of crime scene. There are many body fluids that aids in forensic analysis and investigation such as blood, semen, saliva, urine, vaginal secretions, tears etc. The response of an individual towards emotional and stressful situation leads to the secretion of tears. In the cases, when there is unavailability of body fluids, tears play a significant role in that case and helps in personal identification of an individual by the examination of the biochemistry as well as the molecular aspects in order to obtain entire profile of DNA. [12,13] Glands namely, tears ducts or lacrimal glands are found in the eye of almost all the mammals residing on land. The tears performs various functions including:

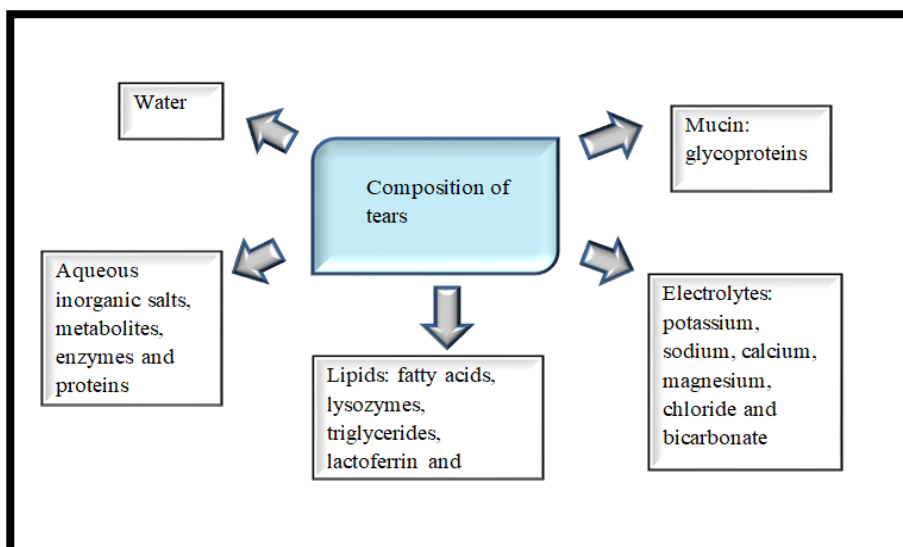
- Lubrication
- Removing of irritants
- Assist immune system
- Heals damage of eye surface
- Prevents dryness

- Supplies oxygen and nutrition to eyes
- Prevents infection



Composition of tears

Although, the tears are secreted in minimal quantity as compared to other body fluids, the film of tears comprises of high concentration of ions, proteins and antioxidants.

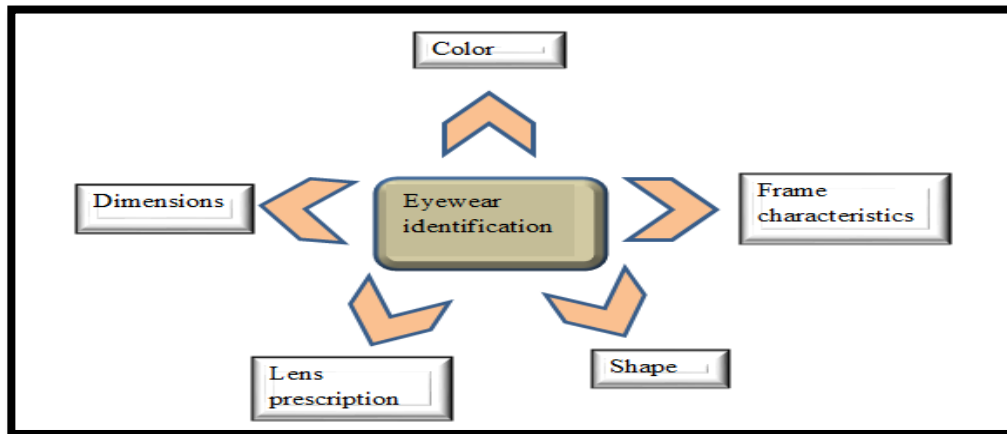


Applications of tears in personal identification

Identification of the individual is the major aspect in the crime investigation. Many cases in today's scenario are solved routinely on the basis of DNA technology. Amalgamation of tears as well as the eye wear would definitely empower the forensic clues. Human tears can be found in many cases that change the emotional behavior of an individual from the tear deposits that are found on various substrates such as tissues, clothes, handkerchief, pillows, bedding etc. The presence of tears in any case denotes that the victim was disturbed or harassed emotionally. The cases include: Rape, Kidnapping, murder, suicide, torture by inducing pain etc. Therefore, tears can be considered as an imperative tool or trace evidence having quite high evidentiary value and are used for positive personal identification during forensic investigation. In case, there is eyewear, say contact lens, present at the crime scene, it will contain plenty of corneal epithelial DNA which can be analyzed for personal identification. Tears can also be used for determining the therapeutic or psychotropic drugs and it can provide immense clues related both to qualitative and quantitative analysis for personal identification of an individual.[12,13]

Role of eyewear in forensic science

The evidences that are collected from the crime scene must be related to that particular case. The role of eyewear as well as its use in forensic investigation is not reported much and is less focused till date. Despite being less focused, the robustness of the eyewear evidence is quite immense. Eyewears that can be used as forensic evidences include spectacles and contact lenses etc. Due to the lack of cognizance, of possibility of recovering eyewear as an evidence, therefore, no such protocols have been made for the recovery and analysis of such evidences. [12]. The contact lens has infrequent applicability in forensic investigations. In some cases, like mass disaster, forensic investigators make use of medical or dental information, anthropology or DNA analysis in order to identify the deceased. Moreover, other parameters such as personal identification, belongings or clothing can also aid in the identification process. Prescription of spectacles or other eye wear also contributes to the identification of unknown people. The degree of effectiveness of use of prescription is still undetermined. Comparing the lensometry findings, with the ophthalmic records is efficacious way in order to find the match and link the unknown individual to the information present in the patient's medical record. [12,14,15].



Future perspectives

With the advancement of technology, the future avenues for the investigation in this area of Forensic ophthalmology are likely to open up. For the initial examination of eye in forensic autopsy or postmortem cases, ophthalmic endoscopy is used, but still this technique is not used routinely. RetCam and OCT are also been used but there is high subjectivity because there is inherent difficulty due to postmortem changes that occur inside the eye[3]. A web based tool namely, Optosearch is employed to determine the frequency with which the prescription and its elements generally occur in a population. The strength of match between refractive error as well as individual's antemortem ophthalmic record can be generated on the basis of objective statistics. [14].

Conclusion

Forensic ophthalmology is the discipline which is still in its development stage and is yet to get streamlined with the other forensic investigations. Identification of any individual can be done on the basis of the eye characteristics. Moreover, eye also acts as an imperative tool in postmortem interval investigation. The changes occurring inside the eye will aid in the death investigation. Furthermore, the eyewears also assist in the personal identification of an unidentified individual. The amalgamation of skills, expertise and knowledge in both the fields' i.e., forensics and ophthalmology should pursue in order to understand the use of eye in detail and how it can assist in forensic investigation. By doing so, we can enhance our understanding of forensic ophthalmology and assist the forensic pathologists in the postmortem investigations.

References

1. Behera, A., Das, S. and Das, G.S., 2005. Eye is the spy of Forensic medicine. Medico-legal Update, 5, pp.04-2006.
2. Iorliam, A., 2018. Subdivisions of Forensic Science. In Fundamental Computing Forensics for Africa (pp. 17-56). Springer, Cham.

3. Ang, J.L., Collis, S., Dhillon, B. and Cackett, P., 2021. The Eye in Forensic Medicine: A Narrative Review. *The Asia-Pacific Journal of Ophthalmology*, 10(5), pp.486-494.
4. Davis, N.L., Wetli, C.V. and Shakin, J.L., 2006. The retina in forensic medicine: applications of ophthalmic endoscopy: the first 100 cases. *The American journal of forensic medicine and pathology*, 27(1), pp.1-10.
5. Marano, Leonardo Arduino, and CintiaFridman. "DNA phenotyping: current application in forensic science." *Research and Reports in Forensic Medical Science* 9 (2019): 1-8.
6. Devranoglu, Dilara, IlksenTavaci, GonulFiloglu, and Ozlem Bulbul. "Effect of Type of Degraded DNA Samples on Human Eye Color Prediction." *Pakistan Journal of Zoology* 53, no. 4 (2021).
7. Carratto, T.M.T., Marcorin, L., do Valle-Silva, G., de Oliveira, M.L.G., Donadi, E.A., Simões, A.L., Castelli, E.C. and Mendes-Junior, C.T., 2021. Prediction of eye and hair pigmentation phenotypes using the HirisPlex system in a Brazilian admixed population sample. *International Journal of Legal Medicine*, 135(4), pp.1329-1339.
8. White, D. and Rabago-Smith, M., 2011. Genotype–phenotype associations and human eye color. *Journal of human genetics*, 56(1), pp.5-7.
9. De-Giorgio, F., Grassi, S., d'Aloja, E. and Pascali, V.L., 2021. Post-mortem ocular changes and time since death: scoping review and future perspective. *Legal Medicine*, 50, p.101862.
10. Nioi, M., Napoli, P.E., Mayerson, S.M., Fossarello, M. and d'Aloja, E., 2019. Optical coherence tomography in forensic sciences: A review of the literature. *Forensic Science, Medicine and Pathology*, 15(3), pp.445-452.
11. Dangel, L., 2020. The Eyes as a Postmortem Interval Estimation Method. *DU Quark*, 5(1), pp.14-22.
12. Aparna, R.S.I.R. and Iyer, R.S., 2020. Tears and eyewear in forensic investigation—A review. *Forensic Science International*, 306, p.110055.
13. O'SULLIVAN, K.K., 2012. Tears and Trial: Weeping as Forensic Evidence in *Piers Plowman*. In *Crying in the Middle Ages* (pp. 223-237). Routledge.
14. Collins, R.S. and Berg, G.E., 2008. Forensic application of optical correction. *Optometry-Journal of the American Optometric Association*, 79(4), pp.203-207.
15. Zwerling, C.S., 2016. Forensic analysis of a contact lens in a murder case. *Journal of forensic sciences*, 61(2), pp.534-539.