

How to Cite:

Jain, A., Brar, G., Chawla, U., Kaur, S., & Joseph, K. (2021). Fascial space infection patients reporting to department of oral and maxillofacial surgery at Dasmesh Institute of Research and Dental Sciences, Faridkot: A retrospective study. *International Journal of Health Sciences*, 5(S2), 459–467. <https://doi.org/10.53730/ijhs.v5nS2.6772>

Fascial space infection patients reporting to department of oral and maxillofacial surgery at Dasmesh Institute of Research and Dental Sciences, Faridkot: A retrospective study

Dr. Amul Jain

Assistant Professor, Department Of Oral and Maxillofacial Surgery, Dasmesh Institute of Research And Dental Sciences, Faridkot, Punjab, India

Email: amuljaindr@gmail.com

Dr. Gursimrat Brar

Associate Professor, Department Of Oral and Maxillofacial Surgery, Dasmesh Institute of Research and Dental Sciences, Faridkot, Punjab, India

Coressponding author email : docginnie@gmail.com

Dr. Ujjwal Chawla

(JR-I), Department Of Oral and Maxillofacial Surgery, Dasmesh Institute of Research and Dental Sciences, Faridkot, Punjab, India

Email: chawla.ujjwal007@gmail.com

Dr. Simran Kaur,

(JR-III), Department Of Oral and Maxillofacial Surgery, Dasmesh Institute of Research and Dental Sciences, Faridkot, Punjab, India

Email: simranpurba94@gmail.com

Dr. K. Joseph

(JR-III), Department Of Oral and Maxillofacial Surgery, Dasmesh Institute of Research and Dental Sciences, Faridkot, Punjab, India

Email: drjosephk123@gmail.com

Abstract---This aim of this study is being conducted to assess the incidence of fascial space infection and its management in patients presenting to department of Oral and Maxillofacial Surgery at Dasmesh Institute of Research and Dental Sciences, Faridkot. This retrospective study was done the in the Department of Oral and Maxillofacial Surgery Dasmesh Institute of Research and Dental Sciences, Faridkot, India, from January 2015 to December 2020. Total 84 fascial space infection record of previous five year patients (reporting to Department of Oral and Maxillofacial Surgery was

evaluated. Patients reported with fascial space infection with age group from 16-70 yrs and ASA I & I were included in this study. The age group most commonly involved was in the third and fourth decades of life. The mean age group was 33.55. Males (55.95%) were more commonly involved than females (44.05%). The most commonly involved space was Right submandibular space infection (17.86%) followed by left submandibular space infection 15.48, R buccal space infection (9.52%), Left buccal space infection (7.14%), Right infraorbital space infection (7.14%), Left pterygomandibular space infection (7.14%), Space infection wrt left submandibular space, submental space, left sublingual space(5.95%), Masticatory space infection with impending submandibular + submental cellulitis (5.95%), Space infection wrt left submandibular space(4.76%), Left Masticatory space infection and Space infection bilateral submandibular, submental, Chronic RT buccal space infection(3.57%) each and Mental space infection was present in very low concentration (1.19%). Preexisting dental infections are the commonest causes of fascial space infections of the head and neck region. Regular dental visits may enhance early detection and treatment of dental ailments, thereby preventing development of fascial space abscess or cellulitis.

Keywords---space infection, head, neck, submandibular, cellulitis.

Introduction

Since Galen's time in the second century, fascial space infection has been identified and documented. Man's battle against microbes stretches back to ancient civilisation Chaulmoogra oil was used by ancient Indians to treat leprosy.' Bacterial infections in the head and neck area are mostly caused by pre-existing dental caries-related sequelae such as pulpitis and apical periodontitis, pericoronitis, or periodontal disorders. Tonsillitis, gunshot wounds, peritonsillar or parapharyngeal abscesses, mandibular fracture, oral lacerations/piercings, or submandibular sialodentitis are all known causes. Anatomical and microbiological variables, as well as host resistance deterioration, might result in the development of a localised odontogenic infection into a maxillofacial space infection if sufficient therapy is not received in the early stages (MSI). In rural regions with poor oral hygiene, acute space infection in the fascial spaces of the neck is frequent. Regular dental checkups may improve early identification and treatment of oral problems, avoiding the development of fascial space abscess or cellulitis. Despite this, even after decades of investigation, humanity has not been able to completely eradicate microbial diseases. 2-s Domgk's discovery of sulfonamides and Alexander Fleming's discovery of penicillin are hopeful tendencies toward microbial infection conquest. Although Penicillin was thought to be the long-awaited cure for tooth infection, the bacteriological spectrum of the oral flora and our awareness of its complexity have evolved rapidly since its introduction, and microorganisms are still one step ahead. Antibiotics that are newer and more powerful have also met with fierce opposition. Treatment of localized infection was probably the first primitive surgical procedure performed, and it most likely involved the opening of bulging abscesses with sharp stones or

pointed sticks. Even today the principle remains the same though the technique has improved.' A greater number of medically impaired patients with changed defence systems, a shift in oral microbial flora toward more resistant forms, and a shift in the efficacy of traditional antibiotic therapy have all raised the risk of catastrophic tooth infection sequelae." As a result, knowing the pathogenesis and correct therapy of oral infections is essential for the dental practitioner. Deaths and complications have also been decreased as a result of prompt intervention and the availability of newer antibiotic treatment with broad-spectrum coverage. However, some cases of deep facial space infections are difficult to treat, particularly in immunocompromised individuals such as those with HIV or diabetes, where the spread can be very fast and cause morbidity and death. Most patients receive treatment in the form of incision and drainage, along with the prescription of broad-spectrum antibiotics. When the airway is damaged, other life-saving procedures, such as tracheostomy, may be necessary.⁶

Material and Methods

This retrospective study was carried out in the Department of Oral and Maxillofacial Surgery, Dasmesh Institute of Research and Dental Sciences, Faridkot, India, between January 2015 and December 2020, with the consent of the protocol review committee and the institutional ethics committee. After obtaining informed consent, a comprehensive history was obtained from the patient or family members. A total of 84 patients' facial space infection records over the preceding five years (reported to the Department of Oral and Maxillofacial Surgery) were reviewed.

Inclusion criteria

Patients reported with facial space infection with age group from 16-70 yrs. ASA I & II.

Exclusion criteria

All medically compromised patients. Data collection and analysis: All collected information was entered in excel sheet. Analysis was done in the form of percentage and mean values.

Results

Extraction was performed, followed by incision and drainage. In a few situations, just extraction was performed. Needle aspiration and collection of samples with a swab through an incision were performed, and the samples were submitted to a range of tests, including clinical effectiveness of antibiotics. The most prevalent age group engaged was in their third and fourth decades of life. The average age group was 33.55 years old. Males were more likely to be involved (55.95%) than females (44.05%). The most commonly involved space was right submandibular space infection (17.86%), followed by left submandibular space infection (15.48), right buccal space infection (9.52%), left buccal space infection (7.14%), right infraorbital space infection (7.14%), left pterygomandibular space infection (7.14%), and left pterygomandibular space infection (7.14%). Masticatory space

infection with imminent submandibular + submental cellulitis 5.95 percent, Space infection with left submandibular space 4.76 percent, Left Masticatory space infection and Space infection B/L submandibular, submental, Chronic RT buccal space infection 3.57 percent each and Infection of the mental space was found in a small number of people (1.19%).

Gender	Number	Percentage
Male	47	55.95
Female	37	44.05
Age in Years		
Below 30	31	36.90
30-40	22	26.19
40-50	20	23.81
50-60	8	9.52
Above 60	3	3.57

Diagnosis	Number	Percentage
Submental space infection	3	3.57
Right submandibular space infection	15	17.86
Left submandibular infection	13	15.48
Right buccal space infection	8	9.52
Left buccal space infection	6	7.14
Right infraorbital space infection	6	7.14
Chronic right buccal space infection	3	3.57
Impending Ludwig's angina	2	2.31
Ludwig Angina	2	2.31
Space infection w.r.t Left submandibular space + Submental space + Left sublingual space	5	5.95
Left pterygomandibular space infection	6	7.14
Masticatory space infection with impending Submandibular + Submental Cellulitis	5	5.95
Left masticatory space infection	3	3.57
Space infection B/L Submandibular + Submental space infection	3	3.57
Space infection w.r.t Left submandibular Space	4	4.76

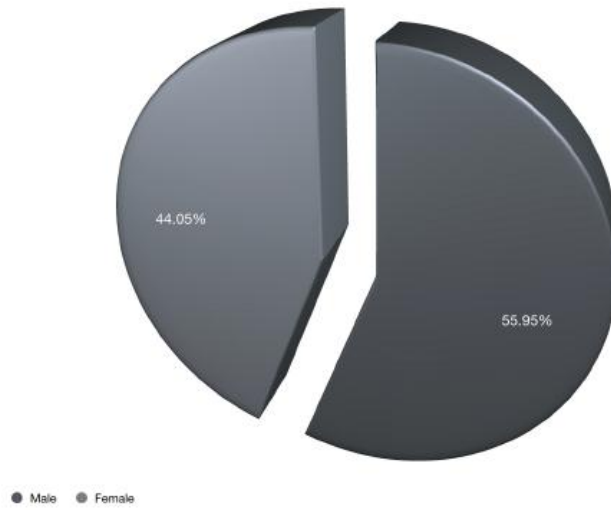


Figure 1. Gender wise percentage distribution

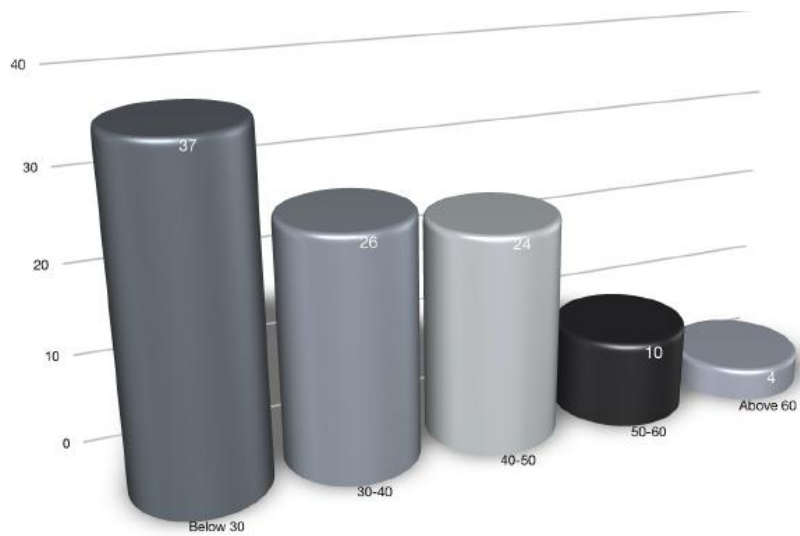


Figure 2. Age wise percentage distribution

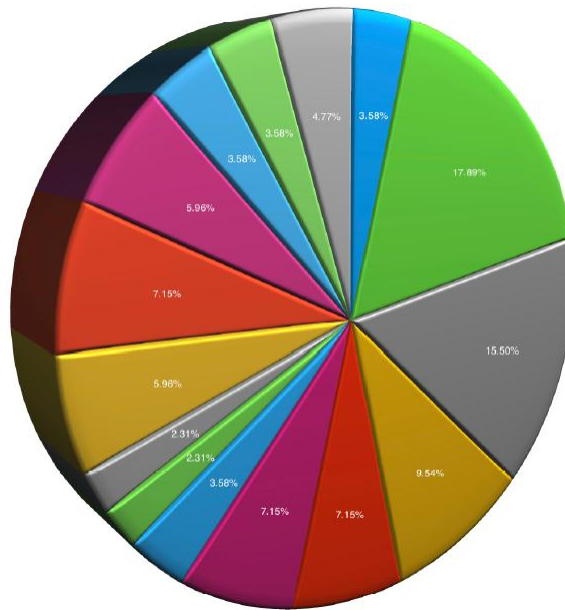


Figure 3. Fascial space wise distribution

- Submental space infection
- Right submandibular space infection
- Left submandibular space infection
- Left submandibular space infection
- Right buccal space infection
- Left buccal space infection
- Right infraorbital space infection
- Chronic right buccal space infection
- Impending Ludwig's angina
- Ludwig Angina
- Space infection w.r.t Left submandibular space + Submental space + Left sublingual space
- Left pterygomandibular space infection
- Masticatory space infection with impending Submandibular + Submental Cellulitis
- Left masticatory space infection
- Space infection B/L Submandibular + Submental space infection

Discussion

Bacterial infections in the head and neck area are mostly caused by pre-existing dental caries-related sequelae such as pulpitis and apical periodontitis, pericoronitis, or periodontal disorders. Tonsillitis, gunshot wounds, peritonsillar or parapharyngeal abscesses, mandibular fracture, oral lacerations/piercings, and submandibular sialodentitis are all known causes. A periapical lesion, periodontal disease, pericoronal issue, post surgical infection, or direct trauma resulting in epithelial breach might all be the source of maxillofacial infection. f these odontogenic ones are most commonly encountered. 7-11 Typically, an

untreated or neglected decaying tooth becomes the root cause of a severe and sometimes fatal infection. In a nation like India, where healthcare providers are scarce and facilities are limited, being unaware of a dental disease worsens the situation. Complications such as retropharyngeal spread and cerebral extension, as well as mediastinal spread and airway obstruction, suggest that these infections can be fatal.²⁻³² The presentation of the patient's illness is governed by complicated microbiota, affected teeth, and anatomic spread pathways.²³ For certainly, incision and drainage are the major treatments, but identifying the implicated bacteria and sensitivity pattern is a significant aspect of it. Many times, even after adequate surgical treatment, the patient's condition does not improve; one of the major reasons for this is the presence of resistant bacterial strains and the use of inappropriate antibiotics.^{23,24}

Our study included 84 individuals with orofacial odontogenic space infections. The most prevalent age group engaged was in their third and fourth decades of life. The average age group was 33.55 years old. This observation corresponds to the age distribution described by Hunt et al²⁵ and Virolainen et al.²⁶ Males were more likely to be involved (55.95%) than females (44.05%). This finding may be compared to the study conducted by Goldberg et al.⁷ Hunt's study found that females outnumbered males.²⁵ Mandibular first molar was the most common causative tooth followed by mandibular third molar. This finding can be compared with the study by Store et al. ¹¹ where third molar was the commonest tooth followed by second and first molars. Right submandibular space infection accounted for 17.86 percent of all infections; followed by left submandibular space infection (15.48 percent), right buccal space infection (9.52 percent), left buccal space infection (7.14 percent), right infraorbital space infection (7.14 percent), left pterygomandibular space infection (7.14 percent), and left pterygomandibular space infection (7.14 percent). Masticatory space infection with impending submandibular + submental cellulitis 5.95 percent, Space infection with left submandibular space 4.76 percent, Left Masticatory space infection and Space infection B/L submandibular, submental, Chronic RT buccal space infection 3.57 percent each and Mental space infection was present in very low concentration 1.19%. This finding was similar to the findings of Store ¹¹, Goldberg et al.⁷ Wang ²⁷, Akst ²⁸.

Conclusion

Pre-existing dental infections are the most prevalent cause of head and neck facial space infections. Regular dental checkups may improve early identification and treatment of dental problems, avoiding the development of facial space abscess or cellulitis. Early detection and treatment of established infections is critical to avoiding significant morbidity and death, particularly in elderly individuals with an underlying systemic disease.

References

1. Topazian RG, Goldberg MH, Hupp JR (2002) Oral and maxillofacial infections, 4th edn. W.B.Saunders, Philadelphia
2. Hunt DE, King TJ, Fuller GE (1978) Antibiotic susceptibility of bacteria isolate from oral infections. J Oral Surg 36:527-529

3. Virolainen E, Haapaniemi J, Aitasalo K, Suonpaa J (1979) Deep neck infections. *Int J Oral Surg* 8:407-411
4. Aderhold L, Knothe H, Frenkel G (1981) Bacteriology of dentigenous pyogenic infections. *Oral Surg* 52:583-587
5. S. Konow LV, Nord CE, Nordenram A (1981) Anaerobic bacteria in dentoalveolar infections. *Int J Oral Surg* 10:313-322
6. Prabhu, S.R and Nirmalkumar, E.S., 2019. Acute fascial space infections of the Neck: 1034 cases in 17 years follow up. *Annals of maxillofacial surgery*, 9(1),P.118
7. Goldberg MH, Nemarich AN, Marco WP (1985) Complications after mandibular third molar surgery: a statistical analysis of 500 consecutive procedures in private practice. *J Am Dent Assoc* 111:277-279
8. Allen D, Loughnan TE, Ord RA (1985) A re-evaluation of the role of tracheostomy in Ludwig's angina. *J Oral Maxillofac Surg* 43:436-439
9. Peterson LJ (1993) Contemporary management of deep infections of the neck. *J Oral Maxillofac Surg* 51:226-231
10. Kuriyama T, Karasawa T, Nakagawa K, Saiki Y, Yamamoto E, Nakamura S (2000) Bacteriologic features and antimicrobial susceptibility in isolates from orofacial odontogenic infections. *Oral Surg Oral Med Oral Pathol Oral Radiol Endod* 90:600-608
11. Store W, Haug RI, Lillich TT (2001) The changing face of odontogenic infections. *J Oral Maxillofac Surg* 59:739-748
12. Al-Belasy FA, Hairam AR (2003) The efficacy of azithromycin in the treatment of acute infraorbital space infection. *J Oral Maxillofac Surg* 61:310-316
13. Sixou JL, Magaud C, Gougeon AJ, Cormier M, Bonnaure-Mallet M, RENNIES M (2003) Microbiology of mandibular third molar pericoronitis: incidence of β -lactamase-producing bacteria. *Oral Surg Oral Med Oral Pathol Oral Radiol Endod* 95:855-859
14. Umeda M, Minamikawa I, Komatsubara H, Shibuya Y, Yokoo S, Komori T et al (2003) Necrotizing fasciitis caused by dental infection: a retrospective analysis of 9 cases and a review of the literature. *Oral Surg Oral Med Oral Pathol Oral Radio Endod* 95:283-290
15. Wang LF, Kuo WR, Tsai SM, Huang KJ (2003) Characterizations of life-threatening deep cervical space infections: a review of one hundred ninety-six cases. *Am J Otolaryngol* 24:111-117
16. Biller JA, Mur AH (2004) The importance of etiology on the clinical course of neck abscesses. *Otolaryngol Head Neck Surg* 131:388-391
17. Patel SM, Mo JH, Walker MI, Adley B, Noskin GA (2004) Epidural abscess and osteomyelitis due to *actinobacillus actinomycetemcomitans*. *Diagn Microbiol Infect Dis* 50:283_285
18. Stefanopoulos PK, Kolokotronis A (2004) The clinical significance of anaerobic bacteria in acute orofacial odontogenic infections. *Oral Surg Oral Med Oral Pathol Oral Radiol Endod* 98:398-408
19. Ohshima A, Arijii Y, Goto M, Izumi M, Naitoh M, Kurita K (2004) Anatomic considerations for the spread of odontogenic infection originating from the pericoronitis of impacted mandibular third molar: computed tomographic analyses. *Oral Surg Oral Med Oral Pathol Oral Radiol Endod* 98:589-597
20. Lida Y, Honda K, Suzuki T, Matsukawa S, Kawal T et al (2004) Brain abscess in which *porphyromonas gingivalis* was detected in cerebrospinal fluid. *British. J Oral Maxillofac Surg* 42:180

21. Mihos P, Potaris K, Gakidis I, Papadakis D, Rallis G (2004) Management of descending necrotizing mediastinitis. *J Oral Maxillofac Surg* 62:966-972
22. Huang TI, Tseng FY, Liu TC, Hsu C, Chen YS (2005) Deep neck infection in diabetic patients: comparison of clinical picture and outcomes with nondiabetic patients. *Otolaryngol Head Neck Surg* 132:943-947
23. Topazian RG, Goldberg MH, Hupp JR (2002) *Oral and maxillofacial infections*, 4th edn. W.B.Saunders, Philadelphia
24. Scolozzi Lombardi T, Edney T, Jaques B (2005) Enteric bacteria osteomyelitis. *Oral Surg Oral Med Oral Pathol Oral Radio Endod* 99:B42-E46
25. Hunt DE, King T3, Fuller GE (1978) Antibiotic susceptibility of bacteria isolated from oral infections. *J Oral Surg* 36:527-529
26. Virolainen E, Haapaniemi J, Aitasalo K, Suonpaa J (1979) Deep neck infections. *Int J Oral Surg* 8:407-411
27. Wang J, Ahani A, Pogrel MA (2005) A five year retrospective study of odontogenic maxillofacial infections in a large urban public hospital. *Int J Oral Maxillofac Surg* 34:646-649
28. Akst LM, Albani BJ, Strome M (2005) Subacute infratemporal fossa cellulitis with subsequent abscess formation in an immunocompromised patient. *Am J Otolaryngol* 26:35-38