

How to Cite:

Arora, D., & Arora, P. (2022). Immediate implants in maxillary anterior region with guided bone augmentation: Dual layer grafting approach. *International Journal of Health Sciences*, 6(S2), 7710–7718. <https://doi.org/10.53730/ijhs.v6nS2.6909>

Immediate implants in maxillary anterior region with guided bone augmentation: Dual layer grafting approach

Dr. Dhruv Arora

MDS, Reader, Dept of Prosthodontics, Seema Dental College and Hospital, HNMG University, Rishikesh, Uttarakhand
Corresponding author email: drdhruvarora@gmail.com

Dr. Pareedhi Arora

MDS, Oral & Maxillofacial Surgery, Consultant Oral & Maxillofacial Surgeon
New Delhi
Email: drpareedhi@gmail.com

Abstract---Aim: This case is a combination of vertical and horizontal defect in maxillary anterior region accompanied with absence of facial soft tissue which rehabilitated following extraction of tooth was rehabilitated by guided bone regeneration (GBR) and immediate implant Background: Loss of the labial bony wall during extraction of maxillary anterior teeth is a commonly encountered conundrum. During planning for an immediate implant placement in such a compromised area, guided bone regeneration (GBR) is a well-accepted method for bone and soft tissue reconstruction. Case Description: In the presented case report, a combination of vertical and horizontal defect of more than 2 mm accompanied with absence of facial soft tissue following extraction of tooth was rehabilitated by GBR and immediate implant. The follow - up was performed 36 months after final loading with good esthetic outcome and bone graft well apposed to native bone in CBCT evaluation with no obvious complications. Conclusion: The vertical and horizontal ridge volumetric alterations positively can be achieved by simultaneous GBR with immediate implant placement. Clinical Significance: The purpose of discussing this case report is to portray the efficacy of GBR along with immediate implant in case with both vertical and horizontal bone defects.

Keywords---immediate implants, guided bone regeneration, bio - guide, autograft, xenograft, maxillary anteriors, bone defects.

Introduction

An immediate implant in a prosthetically driven position is a unique challenge dependent on the quantity and quality of bone in the anterior region of maxilla as site of rehabilitation. The restoration with implant placement becomes clinically challenging when the alveolar ridge lacks sufficient bone volume and esthetics are of main importance.¹ Such clinical situations are accompanied with additional surgical procedures of bone augmentation. The advanced procedures such as guided bone regeneration (GBR) have been successful in providing an instrumental & successful path for implant placement with good esthetics and patient outcomes.² Such cases allow the advanced stream of implantology to show a miracle at cellular level where non-osseous cells are filtered and osteoblast derived from the periosteum and the bones are permitted to form new bone. We discuss a case report of guided bone regeneration & immediate implant in maxillary anterior region with both vertical and horizontal bone defect; 36 months follow up.

Materials and Methods

A healthy 71 years old female suffering from Type II Diabetes (controlled) presented with Grade III mobility of the maxillary right and left central incisors.

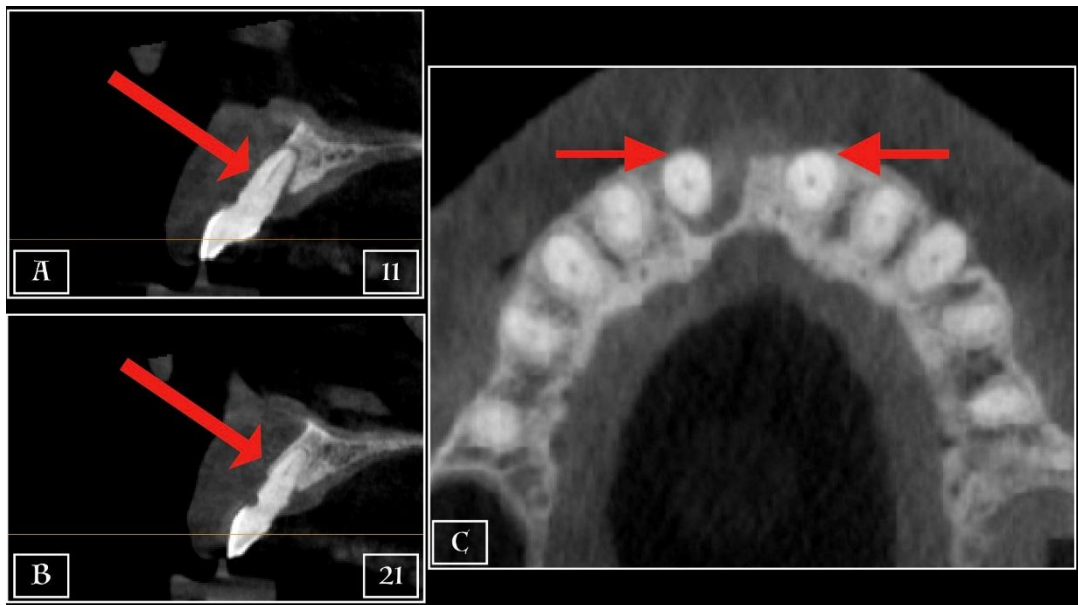

Figure 1 – Pre - Operative Cone Beam CBCT scan

- A. Sagittal section of right central incisor showing absence of labial bone plate
- B. Sagittal section of left central incisor showing crestal resorption upto the middle third of labial bone plate
- C. Axial section of maxillary central incisors showing deficient bone around offending teeth

CBCT evaluation reveals absence of labial facial plate w.r.t 11 and a partial bony plate of about 0.8mm thickness extending only up to the middle third of the tooth w.r.t 21.

Treatment Plan

Tooth 11 and 21 were planned for extracted followed by immediate implant placement with Guided Bone Regeneration (GBR) using bovine xenograft particles (Geistlich Bio-Oss®) and porcine collagen barrier membrane (Geistlich Bio-Gide®).³ The surgical case, analyzed in accordance with Salama et al was classified as Class 3 - deficient buccal bone but implant placement possible in the remaining alveolar housing of extraction socket.⁴ Simultaneous immediate implant with GBR can be performed according to Esposito et al.⁵ It is classified as a Type I surgery (Chen and Buser et al) as immediately after extraction of teeth, implant insertion was planned.⁶ Also, it can be categorized as a Type 2 socket site according to Elian and Tarnow et al, 2007⁷. Therefore, extraction of teeth, socket and labial grafting with immediate implantation were carried out simultaneously. Nobel Active implants were planned to be inserted followed by grafting using Geistlich Bio-Gide® and Geistlich Bio - Oss®.

Case Report

After diagnosis and treatment planning, prophylactic antibiotic regimen (Tab Augmentin 625mg1tds x 3days, Tab Metrogyl 400mg 1bd x 3 days) were given to the patient. On the day of the surgery, written consent was taken from the patient. Blood sugar levels were within normal limits and since there was no contraindication for the administration of local anesthesia, nerve blocks and infiltration with 2% Articaine HCl with 1: 100,000 epinephrine were given. A full thickness papilla preservation flap was raised and extraction of the offending teeth was carried out.

Tooth extraction was done by periotomes and luxators as an atraumatic tooth extraction was imperative. Curettage and socket debridement was done thoroughly leaving no residual granulation tissue. When the socket was ready; a periodontal probe was used to explore and estimate the integrity of the alveolar bone. A vertical defect of 7 mm wrt 11 and total interdental space of approximately 18mm was noted. In available interdental space of 18mm, 2 Nobel active implants were placed.

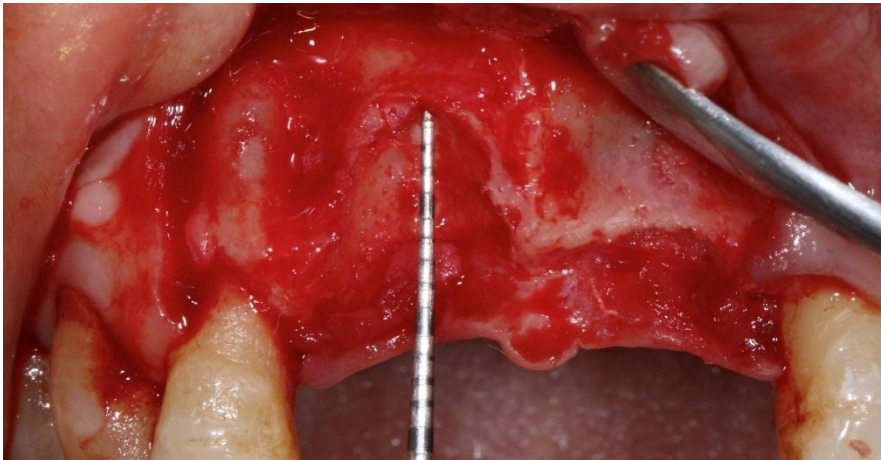


Figure 2 – Post Extraction situation with horizontal and vertical loss of labial walls of both sockets

It was decided that 2 implants of size 4.3 * 10 mm and 3.5 * 10 mm in 11 tooth region and 21 tooth regions respectively would be the ideal choice.

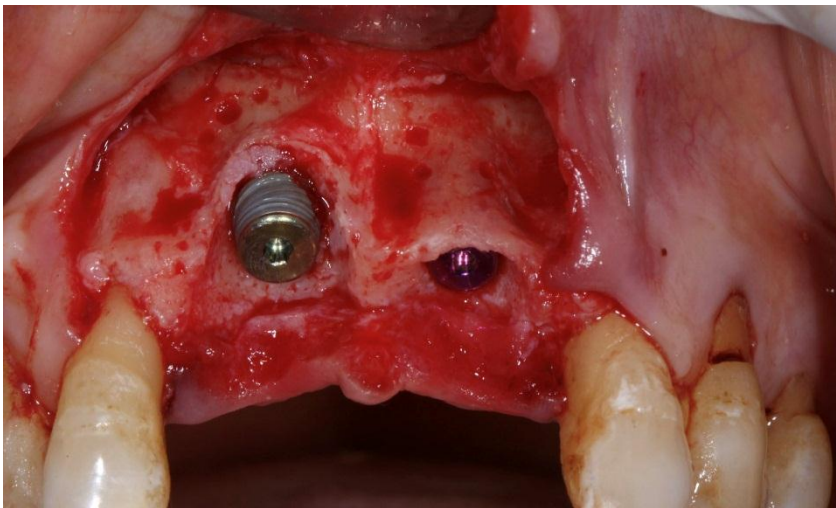


Figure 3 – After Nobel Active Implant Placement, thread exposure of both implants; more exposure of the implant on the right side

Since, for this case there was no buccal bone in 11 tooth region and thin partial buccal plate in 21 tooth regions with exposure of implant threads at both sites was; we decided to go for GBR subsequent to implant placement. For bone graft, autogeneous bone scrapings from the anterior nasal spine were taken using Buser scraper. Blood from the surgical site was collected and the Geistlich Bio-Oss® particles were immersed in it prior to grafting. This was to done to facilitate formation of the Bone Conditioned Media. Contour grafting was done by placing the autogenous bone particles as the first layer followed by the bone conditioned medium (Bio - Oss and blood). Geistlich Bio-Oss® particles become an integral part of the newly formed bone framework and preserve volume over the long term.

The graft material was sealed with Geistlich Bio- Gide® (25 * 15mm) that acted as selective membrane by filtering soft tissue cells and bone forming cells at site of bone formation. Closure of site was achieved and tension free watertight monofilament sutures were given.

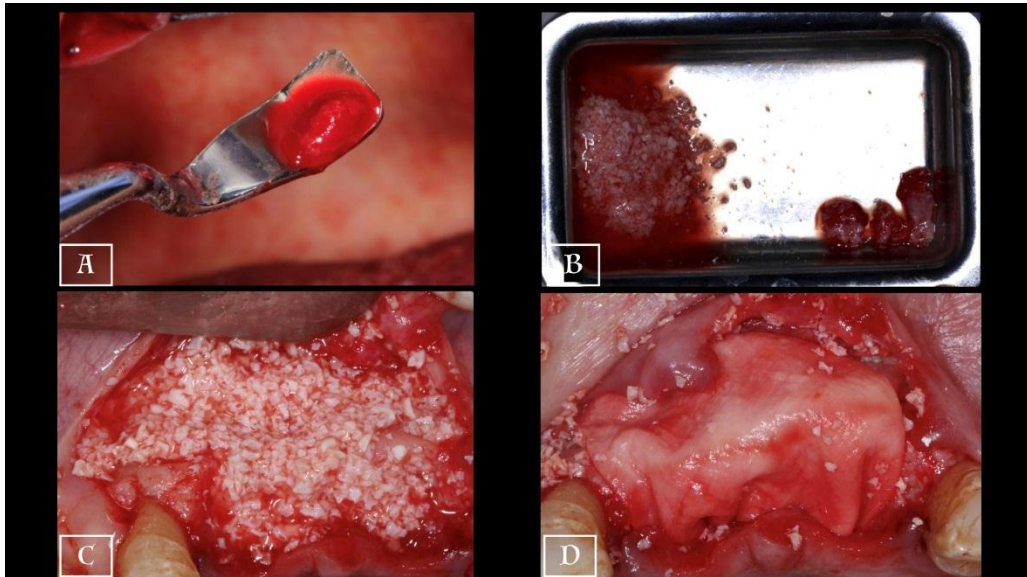


Figure 4 – Guided Bone Regeneration Protocol

- A. Collection of autogenous bone with Buser Scraper
- B. Bone Conditioned Medium (Bio-Oss + Autogenous Blood)
- C. Dual layer grafting with autogenous bone and Geistlich Bio-Oss
- D. Geistlich Bio-Gide placed covering the grafted area

Second stage was done after 3 months to expose the implants and for preservation and enhancement of hard and soft tissues by using internal hex conical connection gingival formers to reduce the stresses on crestal bone. Tissue remodeling with modified provisional or healing abutments were achieved.

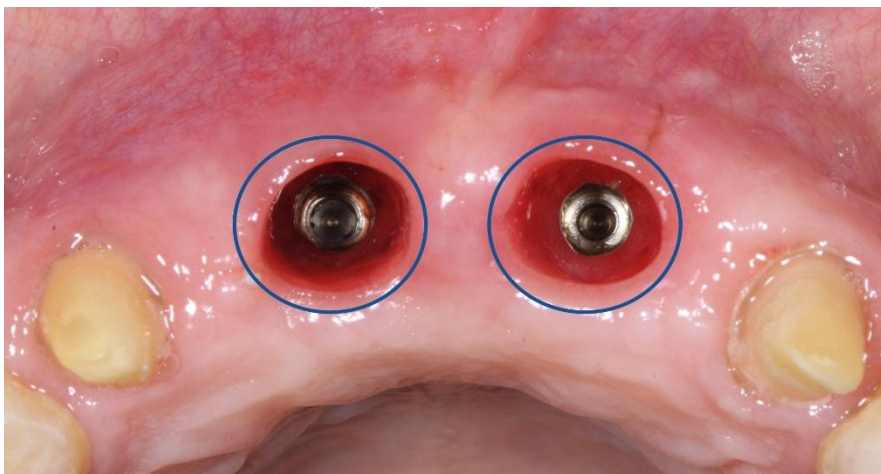


Figure 5 – Emergence profile of peri-implant tissue 3 weeks after 2nd stage surgery

After 15 days of the second stage procedure, temporization was done. After 3 weeks, impressions with addition silicone were made. Gingival mask was applied to the impression copings to account for and maintain record of the soft tissue profile. Confirmation of the accuracy of the impression was done with a Jig trial of pattern resin. Final PFM prosthesis was received from the lab, and tried intra-orally. After minor occlusal adjustments, the prosthesis was cemented with resin reinforced GIC.

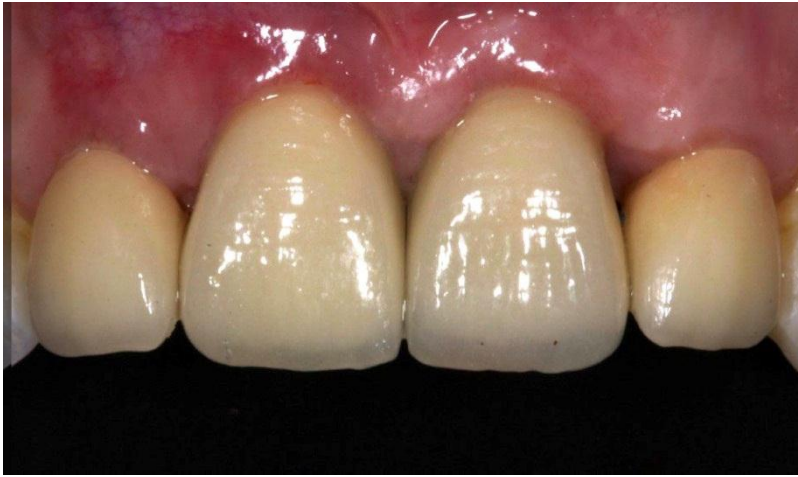

Figure 6 – Final prosthesis after cementation

Follow-up examinations were scheduled regularly revealing preservation of soft tissue width and height in the aesthetic area that were showing good prognostic strength of case. The follow up CBCT done 3 years after the final loading of the implants shows excellent osseointegration of the implants and formation of new stable bone in the augmented area with total patient satisfaction. Labial wall regeneration was upto 2.0 – 2.5 mm in the areas of previously deficient bone.

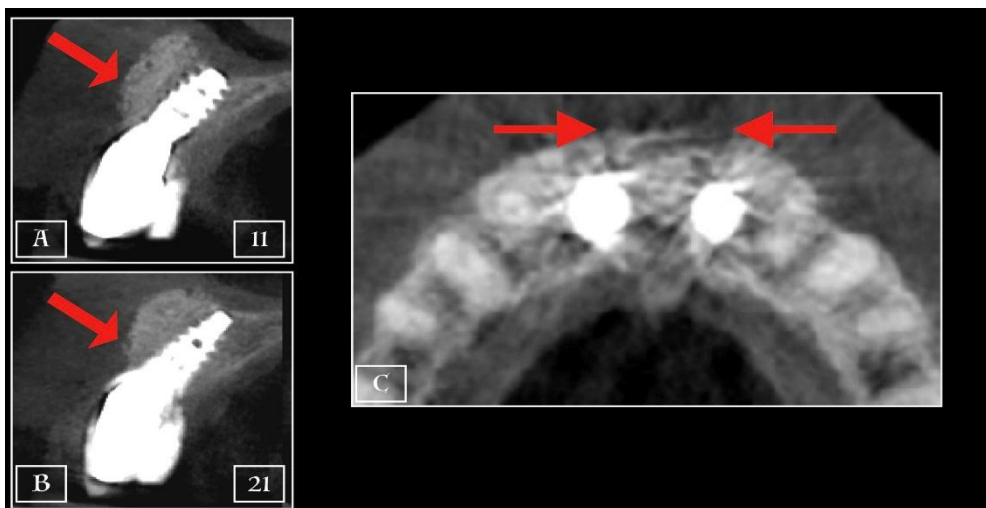


Figure 7 – Follow Up CBCT done after 36 months showing well apposed bone completely covering both the implants homogenously

Discussion

Immediate implant placement after extraction into the existing extraction socket still remains a challenging surgical procedure. It reduces the total treatment time, prevents the loss of soft tissues and gains in esthetic success and various studies have shown that immediate implants have a 90–100% success in survival rate.⁸ There are many advantages of immediate implantation. With this procedure, there is a reduction in the number of surgeries, shorten total treatment time; also aid in preserving the bone and soft tissues at the extraction socket.⁹

The foremost challenge that we are faced with are the prosthetically favorable positioning of the implant. This is followed by extensive GBR procedures to cover any deficient bone areas and exposed implant surfaces so that the fixture is surrounded by sound bone after the healing period. However, in this case specially in region 11 tooth, thickness and height of the facial bone wall was nil making a challenging clinical path for long-term stability of harmonious bony walls and gingival margins around implants.

It cannot be denied that a reliable rehabilitation of the alveolar ridge with endosseous implants requires proper quality and quantity of alveolar bone at the implant site in order to achieve a good long-term prognosis. The question on the table is to find an ideal augmentation material in cases where implant site is in aesthetic zone. Among the options available, autogenous bone harvested from the patient has been considered a gold standard for bone regeneration.¹⁰ Despite this, autogenous grafts are not frequently used clinically due to additional complications such as donor site injury, site limitations, and the added morbidity.^{11, 12}

With the advent of xenogeneic augmentation materials, these situations can be addressed easily. These bone substitutes derived from bones of other species, most commonly bovine, possess sufficient osteoconductivity and biocompatibility for regeneration purposes.¹³ Also, unlike autografts, xenografts dodge the need for a second operative site and have no limits in the availability of additional bone.¹⁴ In our case we exploited both avenues, and the autogenous bone scrapings from anterior nasal spine were conditioned with blood from surgical site and mixed with Geistlich Bio-Oss®.

The emergence of xenografts like Bio Oss provides the ideal source of graft for implantologists. Various studies have revealed that all biopsies from graft site of implantation with Bio-Oss granules presented osteoconductive properties and were embedded in areas with vital bone with no substantial osteoclastic activity in human.^{12, 13} A valuable methodology for successful GBR and allowing the formation of new bone is a barrier membrane like Bio-Gide.¹³ The porcine collagenous Bio-Gide membrane is one of the most successful biodegradable membranes, with numerous merits. It has a bilayer structure with a compact and smooth side designed to prevent non-osteoblast interference opposite the bone defect, and the opposite side porous and rough to enable the attachment of osteoblasts bordering the bone defect.¹⁵

The bone substitutes instead of major autogeneous bone graft are also efficient enough for augmentation in sites where the implant surface is exposed.¹⁶ Therefore, even though augmentation procedures increase the cost of treatment, the incidence of implant failure and complications is comparably lower. The presented case unwaveringly proves that a proper surgical technique and use of bovine xenografts (Bio-Oss) and porcine collagen membrane (Bio-Gide) are one of the best tools for achieving success in bone augmentation in fresh extraction sockets with both horizontal and vertical bone defects in aesthetic zone.

Conclusion

GBR with immediate implant maximizes soft tissue healing preserving ridge envelope and gives essential esthetical outcome. In this case, vertical and horizontal ridge volumetric alterations positively were achieved by simultaneous GBR with immediate implant placement.

References

1. Buser D, Wittneben J, Bornstein MM, Grütter L, Chappuis V, Belser UC. Stability of contour augmentation and esthetic outcomes of implant-supported single crowns in the esthetic zone: 3-year results of a prospective study with early implant placement post-extraction. *Periodontol.* 2011;82(3):342-9.
2. Wang H-L, Kiyonobu K & Neiva R F. Socket Augmentation: Rationale and Technique. *Implant Dent.* 2004 ;13:286-96.
3. Becker J, Al-Nawas B, Klein MO, Schliephake H, Terheyden H, Schwarz F. Use of a new cross-linked collagen membrane for the treatment of dehiscence-type defects at titanium implants: a prospective, randomized-controlled double-blinded clinical multicenter study. *Clin Oral Implants Res.* 2009 Jul;20(7):742-9.
4. DMD, Michael & DMD, David & Salama, Maurice. Immediate Restoration of Single Teeth. *Journal of Oral and Maxillofacial Surgery - J ORAL MAXILLOFAC SURG.* 2005;63:17-18.
5. Esposito M, Grusovin MG, Coulthard P, Worthington HV. The efficacy of various bone augmentation procedures for dental implants: a Cochrane systematic review of randomized controlled clinical trials. *Int J Oral Maxillofac Implants.* 2006 Sep-Oct;21(5):696-710
6. Chen ST, Buser D. Clinical and esthetic outcomes of implants placed in postextraction sites. *Int J Oral Maxillofac Implants.* 2009;24 Suppl:186-217.
7. Elian N, Cho SC, Froum S, Smith RB, Tarnow DP. A simplified socket classification and repair technique. *Pract Proced Aesthet Dent.* 2007 Mar;19(2):99-104
8. Liu R, Yang Z, Tan J, Chen L, Liu H, Yang J. Immediate implant placement for a single anterior maxillary tooth with a facial bone wall defect: A prospective clinical study with a one-year follow-up period. *Clin Implant Dent Relat Res.* 2019 Dec;21(6):1164-1174.
9. Evans CD, Chen ST. *Clin Oral Implants Res.* 2008 (1);19(1):73-80.
10. Misch C.M. Autogenous bone: Is it still the gold standard? *Implant Dent.* 2010;19:361.
11. van den Bergh J.P., ten Bruggenkate C.M., Krekeler G., Tuinzing D.B. Sinus

- floor elevation and grafting with autogenous iliac crest bone. *Clin. Oral Implant. Res.* 1998;9:429-435.
12. Cypher T.J., Grossman J.P. Biological principles of bone graft healing. *J. Foot Ankle Surg.* 1996;35:413-417.
 13. Jensen SS, Terheyden H. Bone augmentation procedures in localized defects in the alveolar ridge: clinical results with different bone grafts and bone-substitute materials. *Int J Oral Maxillofac Implants.* 2009;24 Suppl:218-36.
 14. Jensen S., Bosshardt D., Buser D. Bone grafts and bone substitute materials. *Buser D Ed.* 2009; 20: 1-96.
 15. A.K. Schlegel, H. Möhler, F. Busch, A. Mehl, Preclinical and clinical studies of a collagen membrane (Bio-Gide®). *Biomaterials*, Volume 18, Issue 7, 1997, Pages 535-538
 16. Wilson TG Jr, Buser D. Advances in the use of guided tissue regeneration for localized ridge augmentation in combination with dental implants. *Tex Dent J.* 1994 Jul;111(7):5, 7-10.