

How to Cite:

Ahamed, S. M., Mathew, M., Bharat, T. A. A., Aggarwal, D., Agrawal, B. K., & Yadav, A. (2022). A case of iatrogenic thyroid storm. *International Journal of Health Sciences*, 6(S3), 4812-4817. <https://doi.org/10.53730/ijhs.v6nS3.6958>

A case of iatrogenic thyroid storm

Dr. Shoib Ahamed M.

Junior resident, Department of Medicine, M M Institute of Medical Sciences & Research, Maharishi Markandeshwar Deemed to be University, Mullana-133207, India

Dr. Manu Mathew

Senior Resident, Department of Medicine, M M Institute of Medical Sciences & Research, Maharishi Markandeshwar Deemed to be University, Mullana-133207, India

Dr. Tongar Aditi Ajay Bharat

Junior resident, Department of Medicine, M M Institute of Medical Sciences & Research, Maharishi Markandeshwar Deemed to be University, Mullana-133207, India

Dr. Dipti Aggarwal

Junior resident, Department of Medicine, M M Institute of Medical Sciences & Research, Maharishi Markandeshwar Deemed to be University, Mullana-133207, India

Dr. Bimal K. Agrawal

Professor, Department of Medicine, M M Institute of Medical Sciences & Research, Maharishi Markandeshwar Deemed to be University, Mullana-133207, India
Email: onlybimal@gmail.com

Dr. Ajit Yadav

Assistant professor, Department of Pulmonary Medicine, M M Institute of Medical Sciences & Research, Maharishi Markandeshwar Deemed to be University, Mullana-133207, India

Abstract--Thyroid storm is a rare entity and can be fatal if not properly managed on time. A 75 year old lady reported to the emergency room with agitation, restlessness, breathlessness. On further evaluation she was found to have atrial fibrillation with a heart rate of 180 beats per minute. She was carrying a blood report indicative of thyrotoxicosis, which was confirmed subsequently. The patient was diagnosed as a case of thyroid storm and managed accordingly. On taking the detail history it was found that the patient had palpitation since last 2 years and had been taking levothyroxine 75 microgram/day after consulting a paramedical health worker in a

hospital. The dose had been escalated to one and half tablet of 75mcg strength, in July 2021 as per the advice of the same health care worker after seeing the report. But the lab report of July 2021, the patient had, indicated thyrotoxicosis. Ideally the dose of levothyroxine should have been reduced or discontinued. It appears low TSH level of lab investigation report was misinterpreted as low thyroid level and the dose of levothyroxine had been increased. It is felt that there is a need to educate the paramedical health worker about the tricky issue of interpreting a thyroid test report, i.e low TSH in case thyrotoxicosis and high TSH in case of hypothyroidism!

Keywords---iatrogenic, thyroid storm, agitation, restlessness, breathlessness, levothyroxine.

Introduction

Thyroid storm is an acute life threatening clinical condition though rare, needs early diagnosis and treatment because of its substantial mortality rate. Thyroid storm is a complication of hyperthyroidism that presents with multi-organ-system involvement. The mortality associated with thyroid storm is estimated to be 10-25% (Pokhrel B et al, 2022). It occurs in about 1-2% of hyperthyroid patients. One out of every six patients of thyrotoxicosis was diagnosed with thyroid storm. Thyroid storm is associated with a twelve times increased mortality compared to thyrotoxicosis without any signs of storm.

Case Report

We are reporting a case of 75 year old female hailing from a rural place of Haryana state of India who presented to emergency department with complaints of palpitations for last several months and it had increased recently. She had also developed shortness of breath on exertion since past 1 month. As per her history which dates back to 2 years when she started feeling palpitations and tremors with no other history of co morbidities. She was started on oral tablet Levothyroxine 75mcg1 tablet/day empty stomach by a local health worker. Few of her thyroid profile reports available with her are as given in the Table-1. Since July 2021 the dose of Levothyroxine was increased to one & half table.i.e,112.5 mcg/day by the same local health worker after seeing the report. With the additional history of significant gradual weight loss of around 20 kilos in past 1 year and frequent complaints of loose stools she visited this hospital. In Emergency Room she was restless, disoriented, agitated and anxious, tremors on out stretched hands were noted, and pulse was irregularly irregular with extreme tachycardia (rate of 180 beats per minute).The ECG showed atrial fibrillation(Figure 1). Blood pressure was 140/80 mm of Hg and features of congestive heart failure (JVP-increased, mild pedal edema, B/L basal rales) were noted. There was no goiter. In view of disorientation, atrial fibrillation, congestive heart failure and thyroid function test showing thyrotoxicosis the patient fulfilled the Japanese thyroid association criteria (Pokhrel B et al, 2022) for thyroid storm. As per Burch-Wartofsky point scale (Burch, Henry B et al,1993)the patient scored 55, against 45 required to diagnose thyroid storm(agitation-10 points,

tachycardia >140/min -25 points, atrial fibrillation-10 points, moderate heart failure-10 points)

Patient was managed in medical ICU with intravenous metoprolol and tabletmethimazole40mg stat followed by 20mg twice a day. Injection hydrocortisone was given 100 mg iv twice daily and diuretics was given to relieve her of congestive symptoms. Subsequently oral propranolol was given 40mg qid. Over a period of 10 days during staying in hospital her tremors, palpitations, anxiety symptoms settled. Her pulse rate was irregular with a rate of 104-110 at the time of discharge. She was discharged on propranolol 40mg qid, methimazole 20mg bid. During her follow up on out-patient her symptoms have completely settled and her ECG was sinus rhythm with regular heart rate of 77/min (Fig 2) with atrial fibrillation completely resolved. Beta blocker and anti-thyroid drug doses were reduced accordingly.

Table 1
Thyroid function test values of the patient

	Normal values	July 2021	September 2021	December 2021
T3	0.6-1.81	5.97	3.91	5.58
T4	4.5-10.9	24.86	>30.80	33.0
TSH	0.35-5.5	0.005	<0.001	<0.0001

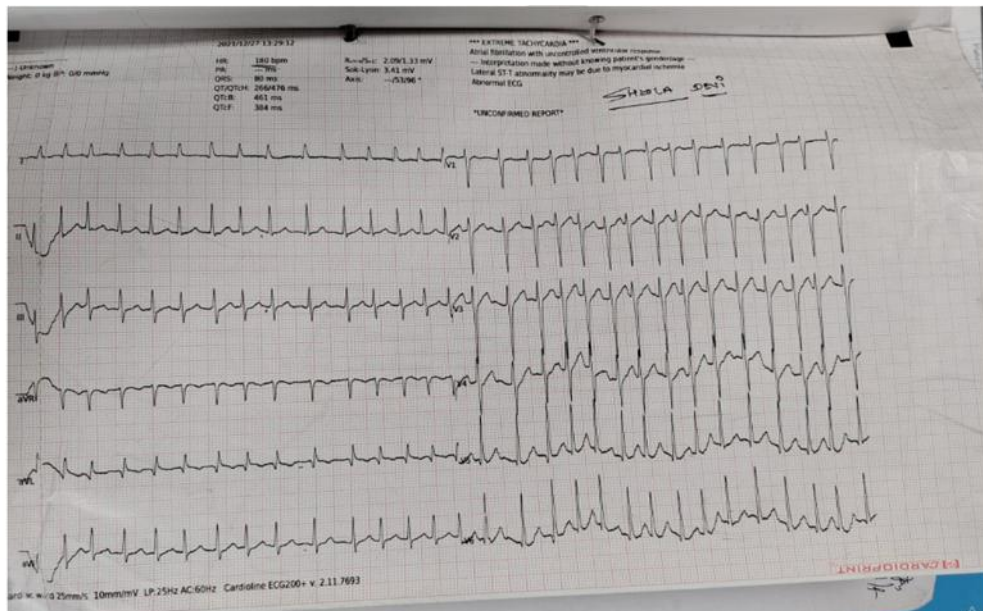


Figure 1. Image showing ECG of the patient on presentation

Findings: Atrial fibrillation-absent P waves with QRS complexes at irregular intervals, Rate -180/min.

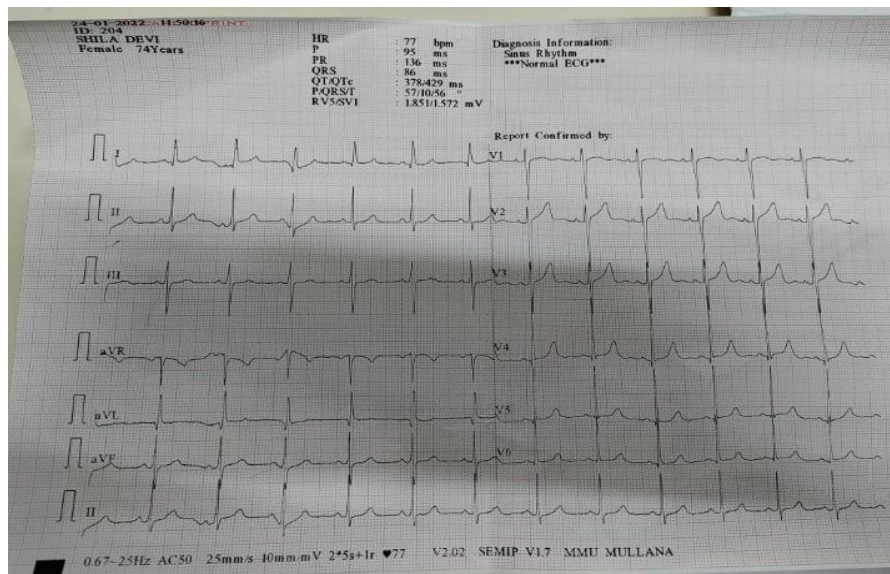


Figure 2. Image showing ECG on out-patient follow up

Findings: normal sinus rhythm with rate of 77/min

Discussion

Thyroid storm is an acute life-threatening condition requiring emergency treatment. This is often triggered by severe physical or mental stress, seen in thyrotoxic patients (Richard Carroll et al,2010). Various precipitating factors in hyperthyroid patients have been reported. Irregular use (Soo-Jee Yoon et al,2003) or discontinuation of anti-thyroid drugs (Donkor K et al,2016),pregnancy/delivery (Yudianto Budi Saroyo et al,2021), infection, cerebrovascular disease, diabetic ketoacidosis, intense exercise, severe emotional stress, ischemic heart disease, trauma (Douglas Yoshida,1996), adrenocortical insufficiency, non-thyroid surgery (Jae Hoon Lee, 2020), administration of iodinated contrast medium Radioiodine therapy, extraction of teeth and others (Miranda M. Broadney et al,2018). Various criteria have been proposed for the diagnosis of thyroid storm, based on signs and symptoms in hyperthyroid patients (BinduNayak et al,2006 and David A Wald et al,2003).

As per both Japanese criteria (Pokhrel B et al, 2022; Miranda M. Broadney et al,2018 and Takashi Akamizu et al, 2012) and Burch-Wartofsky criteria (Pokhrel B et al, 2022; Burch, Henry B et al,1993 and BinduNayak et al,2006) the patient was labelled definitive of thyroid storm. This patient's initial symptoms were suggestive of hyperthyroidism , the blood report of that time was not available. But she was advised by a local health worker to take levothyroxine based on the report. Her symptoms had not improved, rather it had worsened. The dose of levothyroxine had been increased in July 2021, after seeing the report. For economic reasons and scarce health resources, the patients consult paramedical health workers, lab technicians and even the local chemists. It appears low TSH was misinterpreted as hypothyroid state and thyroxin supplement was given. Graduating medical students are asked to interpret a thyroid report as a trick

question. The authors feel, it is important to educate the paramedical health care workers as well in this regard. She was managed and stabilized and now symptom free with atrial fibrillation reverted to sinus rhythm and congestive heart failure resolved. At present the patient is on maintenance therapy on regular follow up. Thyroid storm has been reported following radioactive iodine therapy for Graves's disease. There are case reports of factitious thyroid storm due to patient taking thyroid supplements to decrease body weight. To our knowledge such iatrogenic cause of thyroid storm has not been reported earlier.

Conclusion

The prime and important step in dealing with thyroid disorders is interpretation of the thyroid function test, any lacking in that can lead to mismanagement and sometimes a life threatening scenario as in the case of this patient. Ensuring a qualified interpretation of thyroid report is challenging especially in rural set up with scarce health care facility. The authors feel health education is the only way to solve the problem.

References

1. Pokhrel B, Aiman W, Bhusal K. Thyroid storm[Updated 2021 Jul 21]|Statpearls [Internet]. Treasure Island (FL): StatPearls Publishing; 2022.<https://www.ncbi.nlm.nih.gov/books/NBK448095>.
2. Donkor K. An Unusual Case of Thyroid Storm. Proceedings of UCLA Healthcare -(2016)-volume20.<https://proceedings.med.ucla.edu/wp-content/uploads/2016/03/A150709KD-1-VA-WH-edited.pdf> .
3. Richard Carroll, Glenn Matfin. Endocrine and metabolic emergencies: thyroid storm. *TherAdvEndocrinolMetab*. 2010 Jun; 1(3): 139–145.
4. Yudianto Budi Saroyo, Achmad Kemal Harzif ,Beryliana Maya Anisa, FistyanaElyaCharilda. Thyroid storm in the second stage of labour: a case report. *BMJ Case Rep* 2021; 14: e243159.
5. Soo-Jee Yoon ,Dol-Mi Kim, Jun-Uh Kim, Kyung-Wook Kim, Chul-Woo Ahn, Bong-Soo Cha, Sung-Kil Lim, Kyung-Rae Kim, Hyun-Chul Lee, Kap-Bum Huh. A case of thyroid storm due to thyrotoxicosis factitia. *Yonsei Med J* 2003; 44(2): 351-354.
6. Douglas Yoshida. Thyroid storm precipitated by trauma. *The Journal of emergency medicine* 1996 volume14(6): pg 697-701.
7. Jae Hoon Lee. Thyroid storm after coronary artery bypass surgery: a case report. *Journal of Cardiothoracic Surgery*. 2020 Dec;15(1):1-5. doi:10.1186/s13019-020-1044-2.
8. Burch, Henry B, Wartofsky Leonard. Life-threatening thyrotoxicosis: thyroid storm. *Endocrinology and metabolism clinics of North America*. 1993 Jun 1;22(2):263-77.
9. Bindu Nayak, Kenneth Burman. Thyrotoxicosis and thyroid storm. *EndocrinolMetabClin N Am* 2006 Dec 1;35(4):663-86.
10. Miranda M. Broadney, Priya Vaidyanatha, Bruce L. Klein, Joanna S. Cohen. Management of endocrine emergencies in pediatric endocrinology 2018 (*Chapter 37*) (pp. 825-846).
11. Takashi Akamizu, Tetsurou Satoh, Osamu Isozaki, Atsushi Suzuki, Shu Wakino, TadaoIburi, Kumiko Tsuboi, Tsuyoshi Monden, Tsuyoshi Kouki,

- Hajime Otani, Satoshi Teramukai, Ritei Uehara, Yosikazu Nakamura, Masaki Nagai, and Masatomo Mori. Diagnostic criteria, clinical features, and incidence of thyroid storm based on nationwide surveys. *Thyroid*. 2012 Jul 1;22(7):661-79. doi:10.1089/thy.2011.0334.
12. Takashi akamizu. Thyroid storm: a Japanese perspective. *Thyroid*. 2018 Jan;28(1):32-40.
 13. David A Wald; Allison Silver. Cardiovascular manifestations of thyroid storm: a case report. *The Journal of emergency medicine*. 2003 Jul 1;25(1):23-8.