

How to Cite:

Arora, V., Jitender, J., Singh, R., & Gandhi, K. (2022). Assessment of wound healing using Nano-crystalline silver membrane placed following periodontal flap surgery. *International Journal of Health Sciences*, 6(S1), 9335–9341. <https://doi.org/10.53730/ijhs.v6nS1.7115>

Assessment of wound healing using Nano-crystalline silver membrane placed following periodontal flap surgery

Dr. Varun Arora

MDS Periodontics & Implantology, Practising dentist at Asian Dental Care, Aggarsen Chowk Kurukshetra, Haryana
Email: varunarora19852002@gmail.com

Dr. Jitender

Oral and maxillofacial surgeon, Senior resident in Kalpana Chawla Medical College and Hospital, Karnal, Haryana
Email: jitu692@gmail.com

Dr. Roohi Singh

BDS, Panjab University, Chandigarh, India
Corresponding author email: roohisingh26@gmail.com

Dr. Kanica Gandhi

PG student Department of Prosthodontics, Crown Bridge Implantology at MM College Of Dental Sciences & Research, MMU, Mullana, Haryana
Email: gandhikanica@gmail.com

Abstract--Background: Nanomaterials are widely explored in Periodontics, as well as controlled drug release in forms of hollow spheres, core-shell, nanotubes and other active components. The present study was conducted to assess wound healing using Nano-crystalline silver membrane placed following periodontal flap surgery. Materials & Methods: 60 patients diagnosed with chronic periodontitis of both genders were divided into 2 groups of 30 each. Group I received a nano-crystalline silver dressing and group II received non-eugenol dressing. Flap surgery in each patient was carried out. Parameters such as wound healing index, microbiological analysis and vascular endothelial growth factor (VEGF) were recorded at the 7th and 14th day postoperatively. Results: Patients in group I received a nano-crystalline silver dressing and in group II, non-eugenol dressing. Group I had 14 males and 16 females and group II had 12 males and 18 females. The mean healing index on 7th day was 3.75 and 2.28 in group I and II and 4.12 and 3.14 in in group I and II on 14th day respectively. The difference was significant (P< 0.05). CFU/ml (X10⁶) pre- operatively and post- operatively was 3.4 and 1.6 and 1.5 and 1.8

in group I and II respectively. VEGF pre- operatively was 0.021 and 0.023 and post- operatively was 0.032 and 0.024 in group I and II respectively. The difference was significant ($P < 0.05$). Conclusion: Nano-crystalline silver particles as a periodontal dressing with a good antibacterial effect on the gingival surface promoting early healing post- operatively.

Keywords---Antibacterial, Nano-crystalline silver particles, gingival surface.

Introduction

Nanomaterials are widely explored in Periodontics, as well as controlled drug release in forms of hollow spheres, core-shell, nanotubes and other active components. Periodontal disease is an inflammatory and infectious. Disease of gingiva that leads to the breakdown of periodontal tissues. Its severe form results in loss of alveolar bone with eventual loss of the tooth. The current evidence on etiopathogenesis suggests that the major risk factors are the bacterial aggression and the host response influenced by behavioral and systemic risk factor.¹

Periodontal dressing is a commonly used dressing placed following various periodontal surgical procedures including gingivectomies, flap procedures, crown lengthening, mucogingival procedure, and most commonly after periodontal regeneration.² These dressings help in holding the flap or graft in place; protecting, shaping, or molding the newly formed tissue; minimizing the experience of postoperative pain, infection, and hemorrhage; protecting the surgical site from trauma from mechanical insults like during eating and drinking, and also, supporting the mobile teeth during the healing process.³

Silver nanoparticles (NPs) are being increasingly used nowadays as wound dressings, contraceptive devices, surgical instruments, and bone prostheses.⁴ There is increasing literature to support that silver NPs can promote wound healing through anti-inflammatory properties. Furthermore, the levels of pro-inflammatory markers have been found to be significantly reduced in animals treated with nAg,⁵ The present study was conducted to assess wound healing using Nano-crystalline silver membrane placed following periodontal flap surgery.

Materials & Methods

The present study comprised of 60 patients diagnosed with chronic periodontitis of both genders. The consent was obtained from all enrolled patients. Data such as name, age, gender etc. was recorded. Patients were divided into 2 groups of 30 each. Group I received a nano-crystalline silver dressing and group II received non-eugenol dressing. Flap surgery in each patient was carried out. Parameters such as wound healing index were recorded at the 7th and 14th day postoperatively. The microbiological analysis and vascular endothelial growth factor (VEGF) levels were evaluated at baseline and 7th day postoperatively.

Healing Index (Landry, Turnbull and Howley Healing Index) was recorded as very poor (2 or more signs present): $\geq 50\%$ of red gingiva, poor: $\geq 50\%$ of red gingiva, incision margins not epithelialized with exposed connective tissue, good: 25-50% of red gingiva, incision margins without exposed connective tissue, very good: 25% of red gingiva, incision margins without exposed connective tissue, excellent: All pink tissue, incision margins without exposed connective tissue, absence of bleeding on palpation, granulation tissue and suppuration was followed. Data thus obtained were subjected to statistical analysis. P value < 0.05 was considered significant.

Results

Table I
Distribution of patients

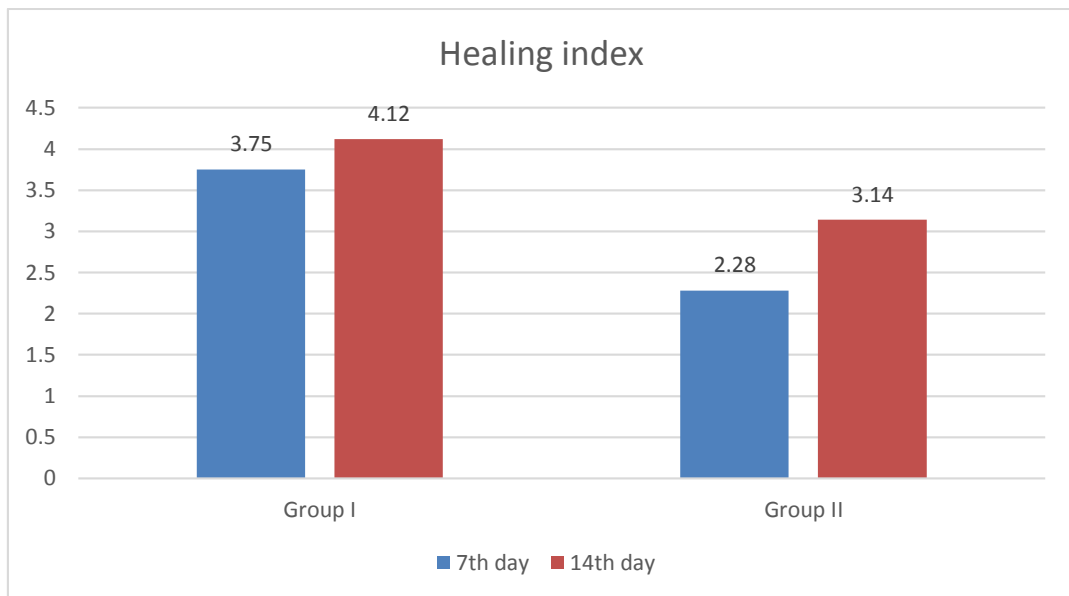
Groups	Group I	Group II
Method	nano-crystalline silver dressing	non-eugenol dressing
M:F	14:16	12:18

Table I shows that patients in group I received a nano-crystalline silver dressing and in group II, non-eugenol dressing. Group I had 14 males and 16 females and group II had 12 males and 18 females.

Table II
Evaluation of healing index

Groups	7 th day	14 th day	P value
Group I	3.75	4.12	0.02
Group II	2.28	3.14	0.03

Table II, graph I shows that mean healing index on 7th day was 3.75 and 2.28 in group I and II and 4.12 and 3.14 in in group I and II on 14th day respectively. The difference was significant ($P < 0.05$).

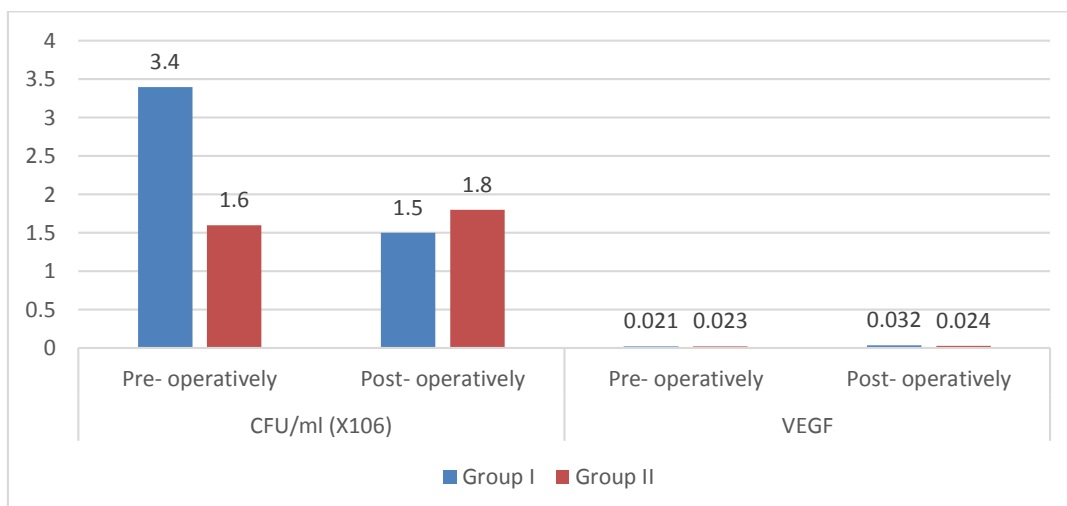


Graph I. Evaluation of healing index

Table III
Evaluation of CFU/ml and VEGF

Parameters	Variables	Group I	Group II	P value
CFU/ml (X10 ⁶)	Pre- operatively	3.4	1.6	0.92
	Post- operatively	1.5	1.8	
VEGF	Pre- operatively	0.021	0.023	0.05
	Post- operatively	0.032	0.024	

Table III, graph II shows that CFU/ml (X10⁶) pre- operatively and post- operatively was 3.4 and 1.6 and 1.5 and 1.8 in group I and II respectively. VEGF pre- operatively was 0.021 and 0.023 and post- operatively was 0.032 and 0.024 in group I and II respectively. The difference was significant (P< 0.05).



Graph II. Evaluation of CFU/ml and VEGF

Discussion

A number of clinical trials have reported plaque accumulation beneath these dressings, leading to inflammation in the tissues and transient bacteremia. This encouraged the invention of drug-loaded dressings, which act as a barrier to microorganisms when applied on a wound, thus stimulating the wound-healing environment by preventing secondary infections.⁶ Various agents have been tested such as chlorhexidine digluconate salts, zinc bacitracin, and tetracycline. Among the different antimicrobial agents, silver has been used widely due to many benefits, including multilevel antibacterial effect on cells with low systemic toxicity. It also reduces the chances of developing resistance and is effective against multidrug-resistant organisms.⁷ Nanoparticles are clusters of atoms in the size range of 1- 100 nm. Silver nanoparticles have the ability to anchor to the bacterial cell wall and subsequently penetrate it, thereby causing structural changes in cell wall affecting its permeability and hence, death of the cell.⁸ The antimicrobial efficacy of 0.02mg/gm silver nanoparticles gel against *P. gingivalis* is 3.125µg/ml and 6.25µg/ml for *A. actinomycetemcomitans* making it suitable option as nano-medicine.⁹ The present study was conducted to assess wound healing using Nano-crystalline silver membrane placed following periodontal flap surgery.

We found that patients in group I received a nano-crystalline silver dressing and in group II, non-eugenol dressing. Group I had 14 males and 16 females and group II had 12 males and 18 females. Aggarwal et al¹⁰ found that there was a significant reduction in CFU/ml post-surgery in test group as compared to pre-surgery. No evident change was seen between pre-surgery and post-surgery mean values in the control group. Gram staining revealed that pre-surgery plaque demonstrated predominant Gram-positive facultative anaerobes with 85.7% in test group and 80.9% in control group. Gram-negative facultative anaerobes dominated in post-surgery samples in both the groups (76.1% in test group and 66.6% in control group). There were some cases wherein no growth was seen on the agar plates, thereby labeled as no growth. The mean levels of VEGF-A were

comparable in both the groups at baseline ($P = 0.92$). The post-surgery levels of VEGF-A showed a highly significant difference between test group (0.0342 ng/ μ l) and control group (0.0260 ng/ μ l). Intragroup evaluation showed a highly significant increase in the VEGF-A levels at 7th day post-surgery from baseline in the test group ($P = 0.001$), while no evident change was seen post-surgery in the control group ($P = 0.52$).

We observed that mean healing index on 7th day was 3.75 and 2.28 in group I and II and 4.12 and 3.14 in in group I and II on 14th day respectively. Kadam et al¹¹ assessed the efficacy of subgingival local drug delivery of silver nanoparticles in comparison with tetracycline in chronic periodontitis. They evaluated effect of silver nanoparticles and tetracycline gel in chronic periodontitis, patients which were divided in different: Group A: Scaling and root planning (SRP) with subgingival delivery of silver nanoparticles gel, Group B: SRP with subgingival delivery of tetracycline gel and Group C: SRP alone. The other data recorded was Plaque Index (PI), Gingival Index (GI), Probing Pocket Depth (PPD) and Clinical Attachment Level (CAL) at baseline (just before placement of gel), 1 month and 3 months of application of gel. Microbiological evaluation (Colony Forming Units, CFU) were recorded at baseline and after 3 months. The results showed that the use of silver nanoparticles delivery after SRP was as efficacious as tetracycline subgingival delivery to treat chronic periodontitis patients. All the clinical as well as microbiological parameters showed statistically significant difference from baseline to 3 months in all the groups.

We found that CFU/ml ($\times 10^6$) pre- operatively and post- operatively was 3.4 and 1.6 and 1.5 and 1.8 in group I and II respectively. VEGF pre- operatively was 0.021 and 0.023 and post- operatively was 0.032 and 0.024 in group I and II respectively. Masurkar SA et al¹² concluded that silver nanoparticles can enhance quorum quenching activity against *Staphylococcus aureus* and prevent biofilm formation.

Conclusion

Authors found that nano-crystalline silver particles as a periodontal dressing with a good antibacterial effect on the gingival surface promoting early healing post-operatively.

References

1. Rai M, Yadav A, Gade A. Silver nanoparticles as a new generation of antimicrobials. *Biotechnol Adv.* 2009;27:76–83.
2. Rigo C, Ferroni L, Tocco I, Roman M, Munivrana I, Gardin C, et al. Active silver nanoparticles for wound healing. *Int J Mol Sci.* 2013;14:4817–40.
3. Lin YH, Hsu WS, Chung WY, Ko TH, Lin JH. Silver-based wound dressings reduce bacterial burden and promote wound healing. *Int Wound J.* 2016;13:505–11.
4. Sirisha P, Gayathri GV, Dhoom SM, Amulya KS. Antimicrobial effect of silver nanoparticles synthesised with *Ocimum sanctum* leaf extract on periodontal pathogens. *J Oral Health Dent Sci.* 2017;1:1–7.

5. Habiboallah G, Mahdi Z, Majid Z, Nasroallah S, Taghavi AM, Forouzanfar A, et al. Enhancement of gingival wound healing by local application of silver nanoparticles periodontal dressing following surgery: A histological assessment in animal model. *Mod Res Inflamm*. 2014;3:128–38.
6. Nissen NN, Polverini PJ, Koch AE, Volin MV, Gamelli RL, DiPietro LA. Vascular endothelial growth factor mediates angiogenic activity during the proliferative phase of wound healing. *Am J Pathol*. 1998;152:1445–52.
7. Shah JM, Omar E, Pai DR, Sood S. Cellular events and biomarkers of wound healing. *Indian J Plast Surg*. 2012;45:220–8.
8. Yamakawa S, Hayashida K. Advances in surgical applications of growth factors for wound healing. *Burns Trauma*. 2019;7:10.
9. Eming SA, Krieg T, Davidson JM. Inflammation in wound repair: Molecular and cellular mechanisms. *J Invest Dermatol*. 2007;127:514–25.
10. Aggarwal K, Gupta S, Sood S, Bhardwaj SB, Prashar S, Jain A. Effect of nano-crystalline silver membrane on early wound healing after periodontal surgery: A comparative randomized study. *Journal of Indian Society of Periodontology*. 2021 Nov;25(6):504.
11. Kadam P, Mahale S, Sonar P, Chaudhari D, Shimpi S, Kathurwar A. Efficacy of silver nanoparticles in chronic periodontitis patients: A clinico-microbiological study. *Iberoamerican J Med*. 2020;2:142–7.
12. Masurkar SA, Chaudhari PR, Shidore VB, Kamble SP. Effect of biologically synthesised silver nanoparticles on *Staphylococcus aureus* biofilm quenching and prevention of biofilm formation. *IET Nanobiotechnol*. 2012;6(3):110-4.