

How to Cite:

Shawky, K., Marzouk, A. A.-E., El-Baz, W. A., Abd-ElHaseeb, A. R., Elsayed, A. M. A., & Abdelmawla, M. H. (2022). Superficial femoral artery chronic total occlusion crossing strategies. *International Journal of Health Sciences*, 6(S4), 2438–2453. <https://doi.org/10.53730/ijhs.v6nS4.7163>

Superficial femoral artery chronic total occlusion crossing strategies

Khaled Shawky

Vascular Surgery Unit, General Surgery Department, Faculty of Medicine, Beni-suef University, Egypt, M.D.

Email: khaledshawky74@gmail.com

Alaa Abd-ElHalim Marzouk

Vascular Surgery Unit, General Surgery Department, Faculty of Medicine, Beni-suef University, Egypt, M.D.

Email: alaa8abdelhalim@yahoo.com

Waleed Ali El-Baz

Vascular Surgery Unit, General Surgery Department, Faculty of Medicine, Beni-suef University, Egypt, M.D.

Email: waliedbaz@hotmail.com

Ayman Refaat Abd-ElHaseeb

Vascular Surgery Unit, General Surgery Department, Faculty of Medicine, Beni-suef University, Egypt, M.D.

Email: aymanrefaat68@yahoo.com

Ahmed Mohamed Abdelalim Elsayed

Vascular Surgery Unit, General Surgery Department, Faculty of Medicine, Helwan University, Egypt, M.D.

Corresponding author email: ahmed.abdelalim@med.helwan.edu.eg.com

Mohamed H. Abdelmawla

Vascular Surgery Unit, General Surgery Department, Faculty of Medicine, Beni-suef University, Egypt, M.D.

Email: mohamedhasan8134@gmail.com

Abstract---Objectives: Superficial femoral artery (SFA) endovascular intervention procedures are one of the most common peripheral artery interventions (PAI) in the lower extremities around the world. Chronic total occlusions (CTO) are extremely common in this vascular bed, accounting for approximately 40–50% of all lesions treated. One of the most crucial decisions an operator must make for a good chronic total occlusion (CTO) recanalization is selecting the right catheter vascular access site. Methods: A prospective, cohort, study conducted on 30

patients to evaluate the safety and efficacy of different strategies for crossing the chronic total occlusion of superficial femoral artery. Results: There was statistically significant difference found between crossing techniques regarding DM and combined DM and dyslipidemia. Conclusion: Correlation of CTO classification with larger sample size may show importance and improve crossing strategies.

Keywords---Femoral artery occlusion, CTO, crossing strategies.

Introduction

Superficial femoral artery (SFA) Endovascular intervention procedures are one of the most common peripheral artery interventions (PAI) in the lower extremities around the world. CTOs are common in this vascular bed, accounting for approximately 40–50% of all lesions treated ⁽¹⁾. As a result, good PAI interventional practice requires a systematic and step-by-step approach to such lesions, as well as experience with various PAI tools and their attributes ⁽²⁾.

Choosing the right vascular access site is one of the most critical decisions the operator must make for effective CTO recanalization. The ipsilateral or contralateral side of the lesion may be used to gain vascular entry. For the operator, contralateral access may be more convenient, while antegrade access may improve the ability to advance catheters. Because of operator comfort, the antegrade method is more widely used. The retrograde solution, on the other hand, provides an alternate technique if the guide wire does not reach the CTO because penetration of the distal cap is normally easier than the proximal cap ⁽³⁾. To allow antegrade passage of the guide wire into the true lumen, a balloon may be inflated in a retrograde dissection plane communicating with the distal true lumen from a retrograde approach. Controlled antegrade-retrograde dissection/reentry, or CART, is the name for this procedure. The reverse CART technique is used to dilate the antegrade dissection space unlike the CART technique ⁽⁴⁾.

If the antegrade and retrograde wiring approaches fail, the SAFARI (subintimal arterial flossing with antegrade-retrograde intervention) technique may be used to recanalize the lesion ⁽⁵⁾. Traditionally the intraluminal (IL) approach has been the standard technique and carries about 20% failure rate primarily in CTO's prompting the development of various crossing techniques such as subintimal recanalization ⁽⁶⁾. The subintimal approach allows to cross difficult totally occluded lesions to be managed via percutaneous endovascular techniques, thus avoiding the increased risk and cost associated with surgical revascularization ⁽⁷⁾. The various combinations of caps have been assigned a number from I to IV, known as C-TOP classification, with higher numbers reflecting a hypothetical rise in lesion complexity that would make crossing these lesions from a conventional antegrade method extremely difficult. (Fig. 1). Type I has concave proximal and distal caps, type II has a concave proximal and a convex distal CTO cap, type III has convex proximal and concave distal CTO caps, and type IV has convex proximal and distal caps when defining the caps from an antegrade approach.

The length of the occlusions, the amount of calcium, and the presence and condition of collateral arteries between the proximal and distal CTO caps are not included in the classification. ⁽⁸⁾.

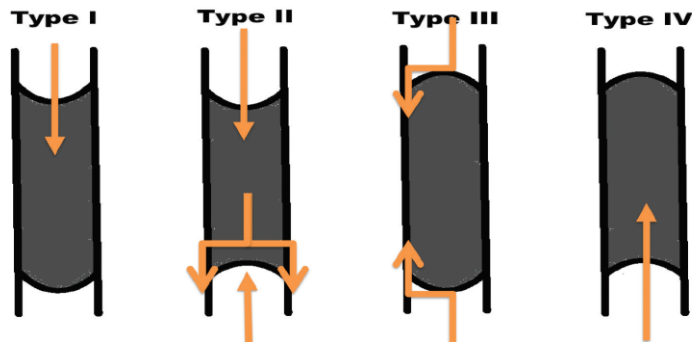


Fig 1: C-TOP classification

Patients and Methods

The study was a prospective cohort study in which 30 patients with superficial femoral artery chronic total occlusion were included from vascular units in Beni-Suef and 6th of October University Hospitals.

Inclusion Criteria: patients with atherosclerotic superficial femoral artery chronic total occlusion who fulfilled the following criteria. Adult patients aged > 18 years old. Both sexes were included.

Exclusion criteria: Patients with elevated s. creatinine. Patient with history of major allergic reaction to IV radio contrast agents. Patients unwilling to undergo the procedure. Patients unfit for the procedure.

The following data were collected preoperatively: Demographic characteristics of the patients Medical history

Diabetes, hypertension, dyslipidemia, cardiac conditions **Complaints as:** Rest pain; unhealed ulcer; Gangrene; or Sever claudication despite best medical treatment for at least 6 months (failed medical treatment).

Then Physical examination was done

Investigations was done in form of Laboratories: CBC. Coagulation profile. S. Creatinine, urea **Imaging:** Arterial duplex. CT angiography.

CTOP Classification: Information was gathered to compare CTO cap morphology as described by the CTOP classification system with crossing performance based on the number and position of arterial access sites. At least two physicians looked at each picture. The presence of the proximal and distal CTO caps during angiographic imaging loops was used to determine their morphology (concave or convex) a cranial-caudal direction.

A- The Procedure : At baseline and after the intervention, an angiogram was obtained in at least two orthogonal views. To detect signs of distal embolization, the distal runoff vessels were examined before intervention and

on the completion angiogram. We use various methods to carry out the operation:

- I. **Antegrade access:** A 6 French sheath was inserted into CFA. Diagnostic angiography was performed through the sheath. A hydrophilic-coated, 0.035-inch guide wire was passed. Then, 5000 units of heparin were administered through the side port of the introducer sheath. In flush SFA occlusion, the access was contralateral crossover. Time for antegrade trials is 15-20 minutes then proceed to retrograde. No reentry devices used.
- II. **Retrograde access (pedal or posterior tibial access):** A 4 French sheath was inserted into dorsalis pedis or posterior tibial artery either close or open. A hydrophilic tip-coated, 0.018-inch guide wire was passed. (**Fig. 2**).

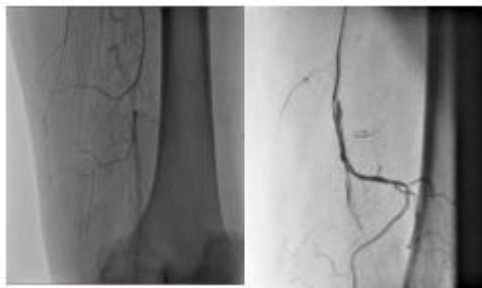

Fig 2: Retrograde access.

- III. **The “SAFARI” technique:** In all patients antegrade subintimal recanalization was attempted using Bolia et al's technique with slight modifications. If reentry into the distal true lumen fails, a catheter from the antegrade approach is left in the subintimal space, and attention is focused on directly accessing the distal target artery's true lumen. Direct puncture of the popliteal artery is performed and has Recanalization of intraluminal and subintimal arteries has been identified. The anterior tibial, posterior tibial, or dorsalis pedis arteries are punctured directly under ultrasound or fluoroscopic guidance. Retrograde subintimal recanalization is performed when access is gained inside the true lumen of the distal goal artery. The retrograde dissection is continued until the antegrade approach enters the subintimal space or the proximal true lumen is reached. The guide wire is then inserted into the antegrade catheter or sheath to create a "flossing"-type guide wire over which balloon angioplasty can be performed. (**Fig. 3**).

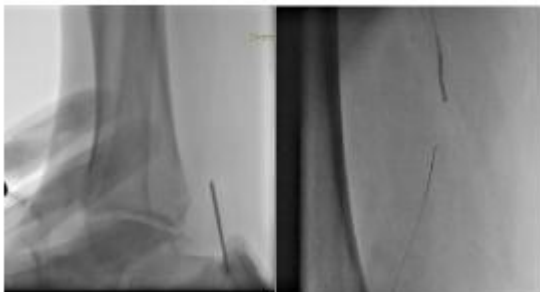


Fig 3: SAFARI technique

- IV. The “Rendezvous” technique:** A low-profile retrograde balloon [e.g., Pacific (Medtronic)] was advanced into the true lumen inside the CTO lesion for the rendezvous technique. In order to guide the antegrade wire to the true lumen, the true lumen was expanded by inflating the retrograde balloon catheter. With wire inside, the antegrade balloon is advanced through subintimal space. As a result, The antegrade guidewire was easily passed through the dissection, connected to the retrograde balloon, and reached the true lumen at the distal end. An antegrade technique may be used to perform sequential procedures, as well as stent placement if necessary. **(Fig. 4).**

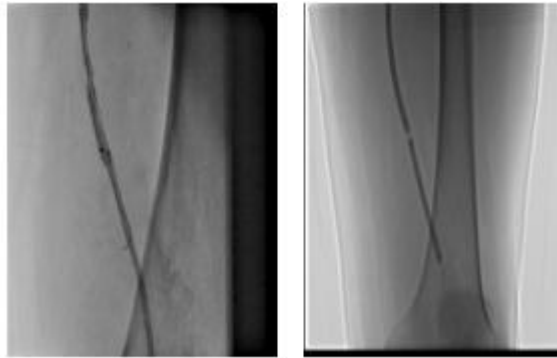


Fig 4: Rendezvous technique.

Anticoagulation is performed with intraarterial heparin to achieve an activated clotting time of 250–300 seconds after active passage of the guide wire in the subintimal space and placement of the flossing wire. Only heparin is used during the operation. When the process is over, When the triggered clotting time is less than 180 seconds and hemostasis is achieved with manual compression, the femoral artery sheath or catheter is removed.

Finally, antegrade balloon angioplasty and stenting could be performed sequentially. The retrograde wire is more likely to be used in the distal part of an occlusive lesion since the plaque there is less fibrotic and calcified. advanced intraluminally.

V. Procedural assessment:

The result was considered technically successful if the wire and catheter passed through the CTO. A clinically successful procedure was defined as the ability to dilate the lesion with balloon and/or deploy the stent if needed, and healed foot lesion

VI. Follow up

All patients were followed for 1week after the intervention for hematoma, then monthly for 6 months clinical and by Duplex; angiography was used if needed. Complications and interventions were recorded for this period.

B- Outcome Measures:

Procedure-related complications were the safety endpoint, while procedure success (successful access and 30 percent residual stenosis by quantitative

angiography with proof of at least 1 patent tibial artery to the foot) was the efficacy endpoint. Immediate hemodynamic success was another efficacy result (restored pulse), defined as (ABI) improvement ≥ 0.15 compared to baseline except for patients with falsely elevated ABI (defined as $ABI \geq 1.3$).

Primary patency (persistent patency without recurrent symptoms despite worsening ABIs and a dampened Doppler waveform pattern due to recurrent disease) and assisted primary patency (reintervention for restenosis, reocclusion, or a new lesion in the treated leg) (persistent patency without recurrent symptoms despite worsening ABIs and a dampened Doppler waveform pattern due to recurrent disease) used to follow-up outcomes. For patients with tissue loss, clinical improvement was described as a 2 Rutherford category improvement, an ABI increase of at least 0.15, and wound healing in 4 months after the index intervention. Clinical progress with or without target vessel revascularization or major amputation was described as sustained clinical success (limb loss above the ankle).

We confirm that the present study run in concordance with international ethical standards and applicable local regulatory guidelines. Written informed consents obtained from all patients prior to study's enrollment. The study's protocol was reviewed and approved by ethics committee or audit department of general and vascular surgery, Faculty of Medicine, Beni-Suef University.

Results

The mean age of the included patients was 57.86 ± 9.6 years old and the majority of patients were males (56.7%) and female were (43.3%) (Fig. 5). 76.7% of patients were smokers (Fig. 6)

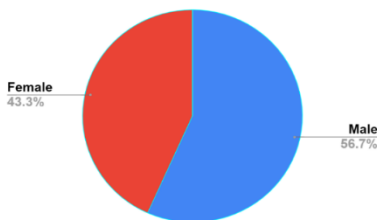

Fig 5: Gender distribution

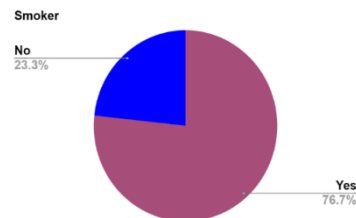


Fig 6: Smoking distribution.

The medical history of patients. The majority of patients were diabetic (80%), hypertensive (70%), and dyslipidemia (63.3%). In addition, 23.3% of the patients had history of IHD (Fig. 7).

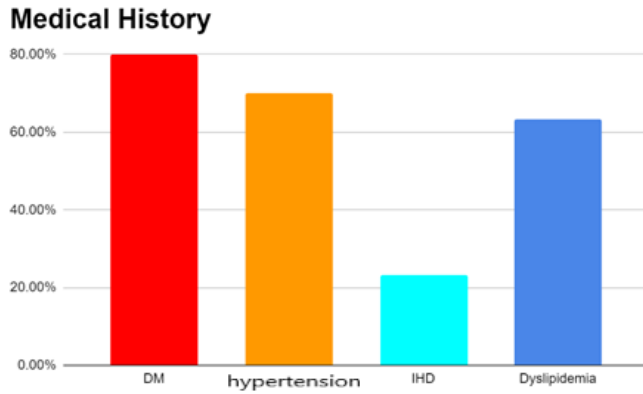


Fig 7: Medical history of patients.

The complaint of the patients. The most common complaints were rest pain, incapacitating claudication and infection (20% each), followed by unhealed ulcer (16.67%) then dry gangrene (13.3%) (Fig. 8).

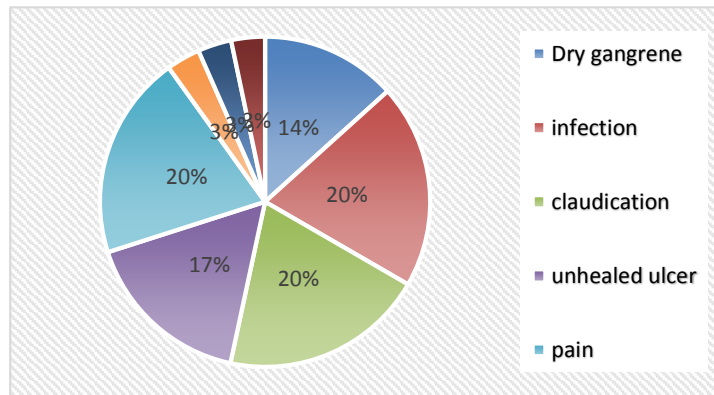


Fig 8: Complaints of patients.

Table 1
Imaging Findings of site of lesion

Variables	Patients (N =30)
Duplex	
- Distal SFA	1 (3.3%)
- Distal SFA, iliac	1 (6.7%)
- Distal SFA, infrapopliteal disease	2 (6.7%)
- Flush SFA	1 (3.3%)
- Long segment occlusion SFA	9 (30%)
- Lower SFA	2 (6.7%)
- Mid-segment occlusion SFA	11 (36.7%)
- Proximal SFA	3 (10%)
CTA	
- Distal SFA	3 (10%)

- Flush SFA	5 (16.7%)
- Long segment occlusion SFA	8 (26.7%)
- Lower SFA	2 (6.7%)
- Mid-segment occlusion SFA	11 (36.7%)
- Occluded iliac stent, distal occlusion SFA	1 (10%)

Table 1 shows imaging findings of site of lesion. The most common findings on both Duplex and CTA imaging was mid-segment occluded SFA (36.7%), followed by long-segment SFA. Notably, 5 patients (16.7%) showed flush SFA in CTA.

C-TOP classification of patients according to angiographic pictures. The most common type was C-TOP II (33.3%), followed by type IV (30%), and II (20%) (Fig. 9).

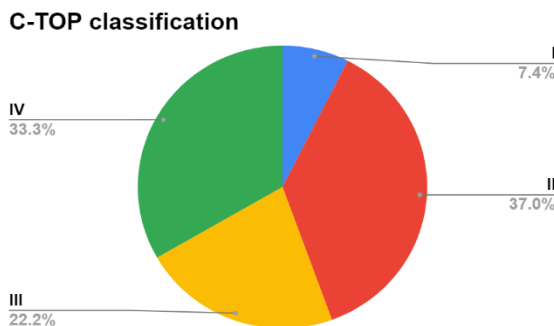


Fig 9: C-TOP classification of patients according to angiography.

Table 2
Crossing techniques

Variables	Patients (N =30)
Crossing techniques	
- Antegrade	21 (70%)
- Cross-over	4 (13.3%)
- Rendezvous	2 (3.3%)
- SAFARI	2 (6.7%)
- Retrograde	1 (3.3%)

Table 2 shows crossing techniques. The most common crossing technique was antegrade (70%) with crossing either intraluminal or subintimal. Cross-over (13.3%) mostly for flush SFA occlusion to gain more working distance, one patient of cross over group, the access selected due to presence of iliac lesion. Retrograde crossing (3.3%) was utilized after failure of antegrade crossing of proximal cap. Two patients underwent SAFARI technique with crossing lesion from distal cap then wire flossing. Two patients underwent Rendezvous technique as crossing was not be able from either proximal or distal cap alone. Two balloons were inserted from proximal and distal accesses.

The most commonly utilized endovascular technique was balloon angioplasty and stenting in 23 patients (77.7%) then balloon angioplasty in 7 patients (23%) (Fig. 10).

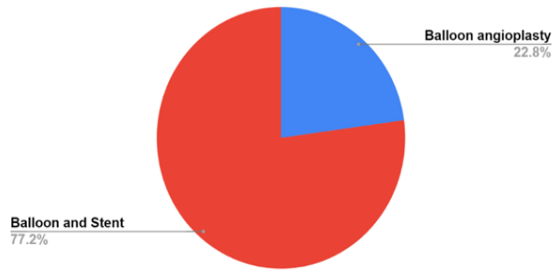


Fig 10: Endovascular techniques

Restored pulses. 36.7% of the patients had restored PTA, 10% had restored ATA, 30% had restored ATA & PTA, and 16.7% had resorted DPA & PTA (Fig. 11).

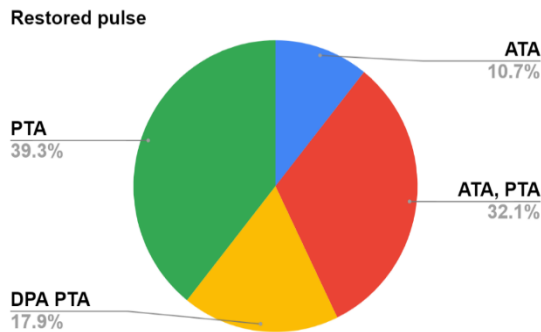


Fig 11: Restored pulses

Table 3 shows the association between diabetes and dyslipidemia and crossing techniques. There were no statistically significant differences between crossing strategies and dyslipidemia. But, there was statistically significant difference found between crossing techniques regarding DM and combined DM and dyslipidemia.

Table 3
Association between Crossing Techniques diabetes and dyslipidemia

Variables	Antegrade (N =21)	Retrograde (N =5)	Cross over (N =4)	P-value
DM (N= 17)	15 (75%)	1 (20%)	1 (25%)	0.044
Dyslipidemia (N=4)	2 (10%)	-	2 (50%)	0.058
Dyslipidemia, DM (N=5)	3 (15%)	3 (60%)	-	0.040

*Data are presented as number (%).

Table 4 shows the association between crossing technique and C-TOP. There was statistically insignificant difference between crossing strategies and C-TOP.

Table 4
Association between crossing technique and C-TOP

Variables	Antegrade (N =21)	Retrograde (N =5)	Crossover (N =4)	P-value
- I	1 (4.7%)	-	1 (25%)	0.267
- II	10 (47.6%)	1 (20%)	2 (50%)	0.512
- III	4 (19.1%)	1 (20%)	1 (24%)	0.963
- IV	6 (28.6%)	3 (60%)	-	0.143

*Data are presented as number (%).

Table 5 shows complications of the included patients. The most common complication was ATA perforation (13.3%), followed by occluded ATA (6.7%).

Table 5
Complications occurred

Variables	Patients (N =30)
Complications	
- ATA dissection	1 (3.3%)
- ATA perforation	4 (13.3%)
- distal SFA perforation	1 (3.3%)
- lost peroneal	1 (3.3%)
- lower pop thrombosis pushed to peroneal	1 (3.3%)
- Lt iliac dissection stented	1 (3.3%)
- Occluded ATA	2 (6.7%)
- PTA perforation	1 (3.3%)
- SFA perforation	1 (3.3%)

*Data are presented as mean \pm SD, median (IQR), or number (%).

Discussion

The most common cause of symptomatic PAD is superficial femoral artery disease, which may progress from lifestyle-limiting claudication to critical limb ischemia and limb loss. CTO of the lower extremities, which affects 40% of symptomatic PAD patients, is a difficult subset of PAD to treat effectively with percutaneous strategies. ⁽⁹⁾.

The inability to cross a CTO is the most common cause of revascularization failure, which is linked to an increased risk of complications. In most prospective registries, the success rate of percutaneous revascularization of CTOs was >95 percent, with half of the patients undergoing subintimal crossing and more than 40% needing bail-out stenting. ⁽¹⁰⁾.

Developing an algorithm to increase the chances of a successful CTO crossing could help boost overall procedural success rates for complex endovascular procedures and, as a result, patient outcomes. As a result, we wanted to see how

safe and effective various methods for crossing persistent complete occlusion of the SFA is. ⁽¹¹⁾.

With age, the frequency and prevalence of PAD rises. Although some studies have found that the incidence of both sexes is comparable, the male to female ratio for PAD is generally stated as 2:1 and as high as 3:1 for critical limb ischemia. ⁽¹²⁾. The average age of the patients in our sample was 57.8±69.6 years old, and the majority of the patients were males (56.7 percent). 457 patients with SFA occlusion were recruited by McDermott and colleagues. The average age was 68.3±9.1 years, and males made up 72.9 percent of the population. ⁽¹³⁾. The most significant modifiable risk factor for PAD is smoking, and the causal correlation between the two conditions could be even greater than the one between smoking and coronary artery disease. ⁽¹⁴⁾. In our study, 76.7% of the patients were smokers.

Similarly, Yu and colleagues evaluate the early and midterm results of SFA stenting with self-expanding nitinol stents and to identify the factors affecting patency. Almost 68% of the patients were smokers ⁽¹⁵⁾. Diabetes is a significant risk factor for PAD and more generalized cardiovascular disease, and diabetic patients are twice as likely to develop the disorder as people without diabetes ⁽¹⁶⁾. According to the Framingham Heart Study, hypertension and dyslipidemia are both separate risk factors for PAD. ⁽¹⁷⁾. The majority of patients in our study were diabetic (80%), hypertensive (70%), and dyslipidemic (63.3%). In addition, 23.3% of the patients had history of IHD.

Likewise, From 2003 to 2006, Ihnat and colleagues reviewed the outcomes of 109 consecutive SFA stenting procedures (95 patients) at two university-affiliated hospitals to see if they were successful. Diabetes mellitus (44%) was the most common risk factor, followed by hypertension (84%), hyperlipidemia (76%), coronary artery disease (47%) and chronic renal insufficiency (47%) (25 percent) ⁽¹⁸⁾.

In our study, the most common complaints were rest pain, incapacitating claudication and infection (20% each), followed by unhealed ulcer (16.67%) then dry gangrene (13.3%). The rest have combined complaints in form of rest pain with infection (3.3%), incapacitating claudication with gangrene (3.3%) and rest pain with gangrene (3.3%). Similarly, Scali and colleagues reviewed all SFA interventions performed in consecutive patients with symptoms Rutherford 3 to 6 between 2001 and 2008. A total of 233 limbs in 204 patients underwent SFA interventions. The most common complaint was rest pain, followed by incapacitating claudication and unhealed ulcer ⁽¹⁹⁾.

Three major categories of CTO crossing techniques are currently in use: antegrade wire escalation, antegrade subintimal technique and retrograde approach ⁽²⁰⁾. In our study, the antegrade approach was utilized in 70% of the patients. It was observed that the antegrade approach was associated with female gender and less likelihood of previous interventions. The success rate of antegrade approach was approximately 70%.

In concordance with our findings, Varghese and colleagues A standardized SFA

CTO revascularization (FACTOR) algorithm was defined, which was based on a scoring system and validated by high revascularization success rates. A retrospective study was conducted on 150 patients with SFA occlusive disease. In the antegrade CTO crossing, 128 out of 150 patients (59 percent) had overall procedural performance. ⁽²¹⁾.

However, other reports showed higher success rate of antegrade approach. For example, Wei and colleagues In patients with peripheral arterial disease, the efficacy of recanalization for CTO of the femoral-popliteal artery was investigated. All patients who had endovascular recanalization for femoral-popliteal CTOs at our center between June 2011 and October 2014 were included in this single-center retrospective review. A total of 205 patients with 238 CTOs were enrolled. In total, successful recanalization was achieved in 228 CTOs (95.8%) in the antegrade procedure ⁽²²⁾.

In five patients who failed antegrade approach, the retrograde approach was utilized. One patient crossed with retrograde access only. Two patients needed SAFARI technique to complete revascularization. In the rest two patient, reentry was difficult either from antegrade or retrograde alone, so, rendezvous technique done to help wire reentry into true lumen. In line with our findings, Wojtasik-Bakalarz and colleagues After retrograde recanalization of the SFA, the efficacy and clinical results were evaluated during long-term follow-up. Between June 2011 and June 2015, 17 patients underwent percutaneous retrograde recanalization of the SFA. In 90% of cases, retrograde crossing of the distal SFA was effective. ⁽²³⁾.

The development of more vigorous and technically demanding approaches for the difficult SFA CTO, such as subintimal arterial flossing with antegrade-retrograde intervention (SAFARI), rendezvous procedure, bidirectional balloon angioplasty technique, and various retrograde approaches, has been aided by the implementation of dedicated wires and support catheters. ⁽²⁴⁾.

In our study, two patients underwent SAFARI technique. Patients had successful revascularization, restored pulsation. In addition, two underwent rendezvous technique. The patients had successful revascularization, restored pulsation. To achieve optimal initial procedural success and maintain patency of the SFA, operators occasionally decide to access through contralateral crossing over as lesion is near or flush to the femoral bifurcation ⁽²⁵⁾. Four patients in our study underwent crossing-over. All of those patients had successful revascularization.

The CTOP study is the first to categorize peripheral CTOs and identify factors. CTO mapping using the CTOP classification actually increases the rate of crossing without increase the rate of complications. Saab and colleagues have classified proximal and distal cap anatomy into 4 different types with their C-TOP system ⁽²⁶⁾. In our study, we found that the most common type was C-TOP II (33.3%), followed by type IV (30%), and III (20%). To our knowledge, this is the second study of its kind that has linked CTO cap characteristics to the probability of crossing the lesion using the conventional antegrade method. A retrospective study of imaging and procedure data from 114 consecutive claudication patients was conducted by Saab and colleagues (Rutherford category 3) or 142 CTOs were

treated with endovascular treatments for critical limb ischemia (Rutherford categories 4–6). CTOs of type I were more likely to be crossed antegrade and had a lower rate of extreme Calcification is a term used to describe the process of a A tibio pedal approach was more likely to retrogradely cross Type IV lesions. CTOP type IV was the least likely to be crossed antegradely (26). CTO types II and III, lesion duration, and extreme calcification were all significant predictors of access conversion.

This clinical application of the CTOP classification is critical because it can enable operators to prepare an endovascular strategy from the start of the case, including entry, crossing, and care. This may result in time savings, increased productivity, and reduced exposure to radiation and contrast.

Conclusion

In patients with SFA occlusion, the antegrade procedure is the most widely used cross technique. In complex cases, other methods such as retrograde and cross-over approaches are commonly used. In our research, revascularization progress was high regardless of the method, with few complications that were successfully handled. Based on imaging, treatment plans, patient body habitus, and personal preference, the solution to a particular case should be determined in advance.

The CTOP classification system's four CTO cap forms, on the other hand, were linked to the possibility of crossing these lesions using the conventional antegrade method. Type I lesions were the simplest to cross antegradely, while type IV lesions were the most complicated. The addition of retrograde tibio pedal access benefited CTO forms II, III, and IV. Type IV was the most likely to be crossed from a tibio pedal access in a retrograde manner. These results may have significant clinical implications, allowing doctors to prepare an endovascular strategy that includes entry, crossing, and care from the start. Extravascular ultrasound guidance combined with retrograde tibio pedal access may be beneficial This translates to time savings, increased productivity, reduced radiation and contrast usage, and fewer complications. However, larger cohort studies are required to verify the claimed benefits by using the CTOP classification to classify CTO interventions.

List of abbreviations:

ABI: ankle brachial index

ATA: anterior tibial artery

CART: Controlled antegrade-retrograde dissection/reentry

CBC: complete blood count

CFA: common femoral artery

CT: computerize tomography

CTA: computerized tomographic angiography

CTO: Chronic total occlusions

DM: diabetes mellitus

DPA: dorsalis pedis artery

IHD: ischemic heart disease

IL: intraluminal

PAD: peripheral arterial disease

PAI: peripheral artery interventions

PTA: posterior tibial artery

SAFARI: subintimal arterial flossing with antegrade-retrograde intervention

SFA: Superficial femoral artery

Declaration

Ethical approval:

We confirm that the present study run in concordance with international ethical standards and applicable local regulatory guidelines. Written informed consents obtained from all patients prior to study's enrollment. The study's protocol was reviewed and approved by ethics committee department of general and vascular surgery, Faculty of Medicine, Beni-Suef University (no number available for approval).

Consent of publication

We confirm that informed consent to publish data was obtained from all participants.

Availability of data and material

All data generated or analysed during this study are included in this published article.

Competing interest

The authors declare that they have no competing interests

Funding

This research did not receive any specific grant from funding agencies in the public, commercial, or not-for-profit sectors.

Authors contributions

AME conceived and designed the study, conducted research. KS provided research materials and collected data. AAM organized data. WAE and ARA analyzed and interpreted data. MHA wrote initial and final draft of article. AAM and WAE provided logistic support. All authors have critically reviewed and approved the final draft and are responsible for the content and similarity index of the manuscript.

Acknowledgements

Not applicable.

References

1. Abd El-Mabood ESA, Elkashef OA, Hosny AS and Zaghoul H. Bailout procedures during percutaneous transluminal angioplasty of superficial femoral artery occlusive disease. *Egypt J Radiol Nucl Med.* 2020;51:51.
2. Banerjee S and Brilakis ES. Femoropopliteal artery chronic total occlusion intervention. *Pract. Approach to Peripher. Arter. Chronic Total Occlusions.* 2017:23–40.

3. Azzalini, L., Carlino, M., Bellini, B., Marini, C., Pazzanese, V., Toscano, E., et al. Long-Term Outcomes of Chronic Total Occlusion Recanalization versus Percutaneous Coronary Intervention for Complex Non-Occlusive Coronary Artery Disease. *The American Journal of Cardiology*. 2020;125(2):182-188.
4. Shi, W., Yao, Y., Wang, W., Yu, B., Wang, S., Que, H., et al. Combined Antegrade Femoral Artery and Retrograde Popliteal Artery Recanalization for Chronic Occlusions of the Superficial Femoral Artery. *Journal of Vascular and Interventional Radiology*. 2014;25(9),1363-1368.
5. Bhatti Z, Turba UC and Arslan B. Assessment of safety of a single vessel runoff “peroneal artery access” during the subintimal arterial flossing with antegrade-retrograde intervention (SAFARI) in critical limb ischemia (CLI). *J Vasc Interv Radiol*. 2015;26:S8.
6. Kondapalli, A., Jeon-Slaughter, H., Lu, H., Xu, H., Khalili, H., and Prasad, A., et al. Comparative assessment of patient outcomes with intraluminal or subintimal crossing of infrainguinal peripheral artery chronic total occlusions. *Vascular Medicine*. 2017;23(1):39-45.
7. Hong, S., Ko, Y., Shin, D., Kim, J., Kim, B., Choi, D., Hong, M. and Jang, Y. Outcomes of Spot Stenting Versus Long Stenting After Intentional Subintimal Approach for Long Chronic Total Occlusions of the Femoropopliteal Artery. *JACC: Cardiovascular Interventions*. 2015;8(3):472-480.
8. Allie DE, Patlola RR, Mitran E V., Ingraldi A and Walker CM. Critical limb ischemia. *Peripher. Endovasc. Interv*. 2010:305–18.
9. Rammos C, Radecke T, Lortz J, Steinmetz M and Rassaf T. Guidelines adherence or chronic total occlusion recanalization of the superficial femoral artery with a stentless approach: The next frontier? *SAGE Open Med Case Reports*. 2019;7:2050313X1882344.
10. Bisdas T, Patelis N and Stavroulakis K. Tips and tricks to cross chronic total occlusions in the superficial femoral artery. *J Cardiovasc Surg (Torino)*. 2019;60:567–71.
11. Banerjee S, Shishehbor MH, Mustapha JA, Armstrong EJ, Ansari M, Rundback JH, et al. A percutaneous crossing algorithm for femoropopliteal and tibial artery chronic total occlusions (PCTO Algorithm). *J Invasive Cardiol*. 2019;31:111–9.
12. Wilson A and Brittenden J. Vascular risk factors and their management. *Postgrad. Vasc. Surg. Candidate’s Guid. to FRCS*. 2011:37–48.
13. McDermott MM, Carroll TJ, Kibbe M, Kramer CM, Liu K, and Guralnik JM, et al Proximal superficial femoral artery occlusion, collateral vessels, and walking performance in peripheral artery disease. *JACC Cardiovasc Imaging*. 2013;6:687–94.
14. Ruiz-Canela M and Martínez-González MA. Lifestyle and dietary risk factors for peripheral artery disease. *Circ J*. 2014;78:553–9.
15. Yu, J., Park, K., Jeon, Y., Cho, S., Hong, K., Shin, W., Choe, Y., Shin, S. and Kim, K., Midterm Outcome of Femoral Artery Stenting and Factors Affecting Patency. *Vascular Specialist International*. 2015;31(4):115-119.
16. Shammas, N., Epidemiology, classification, and modifiable risk factors of peripheral arterial disease. *Vascular Health and Risk Management*. 2007;3(2),229-234.
17. Paul N. Fiorilli And Emile R. and Mohler III. Atherosclerotic Risk Factors: Hypertension. *Rutherford’s Vasc. Surg. Endovasc. Ther*. 2019:153–63.

18. Ihnat, D., Duong, S., Taylor, Z., Leon, L., Mills, J. and Goshima, K., et al Contemporary outcomes after superficial femoral artery angioplasty and stenting: The influence of TASC classification and runoff score. *Journal of Vascular Surgery*. 2008;47(5):967-974.
19. Scali, S., Rzucidlo, E., Bjerke, A., Stone, D., Walsh, D., and Goodney, et al: Long-term results of open and endovascular revascularization of superficial femoral artery occlusive disease. *Journal of Vascular Surgery*. 2011;54(3):714-721.
20. Wei LM, Zhu YQ, Zhang PL, Liu F, Lu HT and Zhao JG. Morphological characteristics of chronic total occlusion: predictors of different strategies for long-segment femoral arterial occlusions. *Eur Radiol*. 2018;28:897-909.
21. Varghese V, George J and Marreddy R. femoral artery chronic total occlusion revascularization (factor) study: validation of a peripheral cto algorithm and score. *J Am Coll Cardiol*. 2016;67:308.
22. Wei LM, Zhu YQ, Zhang PL, Lu HT and Zhao JG. Integrated application of antegrade and retrograde recanalization for femoral-popliteal artery chronic total occlusions: Outcomes compared with antegrade recanalization. *Quant Imaging Med Surg*. 2018;8:568-78.
23. Wojtasik-Bakalarz J, Arif S, Chyrchel M, Rakowski T, Bartuś K, Dudek D, et al. Twelve months follow-up after retrograde recanalization of superficial femoral artery chronic total occlusion. *Advances in interventional cardiology journal*. 2017;13:47-52.
24. Hua WR, Yi MQ, Min TL, Feng SN, Xuan LZ and Xing J. Popliteal versus tibial retrograde access for subintimal arterial flossing with antegrade-retrograde intervention (SAFARI) technique. *Eur J Vasc Endovasc Surg*. 2013;46:249-54.
25. Iwata, Y., Ueshima, D., Jujo, K., Kaneko, N., Umemoto, T., and Utsunomiya, M., et al Crossover stenting across the deep femoral artery entry: a multicenter retrospective study. *Cardiovascular Intervention and Therapeutics*. 2018;33(4):372-378.
26. Saab, F., Jaff, M., Diaz-Sandoval, L., Engen, G., McGoff, T., and Adams, G., et al Chronic Total Occlusion Crossing Approach Based on Plaque Cap Morphology: The CTOP Classification. *Journal of Endovascular Therapy*. 20