

How to Cite:

Suganthy, M., Hemalatha, S., Vinotha, M., & Kirthiga, K. (2022). Lab view model for effective detection of diabetic retinopathy. *International Journal of Health Sciences*, 6(S1), 10584–10595. <https://doi.org/10.53730/ijhs.v6nS1.7299>

Lab view model for effective detection of diabetic retinopathy

Dr. M. Suganthy

Associate Professor, Electronics and Communication Engineering, Vel Tech Multi Tech Dr.Rangarajan Dr.Sakunthala Engineering College

Email: suganthym46@gmail.com

Hemalatha. S

U.G Students, Electronics and Communication Engineering, Vel Tech Multi Tech Dr.Rangarajan Dr.Sakunthala Engineering College

Email: shemalatha484@gmail.com

Vinotha. M

U.G Students, Electronics and Communication Engineering, Vel Tech Multi Tech Dr.Rangarajan Dr.Sakunthala Engineering College

Email: vinothameikandan135@gmail.com

Kirthiga. K

U.G Students, Electronics and Communication Engineering, Vel Tech Multi Tech Dr.Rangarajan Dr.Sakunthala Engineering College

Email: kirthigakumar1704@gmail.com

Abstract---Diabetic Retinopathy is a continuous damage of the retinal blood vessels caused by chronic “HYPERGLYCEMIA”. This can be caused by the problem of diabetes and it is of two types i.e Type 1, Type 2. At first, DR has no symptoms, if it is not treated it make lead to low vision and blindness. Diabetic retinopathy is one of the major reason for the blindness. As a result, adequate screening is required to detect diabetic retinopathy at an early stage. The study describes a Diabetic Retinopathy Screening System that ophthalmologists utilize as a major identifying tool to find Diabetic Retinopathy symptoms. The system uses functional forms like blood vessels, exudates, and microaneurysms in retinal pictures. By removing characteristics from divided images and using GLCM, the retinal images are divided and classed as normal or DR impacted images (Gray Level Co occurrence Matrix).The system is carried out and tested in “LAB VIEW” to justify and take measurements with less effort than traditional programming. The Lab view is the best choice for the beginners who do not have much or any experience with code or programming knowledge. In lab

view the graphical representation is easier to use and also for the better understanding.

Keywords---Diabetic Retinopathy, LABVIEW, Blood vessel, Gray level Co occurrence Matrix, Exudates, Blood clot.

Introduction

Diabetic Retinopathy

Diabetic retinopathy is also known as DIABETIC EYE DISEASES(DED). It occurs when the tiny blood vessels in the retina get damaged. It may lead to low vision , blind spots. At its early stage it does not show any symptoms. If it is not treated for long time it lead to permanent vision loss. The patient gets the knowledge only at its advanced stage. Once it reaches the advance stage the vision loss becomes unavoidable. Figure 1 portrays the difference between normal retina and Diabetic retina. Abnormal blood vessels associated with Diabetic retinopathy encourage the growth of scar tissue which pulls the retina back of the eye. The diabetic retinopathy presence can be detected by examining theretina fromitsfeatures.

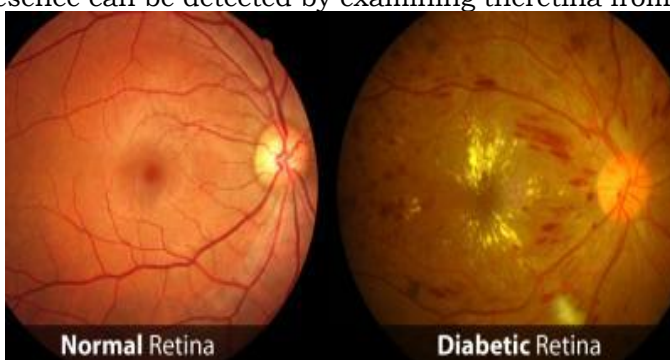

Figure 1. Difference Between Normal Vison And Diabetic Retina.

Abnormalities Related With Retina

Due to leaking of blood vessels, swelling , fatty deposits on the retina and any changes to the retinal blood vessels may lead to “DIABETIC RETINOPATHY”. A person who are suffers from the diabetes are more likely to develop the cataract the younger age. The stages of DR can be earliest stage, retina get blocked, blood vessels blocked are stages shown in figure 2.

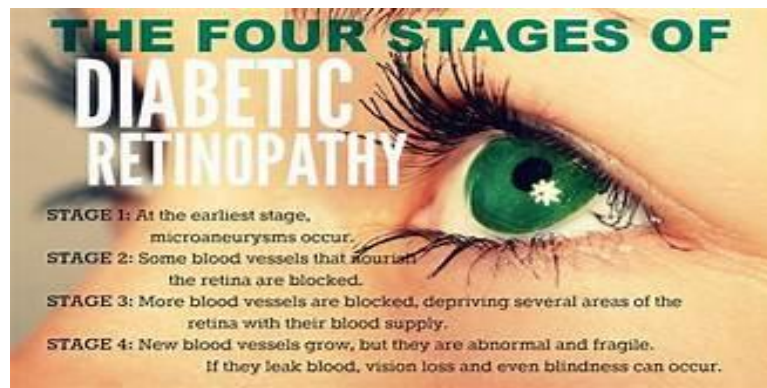


Figure 2: Stages of Diabetic Retinopathy

Microaneurysms

Microaneurysms are ordinarily the most earliest sign of diabetic retinopathy. The input image with microaneurysms is given below in Fig 3. It shows minor ruddy specks scattered within the retina posteriorly (single bolts). They may be encompassed by a ring of yellow lipid, or difficult, exudates. Microaneurysms form when blood sugar levels are high, causing small blood artery walls to expand.

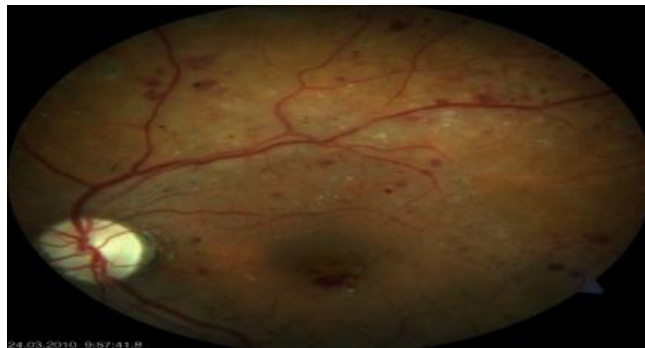


Figure 3. Input Image with Microaneurysms.

Hemorrhages

It occurs in the deep layer of the retina. Because of its “ROUND” shape it is called as “BLOT HEMORRHAGES”. The number of retinal blood vessels will rise as they become more damaged and spongy. Retinal haemorrhages resemble microaneurysms or big flame-shaped haemorrhages and appear as little red dots or blots.

Hard Exudates

The important features of Diabetic retinopathy is “Hard exudates”. Their size ranges from small specks to larger patches with accurate edges. Hard exudates are consists of lipid and proteinaceous material that resolve in outer retinal image. These can damage the vision by stopping the light to reach the retina. Fig 4 Shows the retina with exudates.

Soft Exudates

Soft exudates is also known for “COTTON WOOL SPOT”. It is a yellow – white injury in the external retina that usually settled in an area less than $\frac{1}{4}$ of the optic disc. As the disease reaches the advance stage, the multiple small patches of retina does not get adequate blood supply. The deficient blood supplied regions of retina are appear as fluffy whitish blobs are called “cotton wool spot”.

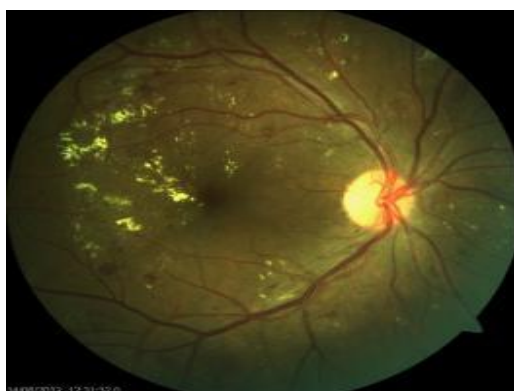

Figure 4 . Input Image With Exudates

Literature Survey

According to the latest survey from the International Diabetic Federation, approximately 8.7% of the world lives with diabetes as of 2019, approximately a 2.4 % increment from 2010. This implies that around 417 million individuals are living with diabetes. Usually anticipated to extend to 645 million by 2040. Nations with most diabetic predominance.

1. Marshall Island (32.5%)
2. Kiribati (23.5%)
3. Tuvalu (23.1%)
4. Sudan (23.1%)
5. Mauritius (23.0%)

The proposed framework by M. Suganthy and S. Manjula achieves 96.67 percent precision for 256 elements using GKPCA straight SVM. For direct SVM, the misleading acknowledgement rate (FAR) and bogus dismissal rate (FRR) are 0 and 3 respectively[1]. According to [2] DRIVE Database Retrieved, the retinal vascular tree is unique to each individual and can be used for biometric recognized verification. The purpose of this trial, according to the authors [3], was to evaluate the safety and efficacy of back sub-kenalog Join's (PSTK) infusion as an adjuvant treatment to intravitreal anti-VEGF in intractable CME from RVO. In [4], the authors tested DR using Messidor database with base 12 and base 13. They obtained good results using a combination of feature extracted from CNN transfer learning and SVM for the classification of diabetic retinopathy.

The goal of [5] is to discuss the difficulties encountered in dividing CT and MR images, as well as the relative merits and drawbacks of currently available

methodologies for dividing clinical images. A survey of writing incorporating the pathophysiology of RR and contemporary remedial treatments available was conducted by Giuliani et al [6]. The model suggested by the researcher [7] recognises binocular fundus pictures as information sources and learns their relationship in order to make expectations. The authors of [8] discovered that the detection of Diabetic retinopathy involves three stages: pre-handling of shading fundus photographs, analytic component extraction, and DR characterisation. So, using a few image computations, scientists were able to determine the thickness of the veins, which determines the severity of diabetes a person may have. For the location and analysis of DR, a variety of methodologies have been presented. Two points stand out in this paper: the number and area of MA are not set in stone [9].

Sifting techniques are used by the writers Betteena Sheryl et al.,[10] to remove noise and natural impedance from images. This approach has taken on neighbourhood entropy thresholding for picture division. The authors [11] demonstrated Diabetic retinopathy pervasiveness at the global level, dating all the way back to 2008, using just data from selected locations. The goal of the flow study is to complete an orderly survey and meta-investigation to infer strong and refreshing gauges on worldwide and setting-explicit DR predominance, given the rapidly changing examples in DR the study of illness transmission.

The researchers [12] devised a method that is computer-controlled and consists of two stages: optic plate discovery and exudate localization. Using the engendering through radii technique, the optic plate is extracted. The researchers in [13] provide a Diabetic Retinopathy Screening Framework that ophthalmologists can use as an important finding instrument in the screening system to distinguish Diabetic Retinopathy symptoms. In retinal images, the framework makes advantage of physical designs such as veins, exudates, and microaneurysms. Suvajit Dutta suggested a three-type model: back proliferation NN, profound neural organisation (DNN), and convolutional neural organisation (CNN). Even if profound learning models beat NN[14], neural networks have the lowest precision due to one secret layer. The authors' proposed framework is based on programmed identification of retinal illnesses like DR, with the primary purpose of removing highlights that indicate the homogeneity of limited regions of the retinal picture (exudates).

Existing System

In the existing system, this set-up order load in two dimensional planes with avail from x-axis and y-axis. The images for detecting exudates. The image are back - up by balancing it with the early existing images fatigued by the ophthalmologists. Detected the progression of diabetic retinopathy by detection of micro aneurysms instead of exudates. strainer banks are used to detect DR by quality vectors that are work out for each type of region in eye based on definite effects of color, strength and shape etc. it is a multi model approach that balancing Gaussian mixture model and Support Vector Machine. The severity and vigorousness of two of these diseases included detecting. The existing detecting system burdens medical professionals and hence, this research proposes an

diabetic retinopathy system that accesses images, preprocesses it, extracts essential features and classifies the images accordingly using labview.

Methodologies of Proposed Work

Detection of Diabetic Retinopathy using labview involves three phases which are as follows:

1. Extraction of Blood clot
2. Extraction of Exudates
3. Exarction of Microaneurysms

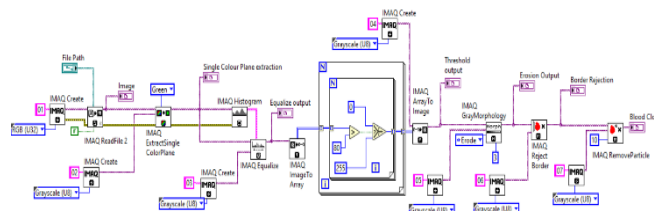


Figure 5. Block Diagram For Detection Of Blood Clot

A) Input Image

The retinal images of the diabetic patients in Fig 6 which are taken by the digital fundus camera are collected from the Eye Hospital. The collected images are saved in the format of jpg. These images are used for training and testing. The images used here is identified by the medical officers for each image such as retinal images.

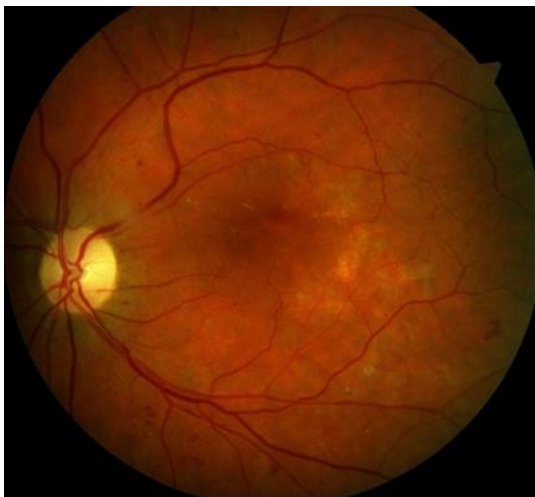

Figure 6: Input Image For Diagnosis

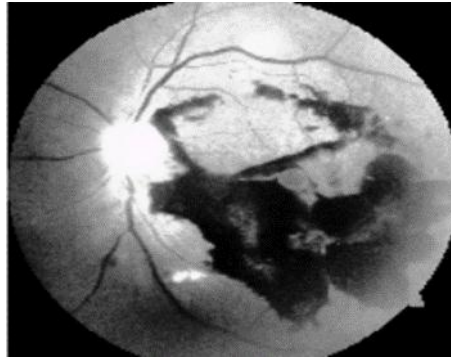

Figure 7: Equalized Image

B) Thresholding

It uses a pixel values in an retinal image to divide the image into two regions, which as the object under the examination and background region. The range of pixel values is determined by the user or automatically as threshold.

1. Pixel value outside the range = 0
 2. Pixel value inside the range = 1
- Binary image is the result of threshold.

C) Morphology

To apply morphology, image must be grayscale or binary. The two categories are

1. Binary Morphology – Here the functions are applied to Binary images.
2. Gray Scale Morphology- Here the functions are applied to Gray level images. After the image equalization, by applying the morphology technique the image shown in figure 10.

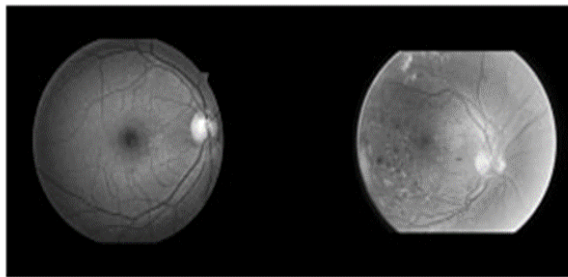


Figure 8: Input Image With Morphology

Functions Of Gray Level Morphology are as Follows:

- 1) Erosion: It decreases the brightness of the pixels, surrounded by neighbours with lower intensity and here the size of the images get shrinks.
- 2) Dilation: It increases the brightness of the pixels, surrounded by neighbours with higher intensity. Structuring element defines the neighbourhood.
- 3) Opening Function: Here gray level erosion is followed by gray level dilation.

4) Closing Function: Gray dilation is followed by Gray level erosion.

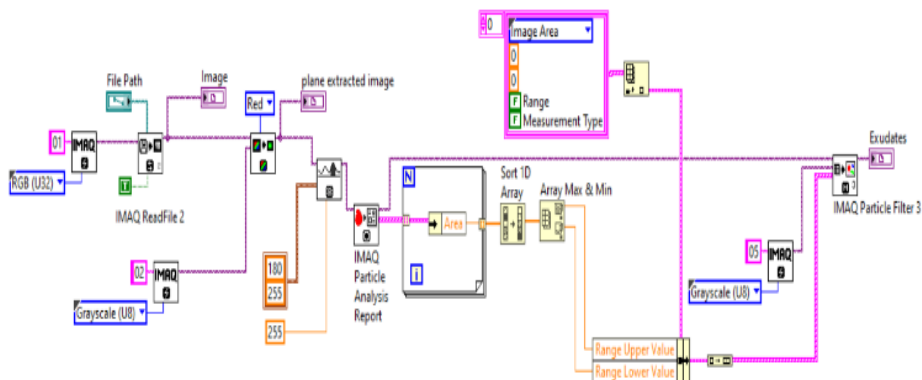


Figure 9: Block Diagram For Detection Of Exudates

A) Image Read

The blend of these two VIs takes into consideration the perusing and showing of any picture document in these arrangements. Read JPEG Record VI , or Read PNG Record VI followed by the Draw Straightened Pixmap VI . The Read VIs are contained in the Functions»Graphics and Sound»Graphics Configuration range, and the Draw VI is in Functions»Graphics and Sound»Picture Capacities range.. The default is 255.

B) Plane Extraction

Extricates a solitary plane from shading picture. Shading Plane characterizes the shading plane to separate. Look over the accompanying qualities, As well as exhibiting how to separate shading planes and grayscale pictures, the code is intended to likewise show the distinctions between the shading plane extraction and grayscaling of a picture. RGB (0)(Default) Determines the shading design RGB (red, green, and blue).

Particle Analysis The default is an unfilled string. Number of Particles shows the quantity of particles distinguished in the picture. Picture Out (copy) is a reference to the Picture input. You can utilize various boundaries like border, point, region, and focus of mass to distinguish and group these particles. Utilizing different boundaries can be quicker and more powerful than design matching in numerous applications. Connectivity 4/8 (8) indicates the kind of availability utilized by the calculation for molecule discovery.

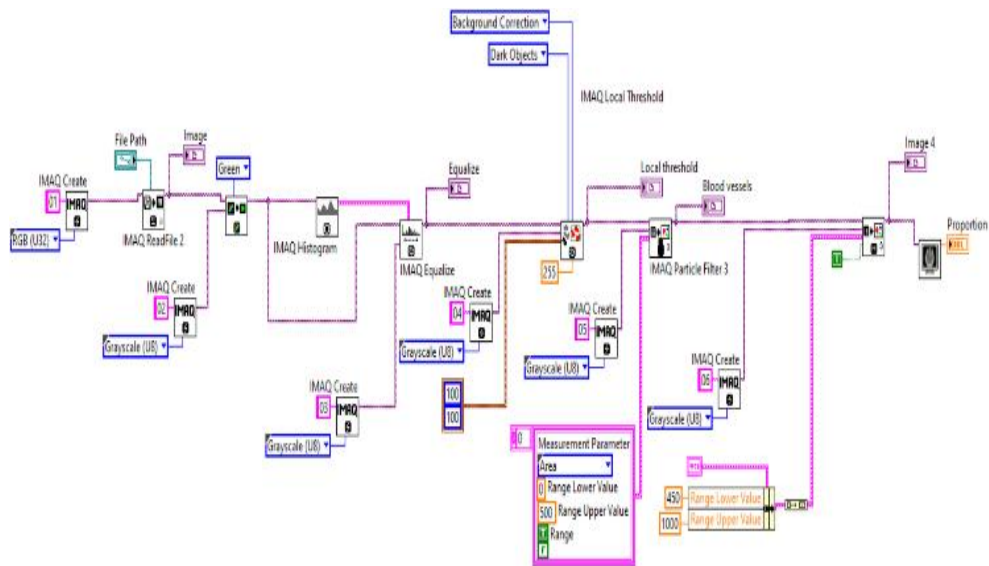


Figure 10: Block Diagram For Detection Of Microaneurysms

A) Histogram

In labview the histogram may be a recurrence number of times that a indicates the interval happens within that input grouping. Histogram chart shows the bar chart of the histogram of the input arrangement X. Where as the Y axis is the “Histogram number”, and the X axis is the “Centre values of the histogram”. X values is the centre values of the given interval. Histogram calculates the overall number of pixels present in each step of grayscale level. The grayscale values ranges from 0 to 255.

B) Local Threshold

Threshold an image into a binary image based on the specified local adaptive thresholding method. The two types of images used are Image Src is the source image and Image Dst is the destination image. The thresholding algorithm used in the local threshold is Method (Niblack). In lab view for local threshold the function is called IMAQ Local Threshold. Before the function runs the error in or no error shows the status of the error. The input Look for shows which type of object you are looking for, and the values for bright object is indicates by “0”and the dark object is indicates by “1”.

C) Particle Filter

The particle filter keeps or removes the molecule in the picture according to its estimation. This VI adjusts the source picture. In case, in need of the original source image, make a copy of duplicate image using the IMAQ copy before using this VI. In lab view the function used for particle filter is IMAQ PARTICLE FILTER.

Simulation Result in lab view

To evaluate the performance of the proposed system, a dataset containing the real images of Diabetic retinopathy is needed. The experiments were conducted in lab view with image processing tool box. Extraction of blood clot using the threshold and morphology is shown in figure 11. Presence of exudates is detected using particle analysis and plane extraction, which is shown in figure 12. Extraction of microaneurysms using the particle filter, histogram and equalization is presented in figure 13.

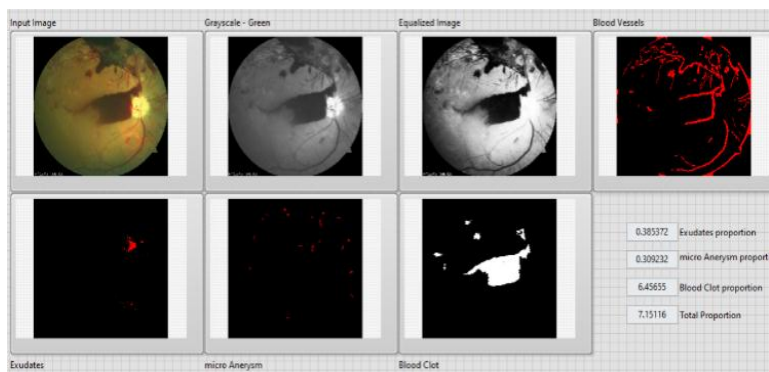


Figure 11: Extraction Of Blood Clot

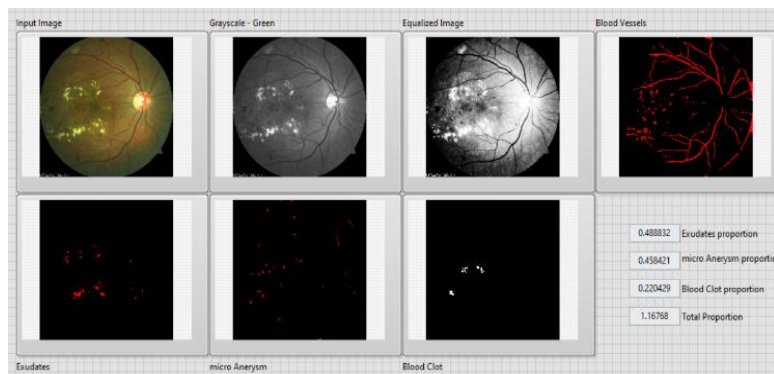


Figure 12: Extraction Of Exudates

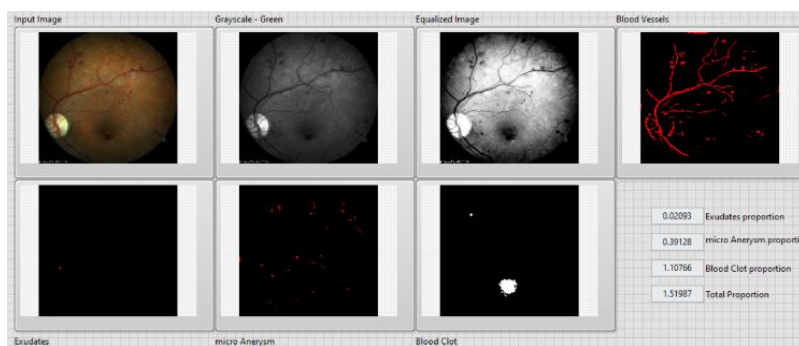


Figure 13: Extraction Of Microaneurysms

Table I
Image Proportion

Blood clot	Exudates	Microaneurysm	Total proportion
6.45655	0.385372	0.309232	7.15116
0.220429	0.488832	0.458421	1.16768
1.10766	0.02093	0.39128	1.51987

Conclusion

In this work, the abnormalities associated with the retina. are Blood clot, Exudates or Microaneurysms indicates the presence of DR. Early signs of DR may be seen in nonproliferative diabetic retinopathy, and it is crucial to diagnose and study DR in its early phases. If a diabetic has proper eye care on a regular basis and therapy when necessary, DR will sometimes result in total blindness. In this DR research, a significant amount of time is spent looking for haemorrhages, microaneurysms and exudates, diabetic macular edoema, and aberrant new blood vessels in fundus pictures as indicators of the presence of retinopathy. Features extracted from the lab view are used to identify the Diabetic Retinopathy in the collected retinal images. This system helps the medical experts in the screening process to find the DR. This can be considered a primary identification tool or decision support tool for ophthalmologist.

Reference

1. Suganthy, MAnd Manjula, S, "Performance Analysis Of Iris Biometric System Using GKPCA And SVM", Int. J. Information Technology and Management, vol . 20, pp.207 – 216, Inder science publishers , 2021.
2. DRIVE Database Retrieved From <Http://Www.Isi.Uu.Nl/Research/Database/DRIVE>, Accessed On 02-01-2014.
3. Estafanous MFG, Kaiser PK and Bowen A, " Posterior Sub-Tenons Kenalog Injections In Diabetic Macular Edema", [Saudi Journal of Ophthalmology, vol.29](#), pp- 270-273 , 2015.
4. DinialUtami, Nurul Qomariah, HandayaniTjandra and ChastineFaticah "Classification OfDiabetic Retinopathy And Normal Retinal Images Using CNN And SVM ",12th International Conference on Information & Communication Technology and System (ICTS), 2019.
5. Neeraj Sharma and Lalit M.Aggarwal, "Automated Medical Image Segmentation Techniques" Journal Of Medical Physics, 2010, vol. 35, issue1, pp. 3–14, 2010.
6. Giuliari, Gian Sadaka, Ama Hinkle,David Simpson andErnest, "Current Treatments For Radiation Retinopathy", Acta oncologica (Stockholm, Sweden),vol .50, pp.6-13 , 2011.
7. XianglongZeng,HaiquanChen,Yuan Luo and Wenbin Ye, "Automated Diabetic Retinopathy Detection Based on Binocular Siamese-Like Convolutional Neural Network",IEEE Access pp(99):1-1,2019.

8. V.V.K. Raju, S.Sagar, B.Divya, K.Madhulika and D.Sandeep, "Retinal Image Analysis For Diabetic Retinopathy", The international journal of analytical and experimental modal analysis ,vol. 12, Issue 5 ,2020.
9. Kumar. S and Kumar.B, "Diabetic Retinopathy Detection By Extracting Area And Number Of Microaneurysm From Color Fundus Image", 5th International Conference on Signal Processing and Integrated Networks (SPIN), pp. 359-364, IEEE, 2018.
10. Betteena Sheryl Fernando, Heena Firdaus, Alexander and Jothimanikandan R, "Diabetic Retinopathy Detection Using Retinal Images", Journal of advances in Engineering and Management (IJAEM), vol.3, issue 3, pp.230-237, 2021.
11. Riccardo Cheloni, Stefano A Gandolfi, Carlo Signorelli and Anna odone , "Global Prevalence Of Diabetic Retinopathy Protocol For A Systematic Review And Meta Analysis, published on BMJ, vol.9, issue 3, 2019.
12. Vijaya Kumari.V and Suriya Narayanan. N, "Diabetic Retinopathy-Early Detection Using Image Processing Techniques", International Journal on Computer Science and Engineering, vol.2, no.2, pp. 357-361, 2010.
13. Priya.R and Aruna.P, "Review Of Automated Diagnosis Of Diabetic Retinopathy Using The Support Vector Machine", International journal of applied engineering research, vol. 1, no. 4, pp. 844-863, 2011.
14. Suvajit Dutta, Bonthala CS Manideep, Syed Muzamil Basha, Ronnie D. Caytiles and N. Ch. S. N. Iyenga, "Classification Of Diabetic Retinopathy Images By Using Deep Learning Models," International journal of Grid and Distributed Computing, vol .11, pp. 89-106, 2018.
15. Jestin V.K, Anitha J and Jude Hemanth, "Texture Feature Extraction For Retinal Image Processing", In International Conference on Computing, Electronics and Electrical Technologies (ICCEET), pp. 548-551, 2012.