

How to Cite:

Priyadarshini, Haritha, B., Nandini, G., Lakshmi, S. C. B., Thote, K., & Bhosle, S. (2022). Assessment of the frequency and the course of anterior loop of mandibular canal near mental foramen using CBCT. *International Journal of Health Sciences*, 6(S3), 7650–7668. <https://doi.org/10.53730/ijhs.v6nS3.7800>

Assessment of the frequency and the course of anterior loop of mandibular canal near mental foramen using CBCT

Dr. Priyadarshini, MDS

Oral Physician and Maxillofacial Radiologist, New Janapriya Super Speciality Hospital, Bengaluru - 560043

*Corresponding author email: drdarshini8@gmail.com

Haritha B. MDS,

Senior Lecturer, Department of Oral Medicine and Radiology, Meghna institute of Dental sciences, 503001

Email: drharithabathula@gmail.com

Gopu Nandini

Meghna institute of Dental sciences, Graduation: Bachelor of Dental sciences

Email: gopu2825nandini@gmail.com

Shantala Lakshmi C. B. MDS.

Reader, Department of Prosthodontics Crown Bridge& implantology, Sri Rajiv Gandhi College of Dental Sciences & Hospital, Bengaluru – 560032

Email: drshantalalakshmicb@gmail.com

Dr. Kirannayi Thote

Assistant Professor, Department of Pedodontics, Meghna institute of Dental sciences, Nizamabad

Email: kiranmayi.703@gmail.com

Sunitha Bhosle, MDS.

Oral Medicine and Radiology, Consultant Stomatologist, CV hospital, Bengaluru

Email: bhoslesunitha@gmail.com

Abstract---The identification of the MC is an important prerequisite for surgical procedures. Hence a careful evaluation of MC and evaluation of presence and course of AL prior to any surgical procedures is mandatory. In this regard CBCT has proven to be a valuable diagnostic tool. To assess the frequency and the course of AL of MC near mental foramen, to evaluate age-related and gender-related changes of AL and also to correlate the variations of the located AL of the same image bilaterally using existing CBCT scans.

To assess the frequency and Length of the AL of MC near mental foramen on CBCT. To evaluate the age-related and gender-related & side-related changes of AL of MC by using CBCT. To evaluate different AL anatomical variants by using CBCT. CBCT images were retrospectively evaluated. Scans of the patients were made at 90 kVp and 12 mA at different resolutions. The FOV was 8-8 cm. Slices thickness of 0.150mm to evaluate the location on MC & AL. The frequency of AL among the subjects was 44%, with significant prevalence in females (25.3%). The AL was found more commonly in the younger age group & was present bilaterally. The lingual cortex was closest. The present study showed that the mandibular canal was closest to the apex of mandibular 2nd molar teeth. A high prevalence of AL was detected among females & younger individuals.

Keywords---mandibular canal, anterior loop, CBCT, anatomic variation.

Introduction

The location of Inferior Alveolar canal (IAC) & its variations is a critical factor that can influence the surgical procedures involving the mandible such as dental implant placement, fractures involving mandible, orthognathic surgeries and so on. The neurovascular bundle may be vulnerable to the surgical procedures especially when certain anatomical variations are present such as bifid mandibular canal, retromolar and accessory mental foramen and also the presence or absence of anterior loop of mandibular canal.¹ The inferior alveolar nerve may extend beyond the mental foramen in an anterior and inferior direction, curving back to the foramen and forming a loop, which has been termed the anterior loop of the inferior alveolar nerve,²⁻⁴ of the mental nerve,⁵⁻⁸ or of the mandibular canal.^{9, 10} Strikingly variable results regarding the prevalence of anterior loops of the inferior alveolar nerve have been reported in the literature, ranging from 22%-28%, 6 to 88%,¹¹ and a maximum length of 11 mm has been reported.¹¹

Differences in evaluation techniques (conventional radiographs, computed tomography [CT] scans, and direct anatomical analyses) may have influenced these variations. Furthermore, the criteria for measuring the anterior loop should be considered, since some authors have used anatomical planes to identify the anterior limit of the mandibular canal,^{3,9,10,12} while others have differentiated between the anterior loop and the incisive canal by evaluating the diameters of these structures.^{2,4,13} Thus, it is essential to use a diagnostic method that allows the satisfactory visualization and correct measurement of anatomical variations. Cone-beam CT (CBCT) presents several advantages, such as allowing the three-dimensional (3D) assessment of craniofacial structures without distortion or overlapping images, in addition to a lower radiation dose than multislice CT. Moreover, CBCT is considered the standard method for assessing bone tissue^{14,15} and is able to determine the presence and length of the anterior loop with precision and reliability.^{3,4} It should be highlighted that significant individual anatomical variations are present to various extents among different populations

and ethnic groups. It is very important to precisely identify and to preserve neurovascular bundles in order to avoid neurosensory damage in the interforaminal region. The aim of this study was to assess the frequency and the course of anterior loop of MC near mental foramen, to evaluate age-related and gender-related changes of AL and also to correlate the variations of the located AL of the same image bilaterally using existing CBCT scans.

Aims and objectives

Aim

The aim of the study was to assess the course of anterior loop of MC near mental foramen on CBCT.

Objectives

- To assess the frequency and Length of the anterior loop of MC near mental foramen on CBCT.
- To evaluate the age-related and gender-related & side-related changes of AL of MC by using CBCT.
- To evaluate different anterior loop anatomical variants by using CBCT.

Materials and Methods

This retrospective study study was conducted in the Department of Oral Medicine & Radiology, Navodaya Dental College, Raichur to assess the frequency and the course of anterior loop of mandibular canal on 150 patients using CBCT images from the year 2013 to 2016 between the age group of 18 to 60 years.

An ethical clearance was obtained from ethical committee of Navodaya Dental College & Hospital, Raichur.

Inclusion criteria

- Images of the patient in the age group of 18 to 60 years
- Presence of sound permanent teeth without any restorations or orthodontic appliances.

Exclusion criteria

- Missing >1 posterior mandibular tooth (excluding third molar)
- Nonvisible MC from the sagittal view of CBCT scans.
- Presence of pathologies involving cysts, tumors, fractures, periodontally compromised patients in the posterior mandible and vascular malformations.
- Artifacts that affected diagnostic quality (restorations or orthodontic appliances)

Materials

- Sirona Orthopos SI CBCT, FOV of 8×8 cm with max 90 kVp and 12 Ma, Germany.
- diagnosis software was used for viewing the images of Slice thickness of 0.15mm.
- Dell 24-inch non-glossy monitor with a Dell Optiplex 9010 Work Station (Dell Inc, Round Rock, TX)

Method of study

Subjects

The study comprised of subjects who had undergone CBCT imaging from the year 2013-2016. CBCT images were retrospectively evaluated. The study samples were divided into 4 groups according to age i.e., Group A – 21-30yrs, Group B – 31-40yrs, Group C – 41-50yrs and Group D – 51-60yrs.

CBCT imaging

Scans of the patients were made at 90 kVp and 12 mA at different resolutions. The field of view was 8-8 cm. Slices thickness of 0.150mm. All constructions and measurements were performed on Dell 24-inch non-glossy monitor, by a single examiner. The intra-examiner callibration was performed on a pilot sample size of 50 scans for reliability of location of anatomical structures and measurement.

Location of mandibular canal

- Evaluation and measuring the changes of location of mandibular canal.
Pano window is used to draw the Dental Pano curve. Pano plane was selected by moving the cross hair line in coronal window at the cervical area and by rotating the cross line on sagittal window, such that the cross line is parallel to inferior border of mandible. After selected the mandibular region, pano curve was drawn manually on axial window & pano image was reconstructed.
- Mental Foramen Location
On MPR window location of mental foramen was done. Mental foramen was located on the Axial window. Once anteroposterior and right & left MPR planes are located at mental foramen, the Anteroposterior plane is rotated in a clockwise direction to trace the mandibular canal between mandibular foramen and mental foramen in sagittal window. Once the mandibular canal is traced, nerve is added in order to achieve the length and diameter of the mandibular canal. Same procedure is repeated for the opposite canal by rotating the anteroposterior MPR plane in anti-clockwise direction. Additionally, the course of the mandibular canal together with AL was traced.

Anterior loop measurement

The presence, morphology, course and length of the anterior loop was determined by measuring four distances:

- The length of anterior loop was measured from the medial margin of the mental foramen to the anterior loop proximal edge.
- The distance between the buccal border of the anterior loop and the buccal cortex
- The distance between the lingual border of the anterior loop and the lingual cortex
- The distance between the inferior border of the anterior loop and the inferior border of the mandible.

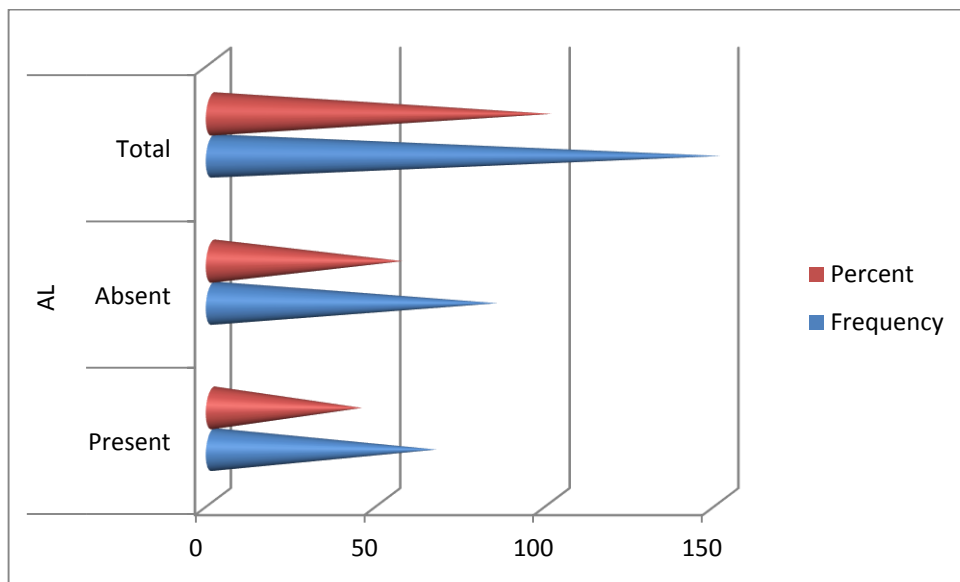
Statistical analysis

Data were collected by using a structure proforma. Data was entered in MS excel sheet and analysed by using SPSS 19.0 version IBM USA. Quantitative data were expressed in terms of Mean and Standard deviation Qualitative data were expressed in terms of proportions. Comparison of mean and SD between two groups was done by using students unpaired t test. Comparison of mean and SD between all groups was done by using One way ANOVA test. Post Hoc test (Tukeys HSD) to assess whether the mean difference between groups is significant or not P value of <0.05 was considered as statistically significant, whereas p value <0.001 was considered as highly significant.

Results

Table 1
Frequency of Anterior Loop

		Frequency	Percent
AL	Present	66	44
	Absent	84	56
	Total	150	100

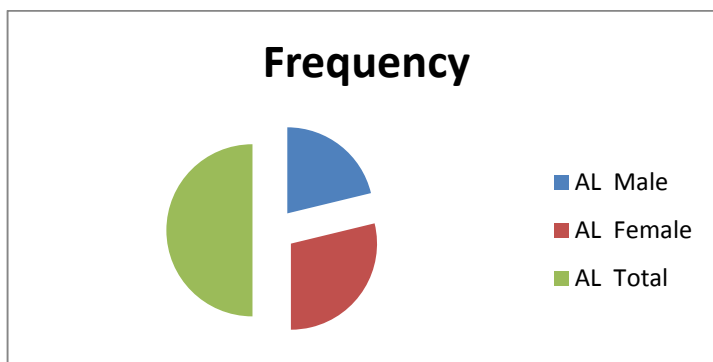


Graph 1. Frequency of Anterior Loop

Among 150 subjects frequency of anterior loop was visualized in 66 (44%) (Table 1 & Graph 1).

Table 2
Frequency of Anterior Loop according to Gender

GENDER		Frequency	Percent
AL	Male	28	18.6
	Female	38	25.3
	Total	66	44

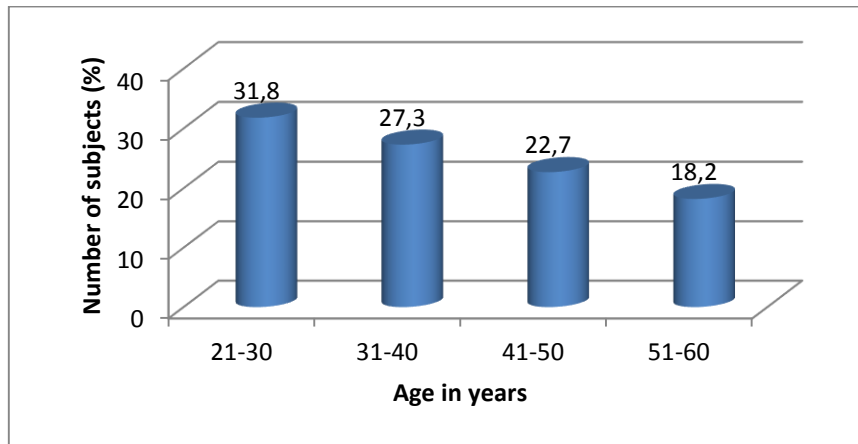


Graph 2. Frequency of Anterior Loop according to Gender

Prevalence of anterior loop was higher among females 38(25.3%) as compared in males 28(18.6 %). (Table 2 & Graph 2)

Table 3
Frequency of Anterior Loop according to Age

		Frequency	Percent
Age group in years	21-30	21	31.8
	31-40	18	27.3
	41-50	15	22.7
	51-60	12	18.2
	Total	66	100.0



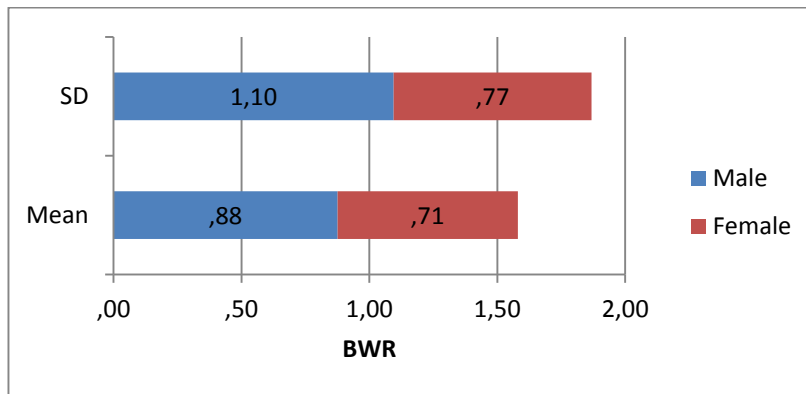
Graph 3. Frequency of Anterior Loop according to Gender

The frequency of Anterior Loop was higher in the age range of 21-30yrs (31.8%) followed by 31-40yrs (27.3%), 41-50yrs (22.7%) & 51-60yrs (18.2%) respectively (Table 3 & Graph 3)

Table 4
Measurement of Distance between buccal border of Anterior Loop to buccal cortex on right side

	SEX	N	Mean	Std. Deviation	t	df	P	Inference
BWR	Male	70	.88	1.10	1.113	148	.267 (>0.05)	Not significant
	Female	80	.71	.77				

BWR* - Buccal width right



Graph 4. Distance between buccal border of Anterior Loop to buccal cortex on right side

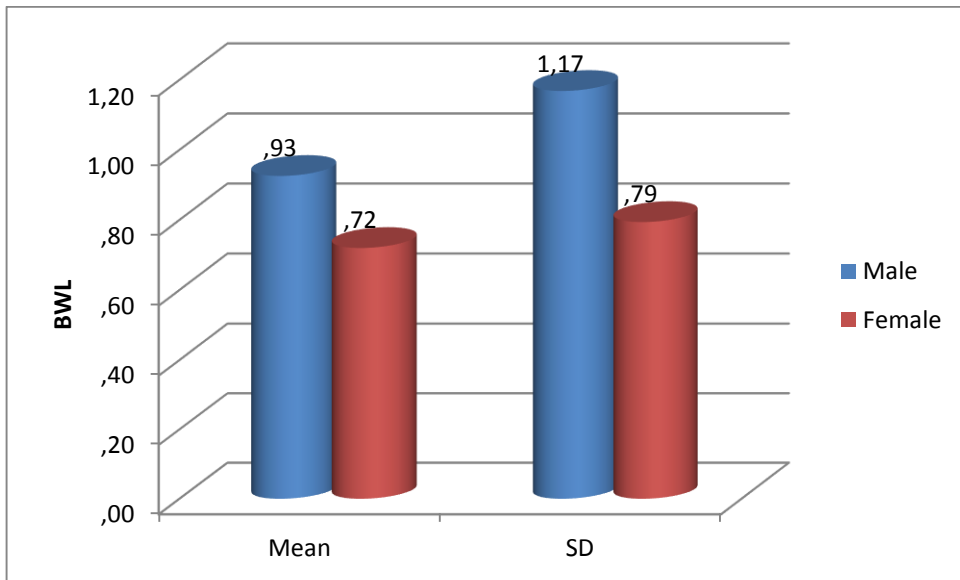
The mean values of the distance between buccal border of anterior loop to buccal cortex on right side was high in males (0.88 ± 1.10) as compared to females (0.71 ± 0.77) (Table 4 & Graph 4). On comparing values were not significant ($P > 0.05$) between genders.

Table 5

Measurement of Distance between buccal border of Anterior Loop to buccal cortex on left side

	SEX	N	Mean	Std. Deviation	t	df	P	Inference
BWL	Male	70	.93	1.17	1.274	148	.205 (>0.05)	Not significant
	Female	80	.72	.79				

BWL* - Buccal width left



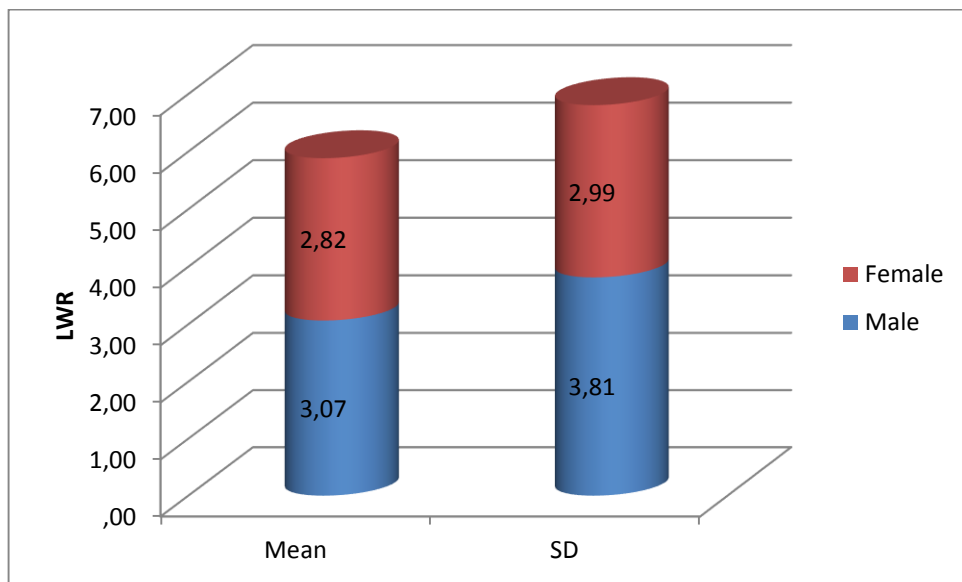
Graph 5. Measurement of Distance between buccal border of Anterior Loop to buccal cortex on left side

The mean values of the distance between buccal border of anterior loop to buccal cortex on left side was high in males (0.93 ± 1.17) as compared to females (0.72 ± 0.79) (Table 5 & Graph 5). On comparing values were not significant ($P > 0.05$) between genders.

Table 6
Measurement of Distance between lingual border of Anterior Loop to lingual cortex on right side

	SEX	N	Mean	Std. Deviation	t	df	P	Inference
LWR	Male	70	3.07	3.81	.441	148	.660 (>0.05)	Not significant
	Female	80	2.82	2.99				

LWR* - Lingual width right



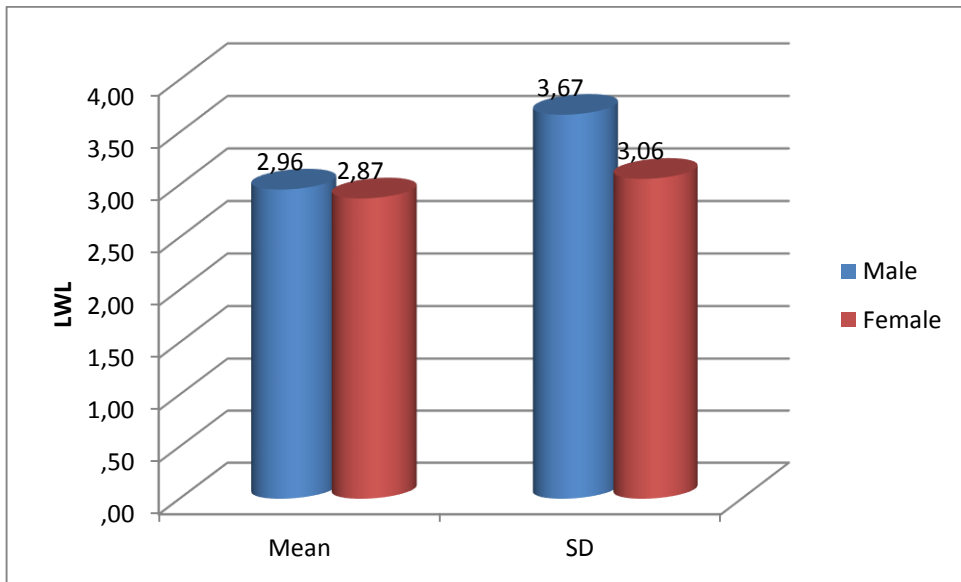
Graph 6. Measurement of Distance between lingual border of Anterior Loop to lingual cortex on right side

The mean values of distance between lingual border of anterior loop to the lingual cortex on right side was higher in males (3.07 ± 3.81) as compared to females (2.82 ± 2.99) (Table 6 & Graph 6). On comparing values were not significant ($P > 0.05$) between genders.

Table 7
Measurement of Distance between lingual border of Anterior Loop to lingual cortex on left side

	SEX	N	Mean	Std. Deviation	t	df	P	Inference
LWL	Male	70	2.96	3.67	.154	148	.878 (>0.05)	Not significant
	Female	80	2.87	3.06				

LWL* - Lingual width left



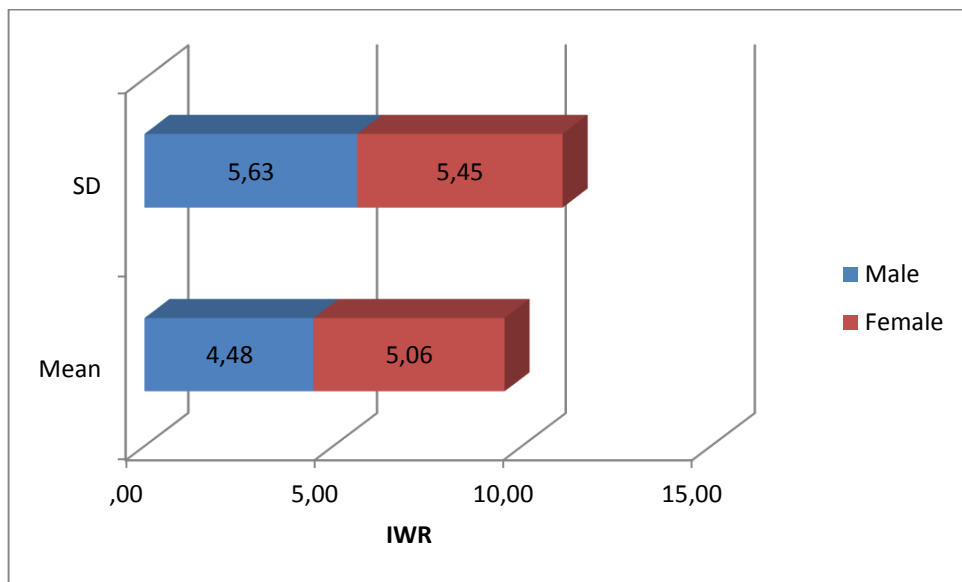
Graph 7. Measurement of Distance between lingual border of Anterior Loop to lingual cortex on left side

The mean values of the distance between lingual border of anterior loop to the lingual cortex on left side was higher in males (2.96±3.67) as compared to females (2.87±3.06) (Table 7 & Graph 7). On comparing values were not significant (P>0.05) between genders.

Table 8
Measurement of Distance between inferior border of Anterior Loop to inferior border of mandible on right side

	SEX	N	Mean	Std. Deviation	t	df	P	Inference
IWR	Male	70	4.48	5.63	-.646	148	.519 (>0.05)	Not significant
	Female	80	5.06	5.45				

IWR* - Inferior width right



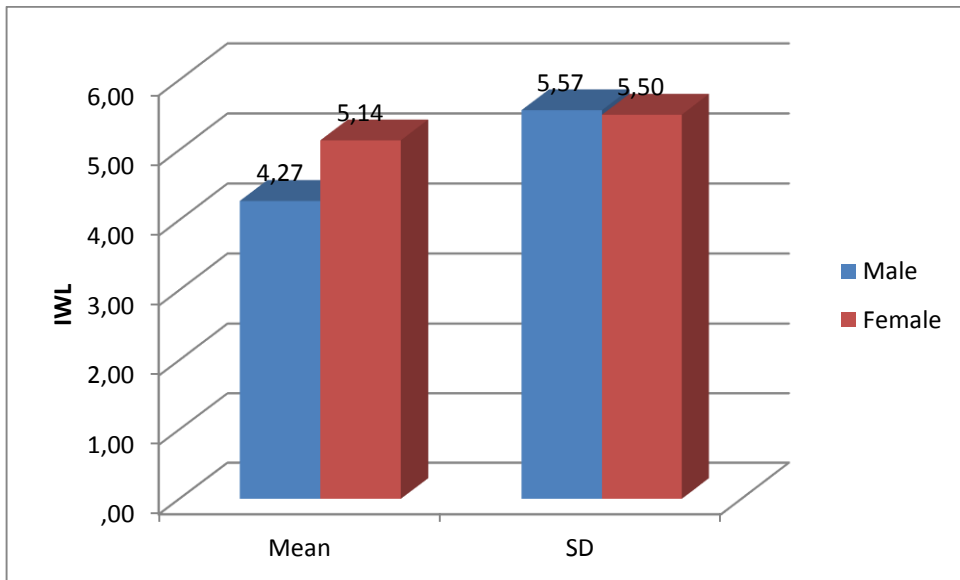
Graph 8. Measurement of Distance between inferior border of Anterior Loop to inferior border of mandible on right side

The mean value of distance between inferior border of anterior loop and the inferior border of mandible on right side was higher in males (4.48 ± 5.63) as compared to females (5.06 ± 5.45) (Table 8 & Graph 8). On comparing values were not significant ($P > 0.05$) between genders.

Table 9
Measurement of Distance between inferior border of Anterior Loop to inferior border of mandible on left side

	SEX	N	Mean	Std. Deviation	t	df	P	Inference
IWL	Male	70	4.27	5.57	-0.955	148	.341 (>0.05)	Not significant
	Female	80	5.14	5.50				

IWL* - Inferior width left



Graph 9. Measurement of Distance between inferior border of Anterior Loop to inferior border of mandible on left side

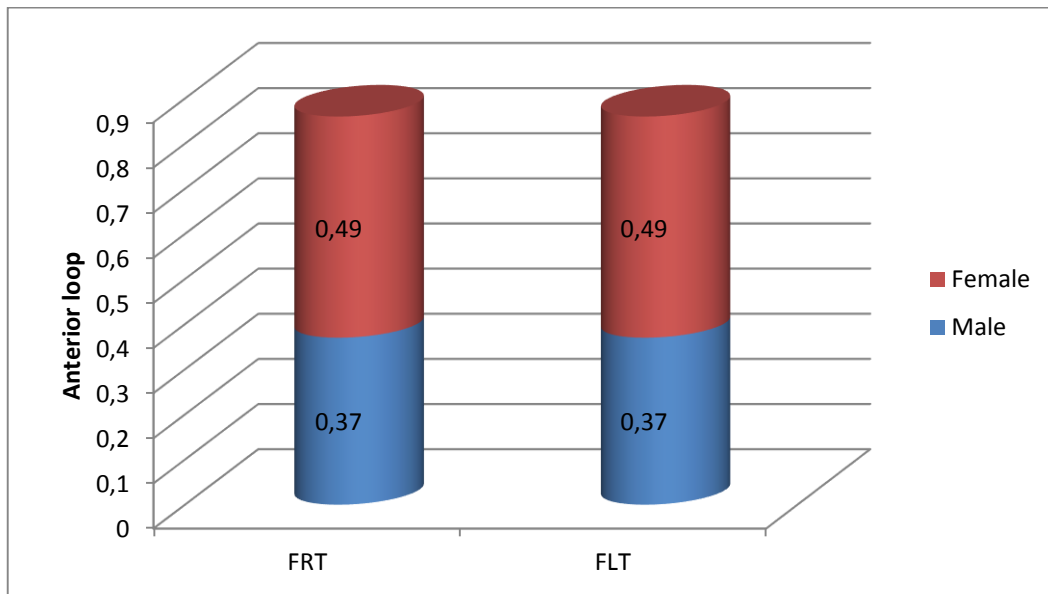
The mean value of distance between inferior border of anterior loop and the inferior border of mandible on left side was higher in males (4.27 ± 5.57) as compared to females (5.14 ± 5.50) (Table 9 & Graph 9). On comparing values were not significant ($P > 0.05$) between gender.

Table 10
Frequency of Anterior loop on right and left side

	SEX	N	Mean	Std. Deviation	t	df	P	Inference
F RT	Male	70	.37	.49	-.665	148	.507	Not significant
	Female	80	.43	.50				
	SEX	N	Mean	Std. Deviation	t	df	P	Inference
F LT	Male	70	.37	.49	-.665	148	.507	Not significant
	Female	80	.43	.50				

F RT* - Frequency right

F LT* - Frequency left



Graph 10. Frequency of Anterior loop on right and left side

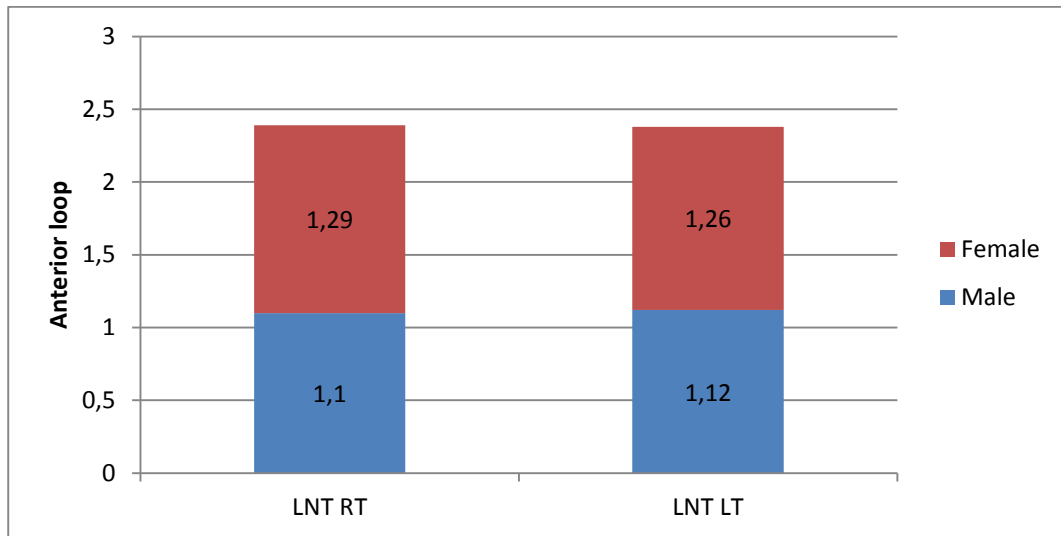
The mean value of frequency of anterior loop on right and left sides in males was 0.37 & in females was 0.49 as shown in Table 10 & Graph 10. On comparison of these values between genders though the values were higher in females & was found to be not significant ($P > 0.05$)

Table 11
Length of Anterior loop on right and left side

	SEX	N	Mean	Std. Deviation	t	df	p	Inference
LNT RT	Male	70	1.10	1.45	-.768	148	.444 (>0.05)	Not significant
	Female	80	1.29	1.52				
	SEX	N	Mean	Std. Deviation	t	df	p	Inference
LNT LT	Male	70	1.12	1.43	-.586	148	.559 (>0.05)	Not significant
	Female	80	1.26	1.52				

LNT RT* - length right

LNT LT* - length left



Graph 11. Length of Anterior Loop on right and left side

The mean value of anterior loop length measuring on right and left sides in males was 1.1 and 1.12 and in females 1.29 & 1.26 respectively as shown in Table 11 & Graph 11. On comparison of these values between genders though the values were higher in females and was found that the results were not significant ($P>0.05$)

Discussion

The inferior alveolar nerve may extend beyond the mental foramen in an anterior and inferior direction, curving back to the foramen and forming a loop, which has been termed the anterior loop of the inferior alveolar nerve, ²⁻⁴ of the mental nerve, ⁵⁻⁸ or of the mandibular canal.^{9, 10} Although it is a benign anatomical variation, its accurate identification is essential for surgical planning, particularly for dental implant placement, in order to prevent iatrogenic complications and to ensure the effectiveness of surgical procedures performed in this region.^{5,9} The prevalence of anterior loops of the inferior alveolar nerve have been reported in the literature, ranging from 22%-28% to 88%, and a maximum length of 11 mm has been reported.¹⁰ Our study showed that the anterior loop of the mandibular canal was present in 44% of the study subjects (Table 1, Graph 1), which was almost in accordance with the study conducted by Apostolakis et al.², where anterior loop was identified in 48% of cases. The present study value is higher than the prevalence reported by Kuzmanovic et al.,¹³ Kaya et al.,⁶ and Ngeow et al.,¹⁹ which could be explained by the fact that these analysis were performed on panoramic images, which has inherent limitation such as distortion and the presence of overlapping structures. Similar to our finding, studies using three-dimensional images have demonstrated higher rates of prevalence for the anterior loop, with values ranging from 34% to 88%.

In the present study we found that the anterior loop was more prevalent in younger patients 21-30yrs age (31.8%) and female patients (25.3%) (Table 2 & 3 ; Graph 2 & 3). No significant difference between the right and left sides was found.

Other studies have also shown that the anterior loop was predominantly seen in females and frequency was higher in the second decade of life.²⁰⁻²¹ . The mean distance between the buccal border of the anterior loop and the buccal cortex in males was 0.88mm on right side and 0.93mm on left side. Whereas in females it was 0.71mm on right side and 0.72mm on the left side. The measurements in males were slightly higher as compared to females, but were statistically not significant ($p > 0.05$) (Table 4 & 5; Graph 4 & 5). Our results were in accordance with the study conducted by Eren et al (2016)¹¹ where the distance between the buccal border of the anterior loop and the buccal cortex ranged from 2.54 mm & 1.9mm in males and females respectively. Similar results were also observed in the studies by Braut et al (2012)¹⁷ & Simonton et al (2009)¹⁸ where they found significant difference in that buccal bone thickness was higher in males as compared to females.

The mean distance between the lingual border of the anterior loop and the lingual cortex in males was 3.07 on right side and 2.96mm on left side. Whereas in females it was 2.82mm on right side and 2.87mm on the left side. The mean distance between the inferior border of the anterior loop and the inferior border of the mandible in females was 4.48mm on right side and 4.27mm on left side, whereas in males it was 5.06mm on right side and 5.14mm on left side. The measurements in males were slightly higher than females, however the values were not significant ($p > 0.05$) (Table 6 – 9; Graph 6 – 9). Our results were in accordance with the studies conducted by Angel et al (2011)²⁰ and Afser et al²¹ (1998), Kieser et al²² (2005). Eren et al¹¹ in 2016 observed, the mean distance between the lingual border of the anterior loop and the lingual alveolar wall ranged from 3.8mm to in females to 4.9 mm in males & the distance between the inferior border of the anterior loop and the inferior border of the mandible ranged from 8.2mm in females & 9.0 mm in males, the results remained constant in relation to buccal and lingual cortex as found in our study.

Variations observed in the present study regarding the distance from the anterior loop from buccal, lingual & inferior border of mandible could be explained because of the course and location of mandibular canal, which is more lingually placed in the posterior body of the mandible and progressively it becomes more superficial in relation to buccal surface where it ends at the mental foramen. Usually the mandible are generally larger in volume in males, and that the vertical height and buccolingual width of the mandible is also greater in males than in females, which was also observed in our study. In the present study, most of the anterior loops were observed bilaterally, followed by the left and right sides, respectively (Table 10, Graph 10). These findings are similar to those reported by Apostolakis² who also observed an anterior loop bilaterally in most of the study subjects. In the survey conducted by Filo et al.,⁴ majority of anterior loop was also observed bilaterally, followed by the right and left sides, respectively.

The mean length of anterior loop is measured from the medial margin of the mental foramen to the anterior loop proximal edge which ranges from 2.9 to 3.3 mm (mean, 3.15 mm). The mean length of the anterior loops found in our study was 1.1 mm (Table 11, Graph 11); a value close to those that have been reported in the literature.^{9,10} The largest anterior loop observed was 4 mm. Despite being clinically relevant in extent, this length was far lower than the maximum lengths

of 9 mm reported by Uchida et al^{9,10} and 11 mm reported by Neiva et al¹². Moreover, our research demonstrated that in 97.1% of cases, the length of the anterior loop was less than or equal to 3 mm, which was similar to the findings of Apostolakis and Brown² & Filo et al⁴ where 95% of cases showed lengths measuring approximately 3 mm. Thus the present study showed significant difference in the location, distance of the mandibular canal from the root apices of mandibular molars. The high prevalence and significant extent of anterior loop found with respect to age & sex in this study highlighted the importance of knowledge regarding this anatomical variation. Hence it is necessary for professionals to identify the presence of anterior loop and to measure them correctly when planning procedures involving the interforaminal region.

Conclusion

The high prevalence and significant extent of the anterior loop found in this study highlight the importance of knowledge regarding this anatomical variation. For this reason, it is necessary for professionals to identify the presence of anterior loops and to measure them correctly when planning procedures involving the interforaminal region. With the increasing demand for accurate preoperative assessment and planning prior to oral implant surgery or other surgeries of this region, cross-sectional images such as from CBCT may be utilized for obtaining more information on the appearance, location and course of the canals and their relation to the other anatomical structures in the jaw bone including the apex of tooth.

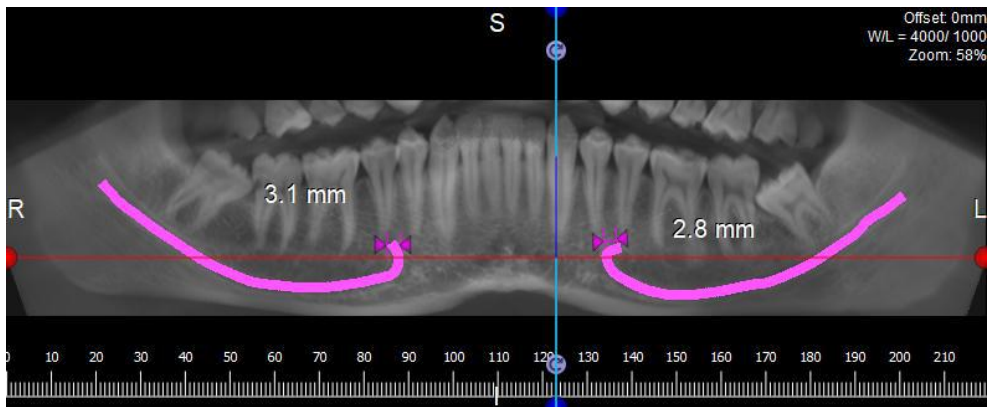
References

1. Okeson JP. management of temporomandibular disorders and occlusion. 5th ed. London: Mosby; 2003. p.3
2. Apostolakis D, Brown JE. The anterior loop of the inferior alveolar nerve: prevalence, measurement of its length and a recommendation for interforaminal implant installation based on cone beam CT imaging. *Clin Oral Implants Res* 2012; 23:1022-30.
3. Rosa MB, Sotto-Maior BS, Machado Vde C, Francischone CE. Retrospective study of the anterior loop of the inferior alveolar nerve and the incisive canal using cone beam computed tomography. *Int J Oral Maxillofac Implants* 2013; 28: 388-92.
4. Filo K, Schneider T, Locher MC, Kruse AL, Lübbers H. The inferior alveolar nerve's loop at the mental foramen and its implications for surgery. *J Am Dent Assoc* 2014; 145: 260-9.
5. Greenstein G, Tarnow D. The mental foramen and nerve: clinical and anatomical factors related to dental implant placement: a literature review. *J Periodontol* 2006; 77: 1933-43.
6. Kaya Y, Sencimen M, Sahin S, Okcu KM, Dogan N, Bahcecitapar M. Retrospective radiographic evaluation of the anterior loop of the mental nerve: comparison between panoramic radiography and spiral computerized tomography. *Int J Oral Maxillofac Implants* 2008; 23: 919-25.
7. de Oliveira-Santos C, Souza PH, de Azambuja Berti-Couto S, Stinkens L, Moyaert K, Rubira-Bullen IR, et al. Assessment of variations of the

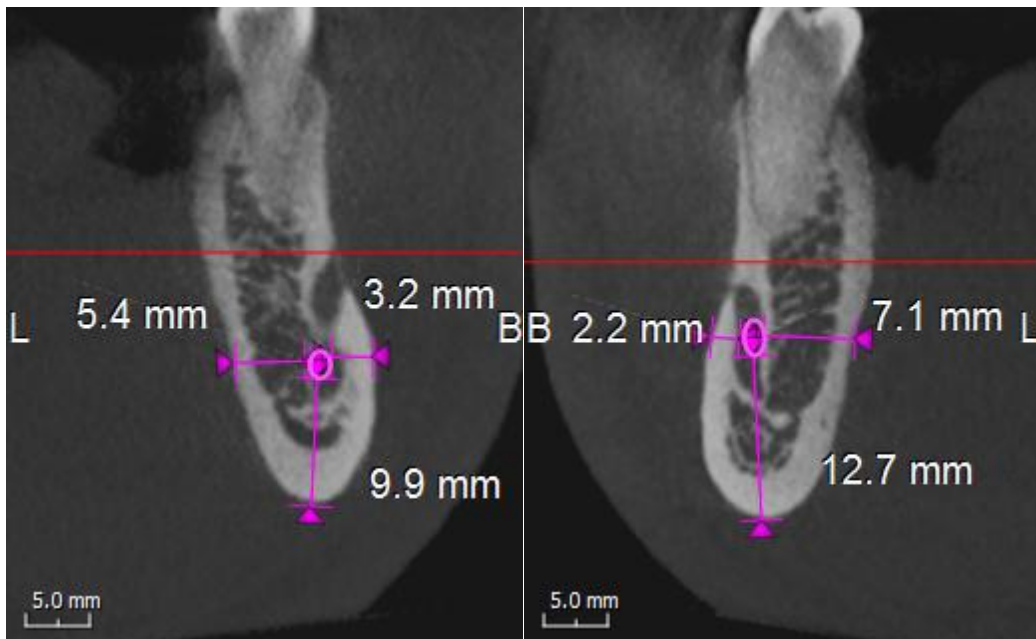
- mandibular canal through cone beam computed tomography. *Clin Oral Investig* 2012; 16: 387-93.
8. Parnia F, Moslehifard E, Hafezeqoran A, Mahboub F, Mojaver- Kahnamoui H. Characteristics of anatomical landmarks in the mandibular interforaminal region: a cone-beam computed tomography study. *Med Oral Patol Oral Cir Bucal* 2012; 17: e420-5.
 9. Uchida Y, Yamashita Y, Goto M, Hanihara T. Measurement of anterior loop length for the mandibular canal and diameter of the mandibular incisive canal to avoid nerve damage when installing endosseous implants in the interforaminal region. *J Oral Maxillofac Surg* 2007; 65: 1772-9.
 10. Uchida Y, Noguchi N, Goto M, Yamashita Y, Hanihara T, Takamori H, et al. Measurement of anterior loop length for the mandibular canal and diameter of the mandibular incisive canal to avoid nerve damage when installing endosseous implants in the interforaminal region: a second attempt introducing cone beam computed tomography. *J Oral Maxillofac Surg* 2009; 67: 744-50.
 11. Eren H, Orhan K, Bagis N, Nalcaci R, Misirli M, Hincal E. Cone beam computed tomography evaluation of mandibular canal anterior loop morphology and volume in a group of Turkish patients. *Biotechnology & Biotechnological Equipment*. 2016; 30:2, 346-353
 12. Neiva RF, Gapski R, Wang HL. Morphometric analysis of implant-related anatomy in Caucasian skulls. *J Periodontol* 2004; 75: 1061-7.
 13. Kuzmanovic DV, Payne AG, Kieser JA, Dias GJ. Anterior loop of the mental nerve: a morphological and radiographic study. *Clin Oral Implants Res* 2003; 14: 464-71.
 14. Li X, Jin ZK, Zhao H, Yang K, Duan JM, Wang WJ. The prevalence, length and position of the anterior loop of the inferior alveolar nerve in Chinese, assessed by spiral computed tomography. *Surg Radiol Anat* 2013; 35: 823-30.
 15. Liang X, Jacobs R, Hassan B, Li L, Pauwels R, Corpas L, et al. A comparative evaluation of cone beam computed tomography (CBCT) and multi-slice CT (MSCT) Part I. On subjective image quality. *Eur J Radiol* 2010; 75: 265-9.
 16. Suomalainen A, Kiljunen T, Käser Y, Peltola J, Kortensniemi M. Dosimetry and image quality of four dental cone beam computed tomography scanners compared with multislice computed tomography scanners. *Dentomaxillofac Radiol* 2009; 38: 367-78.
 17. Braut V, Bornstein MM, Lauber R, Buser D. Bone dimensions in the posterior mandible: a retrospective radiographic study using cone beam computed tomography—part 1: analysis of dentate sites. *Int J Periodontics Restorative Dent* 2012;32:175–84.
 18. Simonton JD, Azevedo B, Schindler WG, Hargreaves KM. Age- and Genderrelated Differences in the Position of the Inferior Alveolar Nerve by Using Cone Beam Computed Tomography. *J Endod*. 2009 Jul;35(7):944-9.
 19. Ngeow WC, Dionysius DD, Ishak H, Nambiar P. A radiographic study on the visualization of the anterior loop in dentate subjects of different age groups. *J Oral Sci* 2009; 51: 231-7.
 20. Angel JS, Mincer HH, Chaudhry J, Scarbecz M. Cone-beam Computed Tomography for Analyzing Variations in Inferior Alveolar Canal Location in Adults in Relation to Age and Sex. *J Forensic Sci*. 2011 Jan;56(1):216-9.

21. Afsar A, Haas DA, Rossouw PE, Wood RE. Radiographic localization of mandibular anesthesia landmarks. *Oral Surg Oral Med Oral Pathol Oral Radiol Endod* 1998;86(2):234–41.
22. Kieser, J., Kuzmanovic, D., Payne, A., Dennison, J. & Herbison, P. Patterns of emergence of the human mental nerve. *Arch Oral Biol.* 2002;47: 743–747.

Length of Anterior Loop On Right & Left Side



Measurements of the anterior loop from the Buccal Cortex, Lingual Cortex & Inferior Border of Mandible on Both Right and Left side.



PROFORMA FOR THE STUDY

Sl.no :-
 Date:-
 Name :-
 Age / sex :-
 CBCT Imaging :-

Frequency and course of anterior loop near mental foramen.

Anterior loop	Width Right(mm)	Width Left(mm)	Length		Frequency
			R	L	
Length from the medial margin of the mental foramen.					
Distance between the buccal border of the anterior loop and the buccal alveolar wall.					
Distance between the lingual border of the anterior loop and the lingual alveolar wall.					
Distance between the inferior border of the anterior loop and the inferior border of the mandible.					