

**How to Cite:**

Naji, I. Q., Wadee, S. A., & Hameed, B. K. (2022). Adverse effects of aspirin on hormonal and hastopathological changes in male rats. *International Journal of Health Sciences*, 6(S3), 8252–8264. <https://doi.org/10.53730/ijhs.v6nS3.7814>

# Adverse effects of aspirin on hormonal and hastopathological changes in male rats

**Ibrahim Qahtan Naji**

Dept. of Pharmacology, Collage of Veterinary Medicine, Tikrit University

**Siham Agmee Wadee**

Dept. of Pharmacology, Collage of Veterinary Medicine, Tikrit University

**Bader Katlan Hameed**

Dept. of Pharmacology, Collage of Veterinary Medicine, Tikrit University

**Abstract**---Aspirin (Acetylsalicylic acid) is widely used in human and veterinary as anti-inflammatory cardiovascular prophylaxis, anti-clotting agent and to decrease cancer risk. However, it is frequently mis- or over-consumed to prevent pain. Many hazards linked with its use have been recorded, but there is a lack of data on its effects on androgenic studies, testicular histology, kidney histology, liver histology, and reproductions. We tried to gather information on its adverse toxicity effects on male rat reproductive in this research. According to research, aspirin has a fatal effect on sperm production and reproductive hormones, as well as lowering testicular weight and altering blood profile. Because aspirin is a prostaglandin inhibitor, it may have an effect on the male reproductive system. Aspirin's detrimental toxic character is further revealed by liver damage.

**Keywords**---aspirin, hormonal, hastopathological, male rats.

## Introduction

Over 50 years ago, inflammation is treated by non steroidal anti-inflammatory drugs (NSAIDs) Which are the most widely and extensively used for their analgesic, antipyretic, and anti-inflammatory properties <sup>(1,2)</sup>. Aspirin (acetylsalicylic acid) was introduced to treatment more than 100 years ago (1)Due to its anti-inflammatory and anti-pyretic advantages, it is widely used in clinical environments. First, it was reported by this aspirin and non-steroidal anti-inflammatory drugs inhibit it Pro inflammatory prostaglandin E2 synthesis. It was late reports that aspirin has inhibitory effects on Cyclooxygenase-1 (COX-1) activity by serine acetylation 530and COX-2<sup>(3-6)</sup>. Aspirin has been reported to produce a reaction to the risk of cancer and heart problems due to its anti-

thrombotic effect. This is due to its inhibition of the cyclooxygenase enzyme (Cox), the arachidonic metabolizes. Acid to a variety of prostanoids, including Thromboxan A<sub>2</sub> (7,8).

The anti-thrombocyte effects of aspirin were tested in various forms of coronary artery disease, pregnancy. Induced hypertension and preeclampsia in angiotensin- sensitive primigravida at low doses and showed positive. Results in most reports. The literature of the recent year creates a lot of awareness and realization of the genotoxic capacity of drugs<sup>(9)</sup>. Infertility has been defined as failure to conceive after frequent unprotected sexual intercourse for one or two years. Male factor infertility accounting for 50% of cases<sup>(10)</sup>. Increasing cases of infertility in men due to the frequent use of a series of therapeutic drugs, has made efforts to study their unfavorable side effects on man's reproduction. Several medications used to treat disease will be informed to cause male infertility, infertility is an important problem for 15-20% of young couples and about 50%. Infertility refers to problems in men. one of very Aspirin's worst effect is on male reproduction. sperm Production is the main reproductive activity of male fertility, and is influenced by many different factors such as therapy and non-therapeutic agents such as chemicals and radiation and environmental factors can regulate or affect sperm production. The testicular weight of aspirin-treated rats was observed to be significantly lower. Reduced sorbitol dehydrogenase and hyaluronidase activity fewer spermatids, and more spermatocyte nuclei were found. Androgen activity is required for spermatogenesis and the operation of the accessory reproductive organs<sup>(11-13)</sup>.

The aim of the study was to assess the effect of aspirin on serum testosterone and FSH levels, and testicular histology in rats.

### **Material and Methods**

The rats were randomly divided equally into three groups:

- Control group 1 (G1): It included 10 adult rats, the animals of this group received 1 ml normal saline 0.9% for 4 weeks.
- Treated group 2 (G2): It included 10 rats, each animal received 25 mg/kg/day of aspirin for 4 weeks.
- Treated group 3 (G3): It included 10 rats, each animal received 50mg/kg/day of aspirin for 4 weeks.

Blood samples were collected through the heart puncture with the aid of a syringe. Samples were dispensed into plain tubes and allowed to clot.

The serum was collected after centrifugation within 30 minutes of specimen collection and stored at -40°C for hormone and biochemical measurements.

Testosterone and FSH levels were assessed using a commercial enzyme-linked immunosorbent assay kit (CUSABIO Biotech Co., USA).

### **Animals**

Thirty adult males of rats weighing ( 220 - 225 g ), it has been achieved in the animal house of the college of veterinary medicine at the Tikrit University. The animals were kept under controlled environmental circumstances. They were

provided a free access to standard pellet diet and tap water. The excised testicular specimens were immediately fixed in 10% formalin and processed for paraffin embedding according to standard procedure. Serial sections of five  $\mu\text{m}$  thickness were cut and stained with hematoxylin and eosin (H&E)<sup>(14-16)</sup>. Statistical analyses were performed using SPSS 11.5 (SPSS Inc., Chicago, IL). Data are presented as mean SD, with  $P < 0.05$  being considered statistically significant.

## Results & Discussion

### The effect of Aspirin on sex hormones Testosterone hormone

Table 4-5  
Effect of Aspirin on Testosterone hormone in studied groups

Groups	Testosterone hormones
Group1 Control	$0.630 \pm 0.006$ A
Group 2	$0.485 \pm 0.022$ B
Group 3	$0.192 \pm 0.009$ C

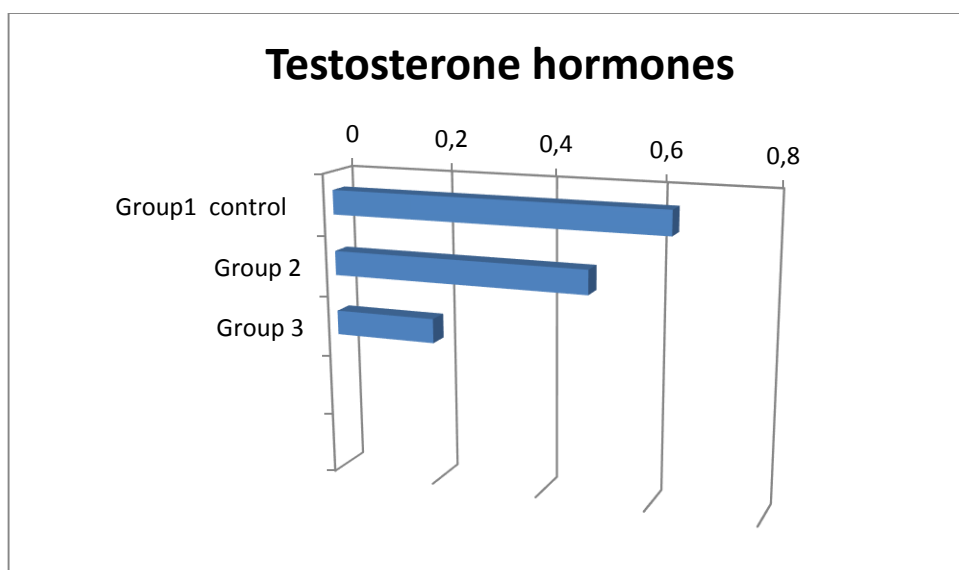


Figure 4-5. Testosterone changes associated with aspirin administration to rat at concentration (25 mg/kg body weight twice/day) and (50 mg/kg body weight twice/day). significant differences ( $p \leq 0.05$ )

The using of aspirin in dose of 25 mg /kg /body weight and 50 mg/Kg/ body weight for 30 day lead to significant decrease ( $p \leq 0.05$ ), in the level of Testosterone hormone compare with group 1( control group). In experimental group 1 the level of testosterone hormone ( $0.630 \pm 0.006$ ) (ng) compare with group 2 and group 3 ( $0.485 \pm 0.022$ ) (  $0.192 \pm 0.009$  )respectively. Several researchers recently discovered that taking aspirin reduced testosterone production significantly<sup>(17)</sup>. Aspirin treatment resulted in a drop in Sertoli cell quantity and a

change in microscopic morphology, with Sertoli cells showing pyknosis and nuclear shrinkage <sup>(18)</sup>. Interestingly, testosterone receptors (androgen receptors) are found on Leydig cells, Peritubular cells, and Sertoli cells, but not on germ cells in the mature testis <sup>(19)</sup>. This is why testosterone does not directly target germ cells; instead, testosterone targets the Sertoli cell, which feeds the germ cell and allows it to differentiate into spermatozoa <sup>(20)</sup>. Aspirin's ability to interfere with testosterone production by lowering androgen receptor sites could be one of the reasons behind this. Adult mammalian spermatogenesis is a testosterone-dependent process, and many investigations have found that removing testosterone from the rat testis causes germ cell death <sup>(21)</sup>. As a result, the ability to reproduce is harmed because germ cell growth does not progress beyond the pachytene stage of meiosis if testosterone levels are unstable or low, testosterone levels in the adult testis of rats should be steady and high <sup>(22)</sup>. The blood-testis barrier, which provides a specific environment for germ cell growth and prevents immunogenic germ cell antigens from accessing the immune system, is maintained and repaired by testosterone <sup>(23)</sup>. Aspirin caused significant decrease in testosterone levels.

### **Hormonal changes associated with Aspirin Follicle-Stimulating hormone (FSH)**

Table 4-6  
Effect of Aspirin on FSH hormone in studied groups

Groups	FSH hormones	
Group1 Control	89.69 ± 1.02	A
Group 2	54.06 ± 1.15	B
Group 3	10.65 ± 0.71	C

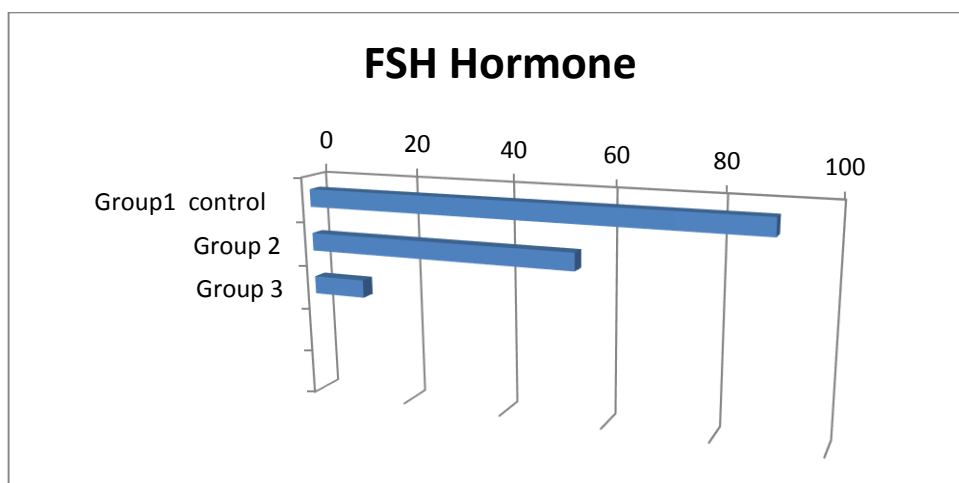


Figure4-6. FSH hormone changes associated with aspirin administration to rat at concentration (25 mg/kg body weight twice/day) and (50 mg/kg body weight twice/day). Significant differences ( $p \leq 0.05$ )

In experimental group 1 a significant decrease ( $p \leq 0.05$ ), decrease was seen in FSH level in experimental group 2 as compared to the control (Figure. 2). The using of aspirin in dose of 25 mg /kg /body weight and 50 mg/Kg/body weight for 30 day lead to significant decrease in the level of FSH hormone compare with group 1( control group) . In experimental control group (group 1) the level of FSH hormone ( $89.69 \pm 1.02$ ) (mIu) compare with group 2 and group 3 ( $54.06 \pm 1.15$ ) ( $10.65 \pm 0.71$ ). Aspirin therapy resulted in a considerable drop in both FSH and TSH, according to several publications <sup>(24)</sup>. The inhibition of PGE2 in the hypothalamus by aspirin is thought to be the cause of this drop. When aspirin is given at a high dose (like we do), this effect appears to be produced through reduction of GnRH release <sup>(25)</sup>.

### **The effect of Aspirin on Histopathological examination**

Testis is composed of seminiferous tubules and interstitial tissues. Male germ cells, Sertoli cells, and Myoid cells are found in seminiferous tubules, while Leydig cells are found between neighboring seminiferous tubules<sup>(26)</sup>.

#### **Group 1 Control Testis (A)**

The parenchyma of the testis we occupied with many Seminiferous tubule, Each tubule we lined by basement membrane and delicate connective tissue, the cells which are resting on the basement membrane were spermatogonia, the first row and the second row new primary spermatocyte, then two rows of secondary spermatocyte, then the spermatide nearly the center of lumen of seminiferous tubule, and the center of each tubule we filled with spermatozoa. The interstitial connective tissue had group, and leydic cells. The testis we coated with dense connective tissue capsule and great blood vessels were present sub capsular location with blood congestion inside lumen and these blood vessels.

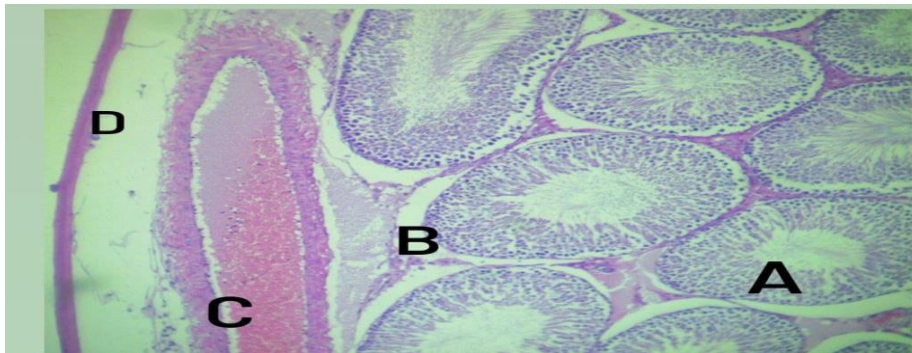


Figure 4-12. A histological picture of the testis shows the seminiferous tubules of the Group 1 ( control group ). (Haematoxylin and Eosin X10)

Seminiferous tubule with Different stage of Spermatogenic development (A)  
Basement membrane (B) Congested blood vessels (C) capsule (d).

### Group 2 Testis (A)

The parenchyma of testis had disorganized Seminiferous tubule, with presence & thickening the basement membrane, the leydig cells in between S. N. T Were mostly atrophied and present a way from the walls of S. N. T s. Blood congestion we demonstrated For the interstitial blood vessels.

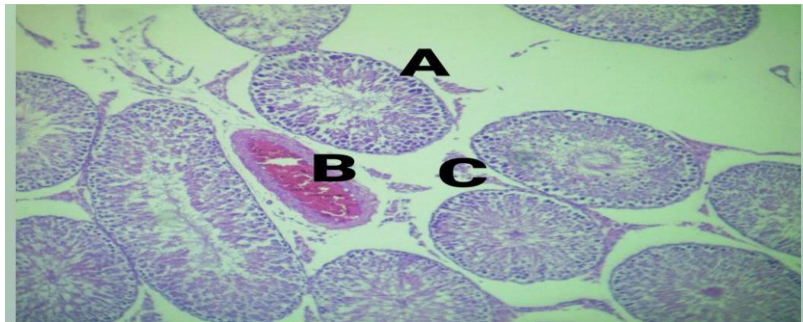


Figure 4-15. A histological picture of the testis treated with (25 mg/kg of B.W.) aspirin shows the seminiferous tubules of the experimental group 2.(Haematoxylin and Eosin X10)

Disorganization of S. N. T s, thickening of Basement membrane (A).Blood congestion of Blood vessels (B). Atrophy of leydig cell (C)

### Group 3 Testis (A)

The parenchyma of testis we occupied by many Seminiferous tubule, Certain number of these tubule were containing degenerated spermatogenic cells in the lumen os S. N. T s, and the interstitial connective tissue had many congested blood vessels, also the interstitial connective tissue had inflammatory odema , mostly around the leydig cells.

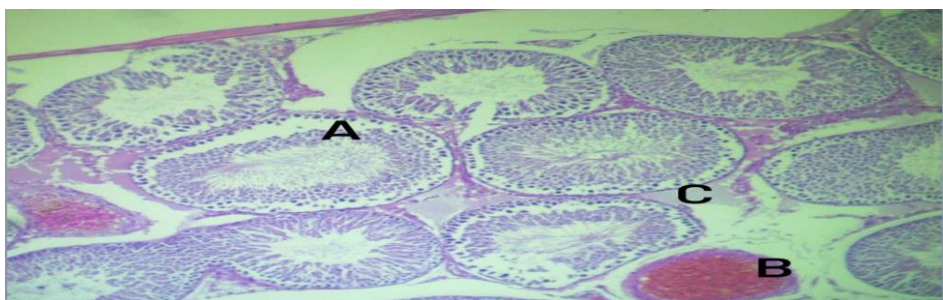


Figure 4-19. A histological picture of the Testis treated with (50 mg/kg of B.W.) aspirin shows the seminiferous tubules of the experimental group 3. (Haematoxylin and Eosin X10)

Degenerated spermatogenic cell (A) interstitial blood vessels congestion (B) Thickening of basement membrane (C).

### Group 1 Control Epididymis (A)

The efferent ductile of epididymis were enriched with a masses of spermatozoa, the basement membrane of each ductile we lined by simple Cuboidal cells. The interstitial connective tissue we loose and continuous with capsule of epididymis which formed by dense connective tissue.

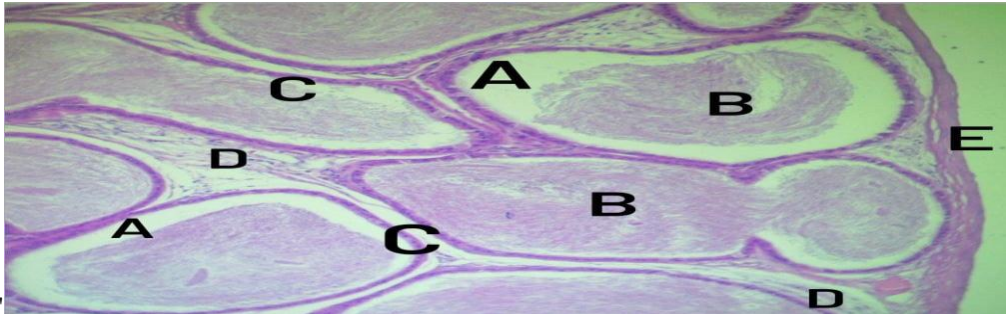


Figure 4-23. A histological picture of the epididymis shows of the Group 1 (control group). (Haematoxylin and Eosin X10)

Efferent ductuli (A) mass of spermatozoa (B) cuboidal epithelium (c) interstitial connective tissue (D) Capsule (E)

### Group 2 Epididymis (A)

The epididymal Canal we Formed by many epididymal ductali, Each one we lined by Simple Columnar Pseudo stratified columnar epithelium . With presence masses of spermatozoa in the lumen of that ductali. the interstitial connective tissue we Formed by Fibrous Collagenous connective tissue which have the blood Vessels and Fibroblast.

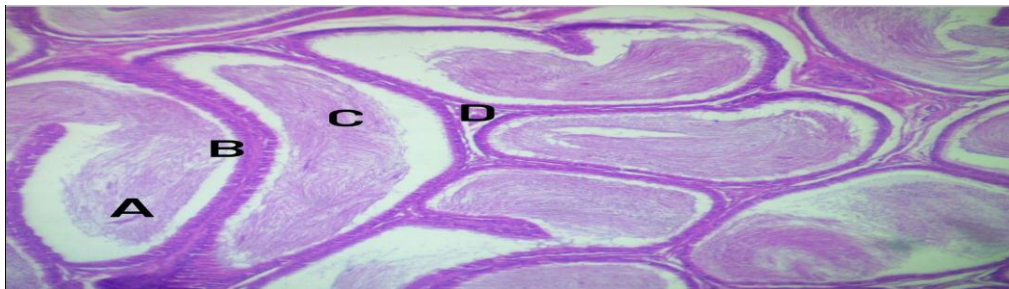


Figure4-25. A histological picture of the epididymis treated aspirin (25 mg/kg of B.W) of the experimental group 2. (Haematoxylin and Eosin X 40).

Epididymial Canal, epididymal ductale (A). epithelial lining (B). Spermatozoa masses (C). Interstitial Connective tissue (D).

### Group 3 Epididymis (A)

The efferent ductile of epididymis were filled with masses of spermatozoa and the lining epithelium were containing degenerated cell, the dense connective tissue

below the epithelium we containing many vacuole and the Collagen bundle, around the ductile were loose, surrounded by adipose tissue from outside.

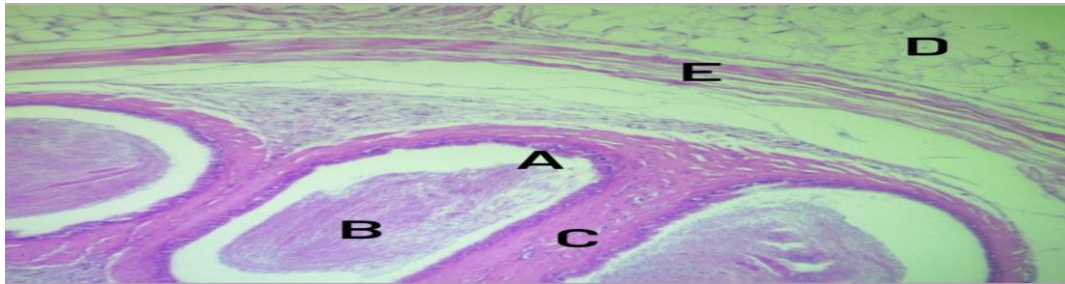


Figure 4-31. A histological picture of the epididymis treated aspirin (50 mg/kg of B.W) of the experimental group 3. (Haematoxylin and Eosin X 10)

Degenerated epithelium Cells (A).masses of spermatozoa (B). Loose connective tissue around the efferent ductile(C).Adipose tissue (D).around the Capsule (E).

#### **Group 1 Control vas difference (A)**

The tubular structure of vas difference was arranged in a thick wall , mostly formed by fibro \_ muscular structure or coat ,the lumen of difference is thrown in folded mucosa ,lined with simple \_pseudo \_stratified columnar epithelium ,surrounded with lamina propria of dense C.T around the epithelium , the lumen with containing a quantity of spermatozoa , the whole duct was covered with loose C.T.

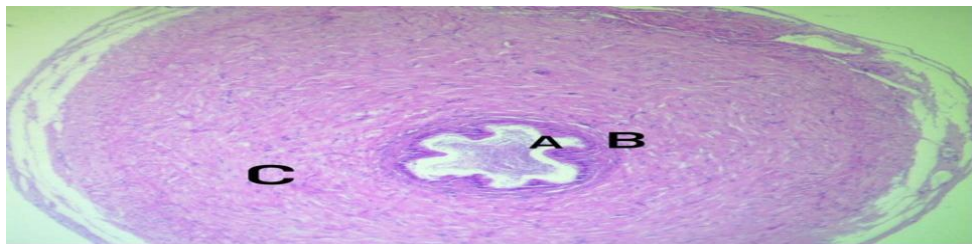


Figure 4-35. A histological picture of the Vas deference shows of the Group 1 (control group). (Haematoxylin and Eosin X10)

Mucosal epithelium fold (A). lamina proparia (B).thick Fibro muscular Coat(C). Mass of spermatozoa (D)

#### **Group 2 Vas deference (A)**

The duct we filled with masses of spermatozoa in its lumen, and the epithelium we lining the lumen we arranged without enfolding. The Fibro muscular Coat we containing many space, the Capsule of duct we contracted from the Fibro muscular Coat.

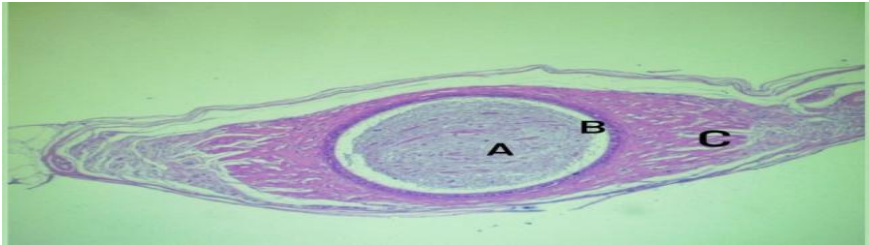


Figure 4-37. A histological picture of the Vas deference treated aspirin (25 mg/kg of B.W) of the experimental group 2. (Haematoxylin and Eosin X 10)

Mass of Spermatozoa (A). Epithelial Lining (B).Space between Fibro Muscular coat (C).

### Group 3 Vas deference (A)

The mucosal fold of vas deference had degenerated epithelium and the basal surfaces Of these cell , were desqurated from its basement membrane , the fibro muscular coat around the lumen we thick and few vacillation were seen in between the collagen bundle.

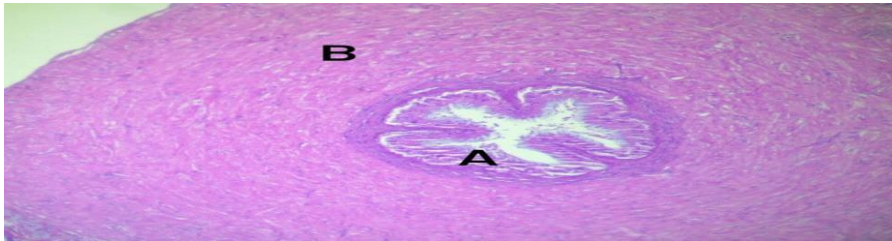


Figure 4-40. A histological picture of the Vas deference treated aspirin (50 mg/kg of B.W) of the experimental group 3. (Haematoxylin and Eosin X 10)

Degeneration of mucosal epithelium (A). Vacuolation of fibro muscular coat (B)

### Group 1 Control Seminal vesicle (A)

The lobule of the gland we formed by great follicle these follicle filled its cavities with seminal fluid which appeared homogenized esinophilic texture ,the follicle were lined with folded epithelium the interstitial connective tissue we formed by collagen fibers of smooth muscle fibers.

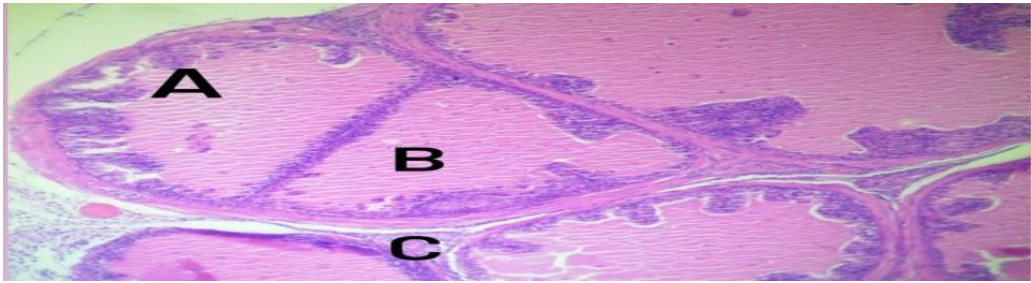


Figure 4-44. A histological picture of the Seminal vesicle shows of the Group 1 (control group). (Haematoxylin and Eosin X10)

Mucosal epithelial Fold (A) Seminal homogenized eosinophilic Fluid (B) interstitial Connective tissue (C).

### Group 2 Seminal vesicle (A)

The lobule of the Seminal vesicle were great in its lumen, filled with homogenized secretion of Seminal , eosinophilic fluid, the epithelium lining the lobule were discontinuous and broken down , Aggregation and WBC. we demonstrated and focal aggregation , the small blood vessels around the gland were congested with blood .

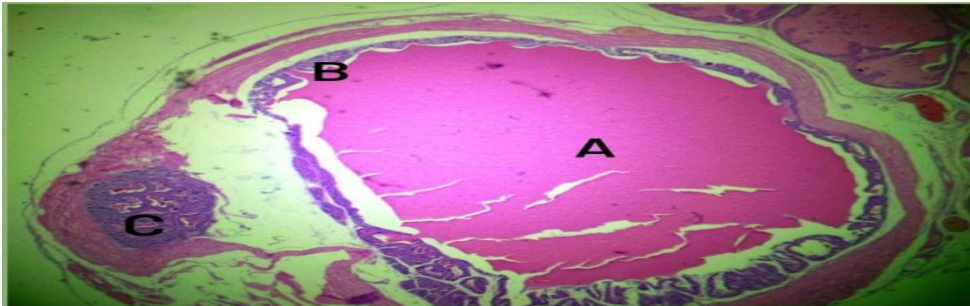


Figure 4-46. A histological picture of the Seminal vesicle treated aspirin (25 mg/kg of B.W) of the experimental group 2. (Haematoxylin and Eosin X 10)

Seminal vesicle lobule of Seminal vesicle homogenized Secretion of gland (A). Breaking down of epithelium (B) WBCs Aggregation (c)

### Group 3 Seminal Vesicle (A)

The follicles and seminal vesicle were filled with seminal secretion which we appeared homogenized eosinophilic fluid , the mucosal fold had epithelial cells projected to the lumen of follicle , loose Connective tissue we investing the gland from outside which we containing blood vessel.

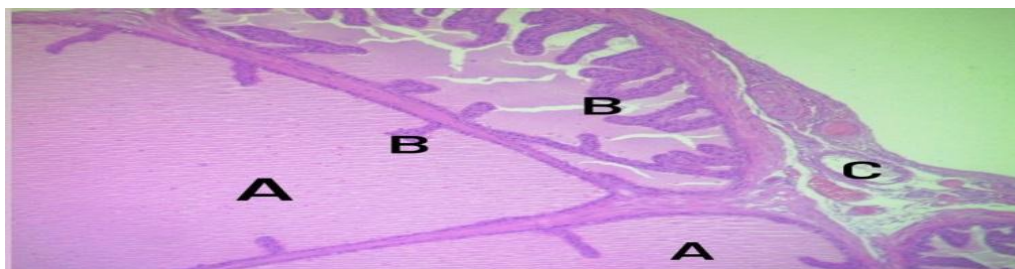


Figure 4-50. A histological picture of the Vas deference treated aspirin (50 mg/kg of B.W) of the experimental group 3. (Haematoxylin and Eosin X 10).

Follicle of Seminal vesicle filled with Seminal secretion (A). Mucosal fold (B). Blood vessels (C). Aspirin-treated Group 3 rats had cytological and nuclear degenerative alterations in their seminiferous tubules, resulting in tubule shrinkage. <sup>(27)</sup>Sertoli cells, Leydig cells, primary spermatogonia, secondary spermatogonia, and spermatocytes were all reduced. These findings point to aspirin's degenerative and retrogressive effects on the testes in rats. Sertoli cells are the most critical cells in seminiferous tubules because germ cell proliferation is dependent on them, and they provide sustenance to proliferating germ cells, including them. Sertoli cells play a role in spermatid discharge into the lumen of seminiferous tubules <sup>(28)</sup>. The testicular vasculature is regulated by the blood testes barrier <sup>(29)</sup>. Sertoli cells play a critical function in the nutrition of germ cells and the maintenance of a microenvironment that is necessary for optimal growth <sup>(30)</sup>. Sertoli cells, germ cells, seminiferous tubules, and Leydig cells were ablated, resulting in a reduction in testicular size <sup>(31)</sup>. In vitro and in vivo experiments revealed that a high dose of aspirin killed blood vessel tissue. Aspirin inhibits continuous prostaglandin synthesis, which causes unopposed arteriole constriction, ischemia of tubules, and epithelial cell death <sup>(30,31)</sup>.

## Conclusion

Aspirin is a widely used drug in both human and veterinary medicine around the world. However, aspirin toxicity has a negative impact on male blood chemistry and reproductive effectiveness. As a result, it is recommended that aspirin be used with caution.

## References

1. SedeeqBI, Sarhat ER , Wade SA, Sarhat TR , Abass KS.Effects of Indomethacin Administration on Some Biochemical and Brain Histological Changes in Male Rats. *Indian Journal of Forensic Medicine & Toxicology*.2021;15( 3): 2127-2135.
2. Entedhar Rifaat Sarhat, Siham Ajmee Wadee, Ban Ismael Sedeeq, Thuraia Rifaat Sarhat, , Kasim Sakran Abass. Biochemical and Histological Evaluation of Indomethacin-induced Hepatotoxicity in Rats. *P J M H S*,2021; 15(4): 1038-1043.
3. Wu K. Aspirin and salicylate. *Circulation*. 2000;102:2022-2023.
4. Entedhar Rifaat Sarhat, Siham Ajmee Wadee, Ban Ismael Sedeeq, Thuraia Rifaat Sarhat, , Kasim Sakran Abass. Biochemical and Histological

- Evaluation of Indomethacin-induced Hepatotoxicity in Rats. *P J M H S*,2021; 15(4): 1038-1043.
5. Salim J.Khalaf, adeer Hatem Aljader, Entedhar R. Sarhat et al. Antidiabetic effect of Aqueous Extract of Medicago Sativa withEnhanced Histopathology of Pancreas in Alloxan Induced DiabeticRats. *P J M H S*.2021;15( 2);:492-496.
  6. Kurumbail RG, Stevens AM, Gierse JK, McDonald JJ, Stegeman RA, Pak JY, et al. Structural basis for selective inhibition of cyclooxygenase-2 by anti-inflammatory agents. *Nature*. ENGLAND; 1996 Dec;384(6610):644-648.
  7. Alvarez-Larran A, Pereira A, Guglielmelli P, Hernandez- Boluda JC, Arellano-Rodrigo E, Ferrer-Marin F, et al. Antiplatelet therapy versus observation in low-risk essential thrombocythemia with CALR mutation. *Haematologica*. 2016 May;8.
  8. Klessig DF, Tian M, Choi HW. Multiple Targets of Salicylic Acid and Its Derivatives in Plants and Animals. *Front Immunol*. Switzerland; 2016;7:206.
  9. Ibtisham F, Yangfen N, Wang Z, Wu J, Xiao M, An L. Animal Cloning Drawbacks An-Overview. *J Dairy Vet AnimRes [Internet]*. 2016;3(4):3-7.
  10. Khalid G. Washeel, Entedhar R. Sarhat, Talal H. Jabir. Assessment of melatonin and oxidant-antioxidant markers in infertile men in Thi-Qar Province. *Indian Journal of Forensic Medicine & Toxicology*, .2019.13( 4) . 1495- 1499.
  11. Roodbari F, Abedi N, Talebi AR. Early and late effects of Ibuprofen on mouse sperm parameters, chromatin condensation, and DNA integrity in mice. *Iran J Reprod Med [Internet]*. Yazd, Iran: Research and Clinical Center for Infertility; 2015 Nov 29;13(11):703-710.
  12. Ahmadi R, Ahmadifar M, Safarpour E, Vahidi-Eyrisofla N, Darab M, Eini AM, et al. The Effects of Levofloxacin on Testis Tissue and Spermatogenesis in Rat. *Cell J*. Iran; 2016;18(1):112-116.
  13. Lara NLM, Santos IC, Costa GMJ, Cordeiro-Junior DA, Almeida ACG, Madureira AP, et al. Duration of spermatogenesis and daily sperm production in the rodent *Proechimys guyannensis*. *Zygote*. 2016 Jun;1-11.
  14. Hasanin NA, Sayed NM, Ghoneim FM, Al-Sherief SA. Histological and Ultrastructure Study of the Testes of Acrylamide Exposed Adult Male Albino Rat and Evaluation of the Possible Protective Effect of Vitamin E Intake. *J Microsc Ultrastruct*. 2018;6(1):23-34. doi:10.4103/JMAU.JMAU\_7\_18
  15. Entedhar Rifaat Sarhat, Siham A. Wadi, B.I. Sedeeq, Th.R. Sarhat and N.A. Jasim.Study of histopathological and biochemical effect of Punica granatum L. extract on streptozotocin -induced diabetes in rabbits .*Iraqi Journal of Veterinary Sciences*,2019. 33( 1):189-194.
  16. Entedhar Rifaat Sarhat, Siham A. Wadi, Ayhan R. Mahmood .Effect of Ethanolic Extraction of Moringa oleifera on Paraoxonase and Arylesterase enzyme activity in High Fat Diet-induced Obesity in Rats. *Research J. Pharm. and Tech*.2018; 11(10): 4601- 4604
  17. Didolkar AK, Gurjar A, Joshi UM, Sheth AR, Roychowdhury D. Effects of aspirin on blood plasma levels of testosterone, LH and FSH in maturing male rats. *Int J Androl*. DENMARK; 1980 Jun;3(3):312-318.
  18. Mazaud-Guittot S, Nicolaz CN, Desdoits-Lethimonier C, Coiffec I, Maamar M Ben, Balaguer P, et al. Paracetamol, aspirin, and indomethacin induce endocrine disturbances in the human fetal testis capable of interfering with testicular descent. *J Clin Endocrinol Metab*. 2013;98(11):1757-1767.

19. Lyon MF, Glenister PH, Lamoreux ML. Normal spermatozoa from androgen-resistant germ cells of chimaeric mice and the role of androgen in spermatogenesis. *Nature*. ENGLAND; 1975 Dec;258(5536):620-622.
20. . O'Shaughnessy PJ, Morris ID, Huhtaniemi I, Baker PJ, Abel MH. Role of androgen and gonadotrophins in the development and function of the Sertoli cells and Leydig cells: data from mutant and genetically modified mice. *Mol Cell Endocrinol*. Ireland; 2009 Jul;306(1-2):2-8.
21. El-Sharaky AS, Newairy AA, Elguindy NM, Elwafa AA. Spermatotoxicity, biochemical changes and histological alteration induced by gossypol in testicular and hepatic tissues of male rats. *Food Chem Toxicol* [Internet]. 2010 Dec;48(12):3354-3361.
22. De Gendt K, Swinnen J V, Saunders PTK, Schoonjans L, Dewerchin M, Devos A, et al. A Sertoli cell-selective knockout of the androgen receptor causes spermatogenic arrest in meiosis. *Proc Natl Acad Sci U S A*. United States; 2004 Feb;101(5):1327-132.
23. Meng J, Holdcraft RW, Shima JE, Griswold MD, Braun RE. Androgens regulate the permeability of the blood-testis barrier. *Proc Natl Acad Sci U S A*. United States; 2005 Nov;102(46):16696-16700.
24. Al-Rubae, E. A. (2005). Effect of Alcoholic Extract of Fenugreek Seeds on Fertility in Albino Male Mice. MSc Thesis, University of Baghdad, College of Science for Women, University of Baghdad.
25. Yen-s, S. C.; Jaffe, R. B. and Barbieri, R. L. (1999). Reproductive endocrinology. Physiology, pathophysiology and clinical management. 4th Ed. W.B. Saunders Company. *Biol. Reprod.*, 54: 1347-55.
26. Elftman H. Sertoli cells and testis structure. *Am J Anat* [Internet]. Wiley Subscription Services, Inc., A Wiley Company; 1963;113(1):25-33. Available from: <http://dx.doi.org/10.1002/aja.1001130104>.
27. Asok Kumar R, Chinoy NJ. Effects of acetylsalicylic acid on reproductive organs of adolescent male rats. *Endocrinol Exp*. CZECHOSLOVAKIA; 1988 Sep;22(3):187-195.
28. Hai Y, Hou J, Liu Y, Liu Y, Yang H, Li Z, et al. The roles and regulation of Sertoli cells in fate determinations of spermatogonial stem cells and spermatogenesis. *Semin Cell Dev Biol* [Internet]. Elsevier Ltd; 2014;29:66-75. Available from: <http://dx.doi.org/10.1016/j.semcdb.2014.04.007>.
29. Rebourcet D, Wu J, Cruickshanks L, Smith SE, Milne L, Fernando A, et al. Sertoli cells modulate testicular vascular network development, structure and function to influence circulating testosterone concentrations in adult male mice. *Endocrinology*. 2016 May;en20161156.
30. Marettova E, Maretta M, Legath J. Toxic effects of cadmium on testis of birds and mammals: a review. *Anim Reprod Sci*. Netherlands; 2015 Apr;155:1-10.
31. Li N, Mruk DD, Lee WM, Wong CKC, Cheng CY. Is toxicant-induced Sertoli cell injury in vitro a useful model to study molecular mechanisms in spermatogenesis? *Semin Cell Dev Biol* [Internet]. Elsevier Ltd; 2015;1-16. Available from: <http://dx.doi.org/10.1016/j.semcdb.2016.01.003>