

How to Cite:

Manjani, S., Vijayamalathi, M., Ranjini, S. S., Janaki, C. S., & Arulparithi, C. S. (2022). Estrogen and progesterone receptor expression: An immunohistochemical study of endometrial lesions in perimenopausal age group. *International Journal of Health Sciences*, 6(S2), 11336–11342. <https://doi.org/10.53730/ijhs.v6nS2.8044>

Estrogen and progesterone receptor expression: An immunohistochemical study of endometrial lesions in perimenopausal age group

Dr. S. Manjani

Associate Professor, Department of Pathology Bhaarith Medical College and Hospital (BIHER)

Dr . M. Vijayamalathi

Associate Professor, Department of Physiology, Bhaarith Medical College and Hospital (BIHER)

Dr. S. Sree Ranjini

Professor & HOD, Department of Anaesthesiology, Bhaarith Medical College and Hospital (BIHER)

Dr. C. S. Janaki

Associate Professor, Department of Anatomy, Bhaarith Medical College and Hospital (BIHER)

Dr. C. S. Arulparithi*

Associate professor, Department of Paediatrics, Vinayaga Mission Medical College, Karaikal

*Corresponding Author

Abstract---Background: The common gynaecological complaints encountered is dysfunctional uterine bleeding .Pipelle aspiration & Dilatation and curettage is done to find out the Histomorphological and its immunohistochemical alterations. Objective : This study aims to bring out the expression of Estrogen and Progesterone receptor in perimenopausal women of non-malignant and malignant endometrium presenting with menorrhagia. Result: Endometrial samples of 41 Perimenopausal women with AUB were also subjected to immunohistochemical staining to find out the Estrogen and Progesterone receptor status. Immunohistochemistry revealed the mean of PI values for ER and PR were highest in the proliferative endometrium (91.64% for ER; 94.38% for PR) followed by simple hyperplasia, complex hyperplasia, atypical hyperplasia and endometrial carcinoma (27.5% for ER; 27% for PR). Conclusion: Immunohistochemistry results in perimenopausal women show that

the estrogen and progesterone receptor expression decreases progressively from proliferative endometrium to hyperplasias to endometrial carcinoma.

Keywords---AUB, estrogen receptor, progesterone receptor.

Introduction

The histopathological with its immunohistochemical evaluation of the endometrium gives better understanding of the hormonal disturbances underlying dysfunctional uterine bleeding and serve as an important prognostic indicator. These Receptor expression therefore helps in targeted hormone therapies. In the reproductive period, the normal cyclical physiological changes are controlled by the cyclical release of estrogen and progesterones from the (Robert J. Kurman, 2011). In endometrial carcinoma the estrogen and progesterone receptors expression, is an independent prognostic marker. Liao et al reported that, the prognosis of patients with nodal metastasis has been favourable with a low ER receptor positivity. Among the two, PR appears to be a stronger predictor of survival than ER. the higher the level, the better the prognosis(4).

Aims and Objectives

To find out Estrogen and Progesterone Receptor status of non-malignant and malignant endometrium in the Perimenopausal age group.

Material and methods

Histopathologically categorised as non malignant, precursor lesion and endometrial carcinomas of 41 cases of perimenopausal women blocks were further processed for immunohistochemistry. The standard antigen retrieval method was used (HRP AND TRIS EDTA) and analysed for positivity of receptors in the glandular epithelium in a 4micron thick sections.

Statistical Methods

Patients were categorised as perimenopausal age group as per standards (41-50 yrs.), for statistical analysis spss software version 6 has been used. Statistical analysis has been represented in tables and figures.

Result

Table:1 Glandular Epithelial Expression Of Both The Receptor

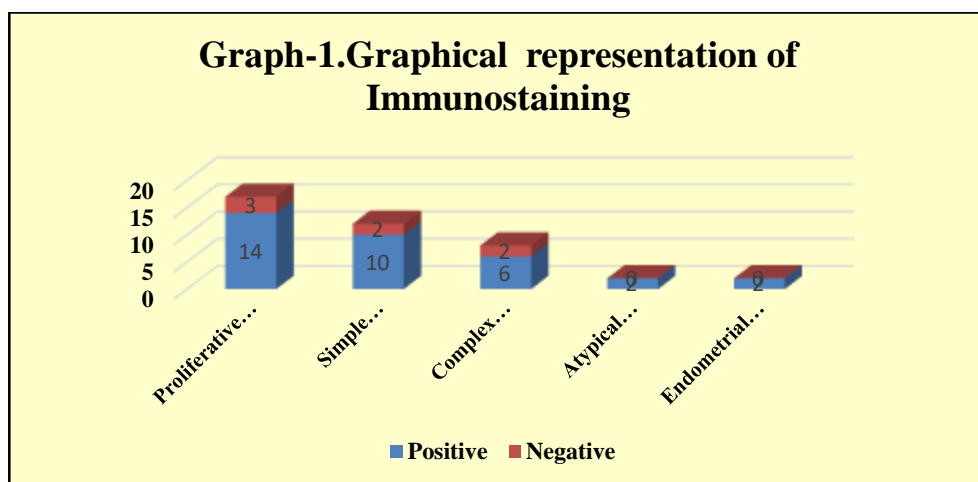
Immunostaining	ER				PR			
	Positive		Negative		Positive		Negative	
Endometrial changes	N	%	N	%	N	%	N	%
Non-malignant	32	94.1	7	100	31	96.9	8	88.9
Malignant	2	5.9	0	0	1	3.1	1	11.1

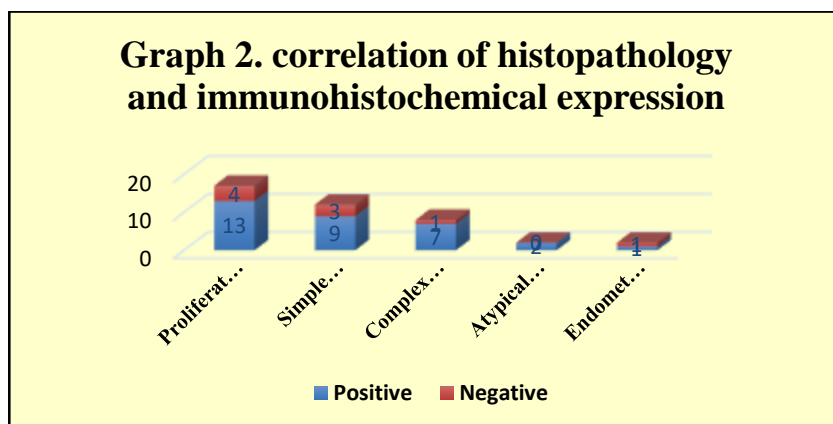
Total	34	100	7	100	32	100	9	100
-------	----	-----	---	-----	----	-----	---	-----

The endometrial adenocarcinoma were positive for both ER and PR, whereas in the remaining 39 cases of non-malignant endometrium 32 (94.1%) cases were positive for ER and 31 (96.9%) cases were positive for PR.

Table 2: Correlation between Histopathological and immunohistochemical expression

Immunostaining Histopathologic finding	ER		PR	
	N	% of positive cases	N	% of positive cases
Proliferative endometrium	14/17	82.35	13/17	76.47
Simple Hyperplasia	10/12	83.33	9/12	75.00
Complex Hyperplasia	6/8	75.00	7/8	87.50
Atypical hyperplasia	2/2	100.00	2/2	100.00
Endometrial adenocarcinoma	2/2	100.00	1/2	50.00
Total	33/41	80.49	32/41	78.05



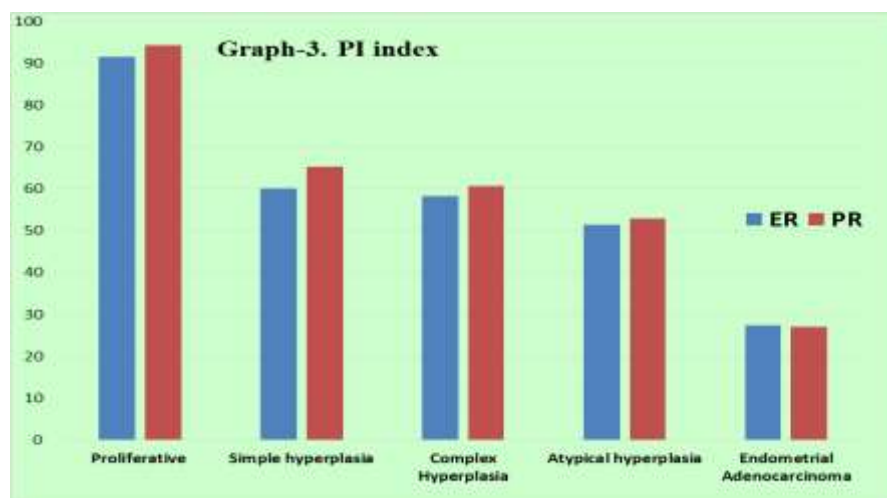


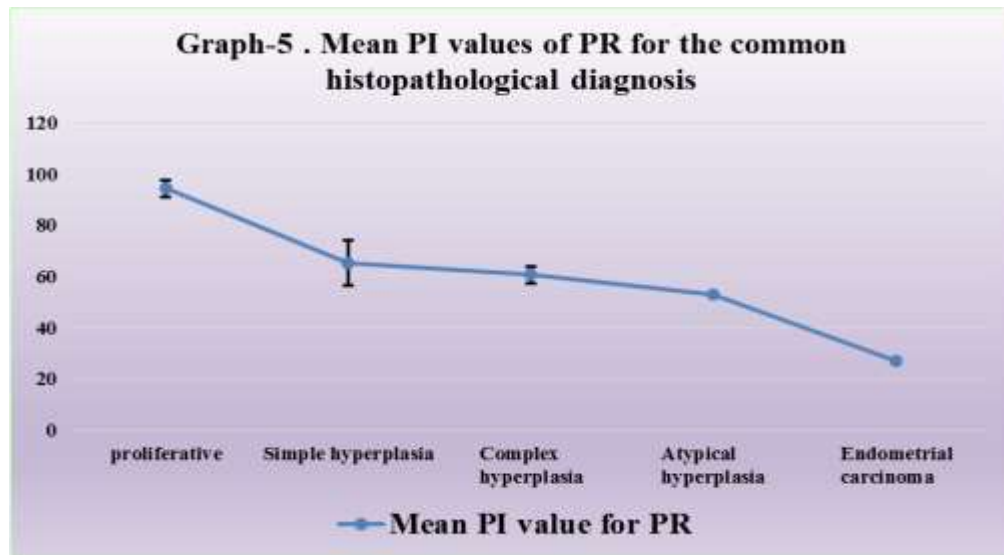
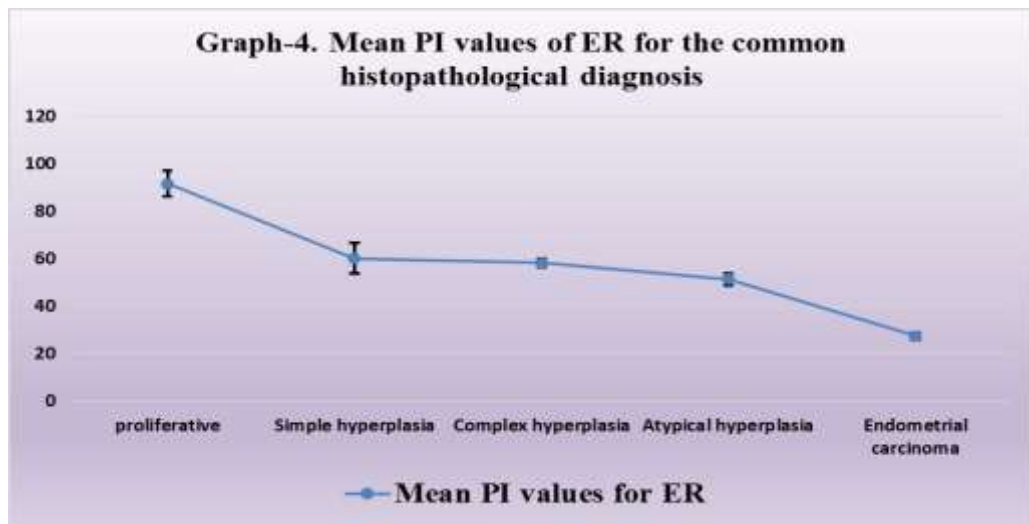
ER and PR positivity was noted in both hyperplasia with atypia and carcinoma. 82.35% were positive for ER and 76.47% were positive for PR in non malignant and hyperplasia without atypia . The percentage of cases showing positivity for ER and PR are respectively 83.33% and 75%.,the percentage of cases positive for ER and PR are respectively 75% and 87.5% in simple and complex respectively

Table 3: PI index

S.No	Histopathological diagnosis	ER			PR		
		N	PI-ER %	P	N	PI- PR %	P
1	Proliferative	14	91.64	<0.0001	13	94.38	<0.0001
2	Simple hyperplasia	10	60.20		9	65.33	
3	Complex Hyperplasia	6	58.33		7	60.71	
4	Atypical hyperplasia	2	51.50		2	53.00	
5	Endometrial Adenocarcinoma	2	27.50		1	27.00	

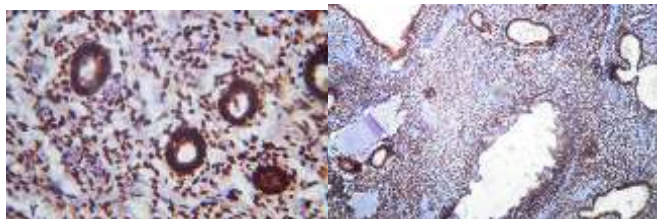
* PI- percentage index



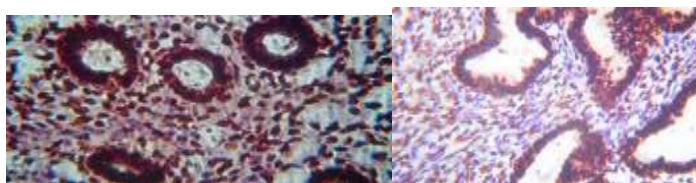


To calculate the mean PI value the number of positively stained cells were divided by the total number of cells counted. Percentages were calculated individually for the two categories of cases. The mean PI index of Receptors in the descending order was found to be for proliferative endometrium (91.64%&94.38%) followed by simple hyperplasia (60.20%), complex hyperplasia (58.33%), atypical hyperplasia (51.5%) and lowest pi for endometrial carcinoma (27%). The significant differences between the mean PI values for ER and PR of the three common categories that is the proliferative pattern, hyperplasia without atypia (simple and complex) by one way analysis variance is highly significant ($p < 0.0001$).

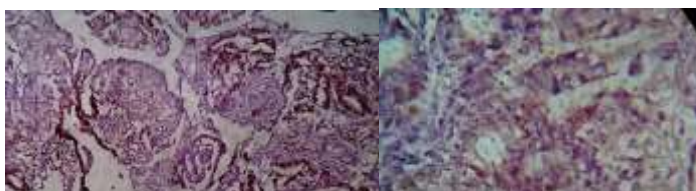ER&PR-strong and intense nuclear positivity.(Proliferative endometrium)



ER &PR -Moderate positivity(Hyperplasia without atypia)



ER &PR -Weak Positivity (Endometrial adenocarcinoma)



Discussion

ER and PR immunohistochemical staining between non-malignant endometrium and malignant endometrium. Most of non-malignant endometrium showed positivity for estrogen receptors (94.1%) and progesterone receptors (96.9%). Quantitative analysis revealed that the mean of the Percentage Index of all the proliferative endometrium was the highest (91.64% for ER and 94.38% for PR) followed by hyperplasia without atypia and atypical hyperplasia. In endometrial adenocarcinoma (27.5% for ER and 27% for PR), the mean of the PI values for both ER and PR were the lowest with mild PR preponderance corresponding to the study conducted by Mylonas et al (6) & Daniela Ilie et al (7) the receptor expression normal in non malignant and declining in carcinomas

But a deviation was noted among hyperplasia From Daniel ille et all (6) The mean PI for ER and PR was high in case of complex hyperplasia without atypia (mean PI for ER 72.3%; mean PI value for PR of 78.5%) followed by atypical hyperplasia and simple hyperplasia. In the present study simple hyperplasia has high mean PI value (60.2% for ER; 65.33% for PR) followed by complex hyperplasia and atypical hyperplasia in that order. Similarity was observed in endometrial adenocarcinoma in both the studies. In The qualitative study by Sahar Aly Daoud et al (8) expression of ER and PR immunostaining in normal and hyperplastic endometrium with that of malignant endometrium, Total 28 cases of

non-malignant endometrium 22 (78.57%) were positive for ER and 19 (67.85%) were positive for PR. Out of 26 endometrial carcinoma, 14 (70%) were positive for ER and 12 were positive for PR (60%)

Conclusion

Immunohistochemistry analysis of ER and PR shows that there is a progressive decrease in positivity from cyclical endometrium, Hyperplasia to Adenocarcinoma. Thus we conclude that receptor expression is of prognostic significance and PR positivity helps to decide upon hormonal therapy in women in order to retain the fertility and minimise the surgery.

References

1. Ayman A A Ewies, Kadry A A Shaaban, Reena Merard, Ulises Zanetto. Endometrial biopsy in women with abnormal uterine bleeding: inadequate and unassessable categorisation is not clinically relevant. *J Clin Pathol*, 67 (2014), 673-677.
2. Kennedy MM, Baigrie CF, Manek S. Tamoxifen and the endometrium: review of 102 cases and comparison with HRT related and non-HRT related endometrial pathology. *Int J Gynecol Pathol*, 18 (1999), 130-137.
3. Ferenczy, Alex. Pathophysiology of endometrial bleeding. *Maturitas The European Menopause Journal*, 45 (2003), 1-14.
4. Jonathan S. Berek, MD, MMS, Neville F. Hacker, AM, MD. *Berek & Hacker's Gynecologic Oncology*. 2015.
5. Robert J. Kurman, Richard W. TeLinde. *Blaustein's Pathology of the Female Genital Tract*. 2011.
6. I. Mylonas, U. Jeschke, N. Shabani, C. Kuhn, S. Kriegel, M. S. KUPKA And K. Friese. Normal and Malignant Human Endometrium Express Immunohistochemically Estrogen Receptor Alpha (ER α), Estrogen Receptor Beta (ER β) and Progesterone Receptor (PR). *Anticancer Research*, 25 (2005), 1679-1686.
7. Daniela Ilie, claudia Valentina Georgescu, Cristiana Simionescu, Anca Daniela Braila, M. Braila. Immunohistochemical Aspects of Endometrium Hyperplasias in Perimenopause. *Current Health Sciences Journal*, 37, 2 (2011).
8. Sahar Aly Daoud, Hala Naguib Hosni and Amal Ahmed Hareedy. Immunohistochemical Expressions of ER, PR and ALDH1 in Endometrial Hyperplasia and Carcinoma. *Journal of American Science*, 9, 12 (2013).