

**How to Cite:**

Pulluru, U. R., Chelli, S. B., Sthevaan, V., & Sumathy, G. (2022). Histomorphometrical changes of placenta in fetal growth restriction. *International Journal of Health Sciences*, 6(S3), 11200–11025. <https://doi.org/10.53730/ijhs.v6nS3.8622>

## **Histomorphometrical changes of placenta in fetal growth restriction**

**Upendhar Reddy Pulluru**

Ph.D. Scholar, Bharath Institute of Higher Education and Research, Chennai, Tamil Nadu

**Sudhakara Babu Chelli**

Assistant Professor, MediCiti Institute of Medical Sciences, Medchal, Telangana

**Sthevaan V.**

HOD, Dept of Pathology, Palamur biosciences private limited, Mahabubnagar, Telangana

**Govindarajan Sumathy\***

Govindarajan Sumathy, Prof & HOD, Dept of Anatomy, Sree Balaji Dental College & Hospital, Chennai, Tamil Nadu

**Abstract**---Introduction: Fetal growth restriction (FGR) is a leading cause of perinatal morbidity and mortality, carrying a 20% recurrence rate. The placental disease is a cardinal factor among FGR underlying processes. The examination of the placenta in utero as well as postpartum, gives valuable information about the state of the fetal well-being. Material and methods: 50 placental samples from normal pregnancy and 50 FGR placental samples were taken after taking informed consent form. Placenta was washed thoroughly under tap water and observed for any macroscopic pathology. Results: Total no. of villi and volume of intervillous space was 76.57 % and 12.56% in FGR. Dense collagen fibers within villous stroma and around the fetal blood capillaries, significance increase in the mean number of syncytial knots & mean number of collagen fibers was observed in FGR group, when compared with normal group. Conclusion: More number of syncytial knots, dense collagen fibres within villous stroma and area of collagen fiber was significantly more in FGR when compared to normal. Macroscopic and microscopic examination is an accurate way to understand FGR for better management. Placental microscopic changes reflect severity of FGR which has big role in fetal growth.

**Keywords**---fetal growth restriction, histomorphometry, placenta, preeclampsia.

## Introduction

Fetal growth restriction (FGR) is a leading cause of perinatal morbidity and mortality, carrying a 20% recurrence rate. It is also known as intrauterine growth restriction (IUGR). The placental disease is a cardinal factor among FGR underlying processes<sup>1</sup>. The placenta is a unique characteristic of higher mammals which is attached to the uterus and is connected to the fetus through the umbilical cord. Researchers have, for a long time, emphasized the benefits which are associated with the anatomical examination of the placenta, an organ that is often disposed soon after parturition, without adequate examination<sup>2</sup>. The infant born with intrauterine growth retardation is recognized as having an increased risk of in utero mortality, neonatal morbidity and mortality, and long-term neurological complications<sup>3,4</sup>. Known causes of FGR can be traced in up to 40% of cases studied, including maternal diseases and fetal or placental factors<sup>5,6</sup>. The examination of the placenta in utero as well as postpartum, gives valuable information about the state of the fetal well being<sup>7</sup>.

## Materials and Methods

The study was conducted in the department of Anatomy at SVS Medical College, Mahbubnagar, Telangana after getting ethical committee clearance. 50 placental samples from normal pregnancy and 50 FGR placental samples were taken after taking informed consent form. Placenta was washed thoroughly under tap water and observed for any macroscopic pathology. Histomorphometry was done by using Leica LAS V4.12 software with the help of Leica DM 1000 LED microscope.

## Results

Microscope calibration lens was set 1 pixel (=1.07 microns). H& E stain as a part of routine staining and Masson's trichrome for collagen fibers was used in our study. Volume of total villi and volume of intervillous space was 76.57 % and 12.56% in FGR (Table-1). In normal placenta total villi volume was 82.46% and volume of intervillous space was 8.32%. original and processed image in LEICA microscope was given in figure1 & 1.1. where villi area shown in blue and intervillous space in green.

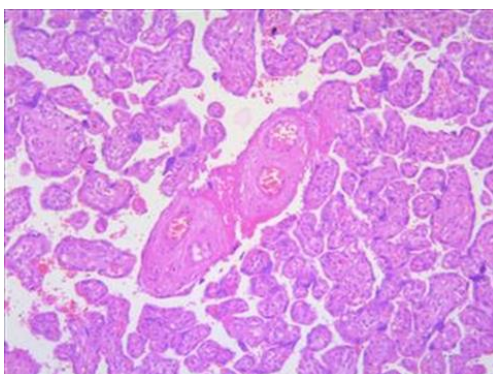


Fig 1. Original Image




Fig 1.1. Processed Image

Table 1  
Histomorphometry of placenta in normal and FGR

Parameters	Normal %	FGR %
Volume of total villi	82.46	76.57
Volume of intervillous space	8.32	12.56

In control group, with Masson's trichrome staining, delicate collagen fibres within villous stroma and around fetal blood capillaries were seen. In FGR, with Masson's trichrome staining, dense collagen fibers within villous stroma and around the fetal blood capillaries were observed (figure-2). Significance increase ( $P < 0.05$ ) in the mean number of syncytial knots were seen in FGR group (figure-3), when compared with normal group. Significance increase ( $p < 0.05$ ) in the mean number of collagen fibers was observed in FGR group (figure-4), when compared with normal group. The summary of nos of syncytial knots and area of collagen fibers are given in table-2.

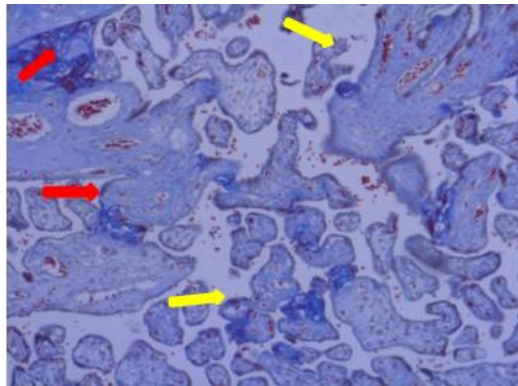


Fig 2. Masson's trichrome stain: A photomicrograph of a section in the human placenta of a FGR group showing dense collagen fibers within villous stroma (red arrow) and around fetal blood capillaries (yellow arrow)

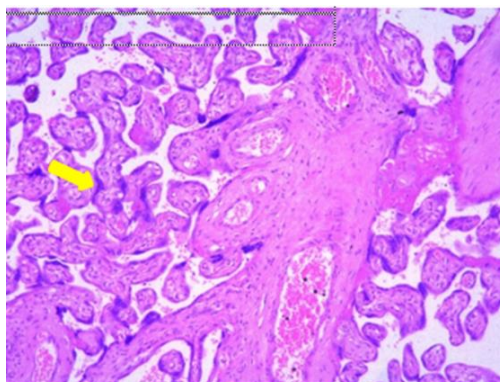


Fig 3. H & E stain: A photomicrograph of a section in the human placenta of a FGR group showing large number of syncytial knots (yellow arrow) around fetal blood capillaries

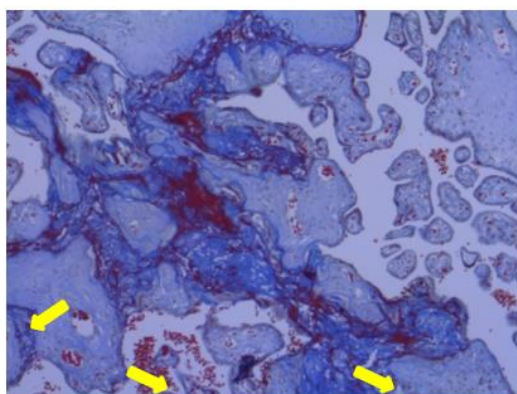


Fig. 4. Masson's trichrome stain: A photomicrograph of a section in the human placenta of a FGR group showing more amount of collagen fibers.

Table 2

Mean + SD values of syncytial knots and collagen fibers in cases and control

Parameters	Control (Mean + SD)	FGR (Mean + SD)
Number of syncytial knots	6 + 0.03	9.8 + 1.48
Area of collagen fibers	14 + 0.2	30 + 2.96

## Discussion

Teasdale F observed reduced surface area for exchange in IUGR placenta when compared to normal placenta. In IUGR placenta villous surface area, intervillous surface volume and peripheral capillary surface area are significantly less <sup>8</sup>. Our findings are contrast to the finding of the above author where we observed more intervillous volume in FGR in our study. Xu W et al postulated that placental smaller functional structures are related to development of IUGR. They observed smaller ratio of villi capillaries, surface area, absolute villi component and parenchymal tissue ratio <sup>9</sup>. In our study we observed reduced volume of total villi

in FGR. Biswas S et al observed reduced placental volume and weight in IUGR placenta than controls. They observed reduced mean surface area of villi in IUGR group which caused idiopathic intrauterine growth restriction <sup>10</sup>. Guven D et al observed volumetric densities of total villi, peri villous fibrin deposition, Intervillous vessels and syncytial knots which showed significant differences. In their study pre-eclampsia group showed increased volumetric parameters when compared to other study group <sup>11</sup>.

Khajuria et al studied placental weight hemorrhagic endovasculitis, infarction, chorionic villitis. Intervillous thrombosis, fibrinoid necrosis, placental intravascular thrombi, villous edema and perivillous fibrin deposition which were prevalent in IUGR than normal group. Intervillous fibrin deposition of 64% and basement thickening of 40% was seen in IUGR group in a study conducted by Mardi K et al <sup>13</sup>. In our study we observed more no of syncytial knots and more collagen fibres in FGR when compared to normal group. T.M Mayhew et al observed reduced intervillous space volume in IUGR which is associated with placental morphological changes <sup>14</sup>. Maly A et al found 5-fold decrease of villous vascular volume in pregestational diabetes mellitus and in preeclampsia the decrease was 1.6-fold. These findings in preeclampsia in absence of IUGR didn't differ significantly in their study <sup>15</sup>. Egbor M et al stated that FGR where its alone existence or with preeclampsia showed reduction in volumetric and terminal villous surface area with other vascular features. Terminal villous diameter was reduced significantly in FGR in their study<sup>16</sup>.

## **Conclusion**

Present study highlighted morphometrical differences between placenta of FGR and normal which were significant. Macroscopic and microscopic examination is an accurate way to understand FGR for better management. Placental microscopic changes reflect severity of FGR which has big role in fetal growth.

Funding: Nil

Conflict of interest: None

## **Acknowledgement**

We thank Dr. Sthevaan, HOD, Dept of Pathology, Palamur biosciences private limited, Mahabubnagar, Telangana for his support in support in histological procedures.

## **References**

1. Rotshenker-Olshinka K, Michaeli J, Srebnik N, Terlezky S, Schreiber L, Farkash R, Granovsky SG. Recurrent intrauterine growth restriction: characteristic placental histopathological features and association with prenatal vascular Doppler. Archives of gynecology and obstetrics. 2019 Dec;300(6):1583-9.
2. Kouvalainen K, Pynnonen Al, Makarainen M, Peltonen T. Weights of placental membranes and umbilical cord. Duodecim. 1971; 87:1210-1214.
3. Fox H. Pathology of the placenta. 2nd ed. London (UK): WB Saunders, 1997.

4. Lewis SH, Perrin E. Pathology of the placenta, 2nd ed. New York: Churchill Livingstone, 1999.
5. Hoffman H, Bakketeig I. Heterogeneity of intrauterine growth retardation and recurrence risks. *Semin Perinatol* 1984; 8: 15-24.
6. Ghidini A. Idiopathic fetal growth restriction: a pathophysiologic approach. *Obstet Gynecol Surv* 1996; 51: 376-82.
7. Kouvalainen K, Pynnonen Al, Makarainen M, Peltonen T. Weights of placental membranes and umbilical cord. *Duodecim*. 1971; 87:1210-1214.
8. Teasdale F. Idiopathic intrauterine growth retardation: histomorphometry of the human placenta. *Placenta*. 1984 Jan-Feb;5(1):83-92. doi: 10.1016/s0143-4004(84)80051-x. PMID: 6728834.
9. Xu W. [Histomorphometric study of the placenta in intrauterine growth retardation]. *Zhonghua Fu Chan Ke Za Zhi*. 1989 Nov;24(6):338-40, 381. Chinese. PMID: 2632164.
10. Biswas S, Ghosh SK, Chhabra S. Surface area of chorionic villi of placentas: an index of intrauterine growth restriction of fetuses. *Journal of Obstetrics and Gynaecology Research*. 2008 Aug;34(4):487-93.
11. Güven, D., Altunkaynak, B.Z., Altun, G., Alkan, I., & Koçak, İ. Histomorphometric changes in the placenta and umbilical cord during complications of pregnancy. *Biotechnic & Histochemistry*, 2018 (93), 198 - 210.
12. Khajuria, Ruchi, and Megha Sharma. "Histopathology of placenta in intrauterine growth restriction (IUGR)." (2019).
13. Mardi K, Negi L. Histopathological study of placentae in intrauterine growth retardation pregnancies in a tertiary care hospital and correlation with fetal birth weight. *J Pathol Nep* 2017;7: 1176-9. doi: 10.3126/jpn.v7i2.18003
14. T.M Mayhew, C Ohadike, P.N Baker, I.P Crocker, C Mitchell, S.S Ong, Stereological Investigation of Placental Morphology in Pregnancies Complicated by Pre-eclampsia with and without Intrauterine Growth Restriction, *Placenta*, Volume 24, Issues 2–3, 2003, Pages 219-226.
15. Maly A, Goshen G, Sela J, Pinelis A, Stark M, Maly B. Histomorphometric study of placental villi vascular volume in toxemia and diabetes. *Human pathology*. 2005 Oct 1;36(10):1074-9.
16. Egbor M, Ansari T, Morris N, Green CJ, Sibbons PD. Pre-eclampsia and fetal growth restriction: how morphometrically different is the placenta? *Placenta*. 2006 Jun 1;27(6-7):727-34.
17. Rinartha, K., & Suryasa, W. (2017). Comparative study for Gede Budasi, I. & Wayan Suryasa, I. (2021). The cultural view of North Bali community towards Ngidih marriage reflected from its lexicons. *Journal of Language and Linguistic Studies*, 17(3), 1484–1497
18. Kustina, K.T., Dewi, G.A.A.O., Prena, G.D., Suryasa, W. (2019). Branchless banking, third-party funds, and profitability evidence reference to banking sector in indonesia. *Journal of Advanced Research in Dynamical and Control Systems*, 11(2), 290-299.