

How to Cite:

Parate, A. S., Sheth, M., Wahab, A., Gangadharappa, P., Bumb, P. P., & Ganti, S. (2022). Assessment of commercially available bone graft material in the implant placed socket to enhance the osteointegration. *International Journal of Health Sciences*, 6(S2), 15183–15188. <https://doi.org/10.53730/ijhs.v6nS2.9011>

Assessment of commercially available bone graft material in the implant placed socket to enhance the osteointegration

Dr. Akhilesh Singh Parate

Senior resident, Department of Dentistry, Government medical College, Shahdol (MP)

Corresponding author email: drakhileshortho@gmail.com

Dr. Malav Sheth

(MDS) Senior Lecturer/Tutor, Department of Periodontics, Government dental college & hospital, Jamnagar

Email: drmalavsheth@gmail.com

Dr. Afreen Wahab

Post graduate student, Dept. Of Orthodontics and dentofacial orthopaedics, School of dental sciences, Karad, Maharashtra

Email: afugujarat@gmail.com

Dr. Praveen Gangadharappa

M.D.S., Asst Professor, Department of Prosthodontics, Jazan University-College of Dentistry, Jazan, Saudi Arabia

Email: praveengmds@gmail.com

Dr Pratik Prakash Bumb

Postgraduate, Dept. of Prosthodontics and Crown and Bridge, Teerthanker Mahaveer Dental College and Research Centre, Moradabad. (U.P)

Email: pratikbumb1996@gmail.com

Dr. Srinivas Ganti

Professor & Head, Department of oral and Maxillofacial surgery, KIMS Dental college & Hospital, Amalapuram. (A.P)

Email: ganti27drs@gmail.com

Abstract---Background: Alveolar bone resorption occurs in the majority of patients following teeth extraction. The present study was conducted to assess commercially available bone graft material in the implant placed socket to enhance the osteointegration. Materials & Methods: The present study comprised of 64 patients of both genders. Concentrated growth factor (CGF) was prepared according to Sacco's

protocol, using the patients' own venous blood. Extraction of mandibular first molars was carried out and implants were immediately placed with CGF grafting. A Cone Beam Computed Tomography (CBCT) was taken immediately after implant placement and after six months of undisturbed healing to assess the quantity and quality of new bone formed around implants. Results: Out of 64 patients, males were 40 and females were 24. The mean bone height was on buccal side immediately was 9.04 and after 6 months was 11.3, on lingual side immediately was 10.6 and after 6 months was 11.8, on distal side immediately was 8.3 and after 6 months was 11.0, on mesial side immediately was 7.5 and after 6 months was 11.2. The difference was significant ($P < 0.05$). Conclusion: A significant increase in bone volume was evident at 6 months follow-up after implant placement using concentrated growth factor bone graft.

Keywords---concentrated growth factor, bone graft, implant.

Introduction

Alveolar bone resorption occurs in the majority of patients following teeth extraction. In many cases the alveolar bone continues to resorb and creates atrophied edentulous areas that are problematic to restore without extensive bone grafting.¹ Immediate single-tooth implant placements with transgingival healing should solve the problem of post-extraction extensive alveolar bone resorption and the loss of gingival papillae.² The latter is a common cause of esthetic problems in delayed implant placement. Albrektsson et al³ reported that primary implant stability and lack of micromovement are two of the main factors considered necessary for the achievement of predictably high success rates for osseointegrated oral implants. Primary stability of implants placed immediately after extraction strongly influences the long-term success of dental implants.⁴ Following tooth extraction, the alveolar bone supporting tooth undergoes constant atrophy⁵. It is shown that a marked reduction of the height of the alveolar ridge consistently occurred following tooth extraction and that implant installation in the fresh extraction socket did not interfere with the process of bone modelling.⁶ The present study was conducted to assess commercially available bone graft material in the implant placed socket to enhance the osteointegration.

Materials & Methods

The present study comprised of 64 patients of both genders. The consent was obtained from all enrolled patients. Data such as name, age, gender etc. was recorded. Concentrated growth factor (CGF) was prepared according to Sacco's protocol, using the patients' own venous blood. Induction of local anaesthesia was carried out using 2% lidocaine with 1:80,000 adrenaline. The tooth was extracted with the preservation of the buccal bone, with subsequent curettage and antibacterial irrigation (0.12% chlorhexidine gluconate) of the socket. Extraction of mandibular first molars was carried out and implants were immediately placed with CGF grafting. A Cone Beam Computed Tomography (CBCT) was taken immediately after implant placement and after six months of undisturbed healing,

radiographic evaluation was carried out using CBCT to assess the quantity and quality of new bone formed around implants. Data thus obtained were subjected to statistical analysis. P value < 0.05 was considered significant.

Results

Table I Distribution of patients

Total- 64		
Gender	Males	Females
Number	40	24

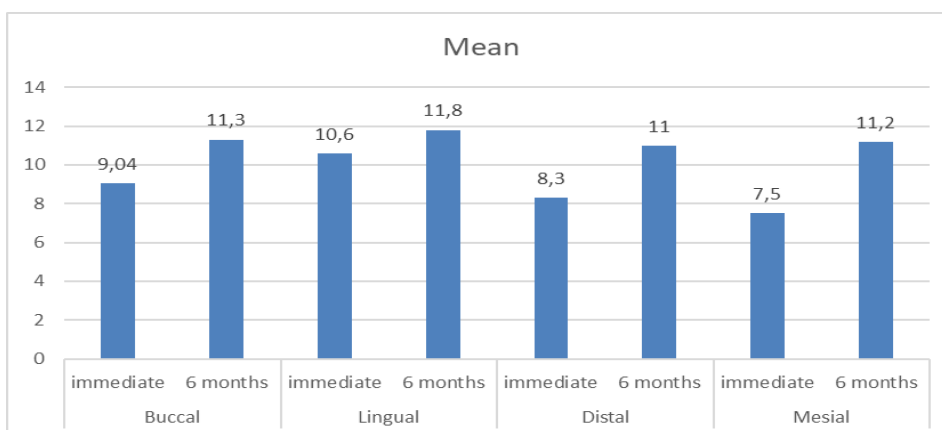
Table I shows that out of 64 patients, males were 40 and females were 24.

Table II Radiographic evaluation of quantity of bone formation following immediate extraction and implant placement

Tooth surface	Duration	Mean	P value
Buccal	immediate	9.04	0.04
	6 months	11.3	
Lingual	immediate	10.6	0.05
	6 months	11.8	
Distal	immediate	8.3	0.02
	6 months	11.0	
Mesial	immediate	7.5	0.01
	6 months	11.2	

Table II, graph I shows that mean bone height was on buccal side immediately was 9.04 and after 6 months was 11.3, on lingual side immediately was 10.6 and after 6 months was 11.8, on distal side immediately was 8.3 and after 6 months was 11.0, on mesial side immediately was 7.5 and after 6 months was 11.2. The difference was significant ($P < 0.05$).

Graph I Radiographic evaluation of quantity of bone formation following immediate extraction and implant placement



Discussion

Numerous studies have confirmed the predictability and success of implant placement at the time of extraction, with a number of prospective and retrospective studies confirming high survival rates for more than 95% of immediate post-extraction implants and with observation periods ranging from 1 to 5 years.⁷ Immediate installation of implants in fresh sockets is a challenging and sensitive technique and requires careful case selection.⁸ It has been postulated that when the size of horizontal gap surrounding immediately placed implants exceeds the threshold of 1 to 2 mm, bone graft procedures might be recommended to reduce peri-implant bone resorption and improve the esthetic outcome of the soft tissue.⁹ The influence of grafting procedure on primary stability of immediately placed implants, nevertheless, has not been given enough attention.¹⁰ The present study was conducted to assess commercially available bone graft material in the implant placed socket to enhance the osteointegration. We found that out of 64 patients, males were 40 and females were 24. Manoj et al¹¹ assessed radiographically the quantity and quality of bone formed in the region of mandibular first molar after extraction of the tooth and immediate implant placement with concentrated growth factor (CGF) grafting. A total of 10 subjects were selected for this prospective study. Extraction of mandibular first molars was carried out and implants were immediately placed with CGF grafting. A Cone Beam Computed Tomography (CBCT) was taken immediately after implant placement and after six months of undisturbed healing, radiographic evaluation was carried out using CBCT to assess the quantity and quality of new bone formed around implants. The collected data were statistically analyzed. CBCT results showed a mean bone gain of 2.3 mm in buccal, 1.52 mm in lingual, 2.97 mm in mesial and 4.26 mm in distal aspect respectively. No statistically significant change was noticed in bone density comparing the first two and last two threads of implants inserted with concomitant placement of CGF into the extraction socket.

We observed that mean bone height was on buccal side immediately was 9.04 and after 6 months was 11.3, on lingual side immediately was 10.6 and after 6 months was 11.8, on distal side immediately was 8.3 and after 6 months was 11.0, on mesial side immediately was 7.5 and after 6 months was 11.2. Jun et al¹² evaluated the effect of bone graft procedure on the primary stability of implants installed in fresh sockets and assess the vertical alteration of peri-implant bone radiographically. 23 implants were inserted in 18 patients immediately after tooth extraction. The horizontal gap between the implant and bony walls of the extraction socket was grafted with xenografts. The implant stability before and after graft procedure was measured by Osstell Mentor as implant stability quotient before bone graft (ISQ bbg) and implant stability quotient after bone graft (ISQ abg). Peri-apical radiographs were taken to measure peri-implant bone change immediately after implant surgery and 12 months after implant placement. The increase of ISQ in low primary stability group (LPSG) was 6.87 ± 3.62 , which was significantly higher than the increase in high primary stability group (HPSG). A significant correlation between ITV and ISQ bbg was found; however, age and peri-implant bone change were not found significantly related to implant stability parameters. It was presented that there were no significant peri-implant bone changes at 1 year after bone graft surgery.

Tehemar et al¹³ determined whether the addition of a bone substitute graft material and/or a guided bone regeneration membrane added to the site of an immediately placed implant would increase the development of lamellated bone, particularly in the presence of bone defects. Four treatment modalities associated with the immediate placement of hydroxyapatite-coated endosteal screw implants into extraction sockets of healthy (CiH) and periodontally diseased teeth (TIPD) were tested. Five dogs with healthy teeth and five dogs with naturally occurring periodontitis were chosen for the study. Each dog received eight implants after extraction of four mandibular and four maxillary premolars. Four implants were submerged for 3 months and four for 6 months. The implants were either inserted alone (subgroup A); surrounded by a GORETEX® membrane (subgroup B; W.L. Gore & Associates Inc., Flagstaff, AZ, USA); surrounded by PepGen P-15" (Dentsply Friadent CeraMed Dental Co. Denver, CO, USA) at coronal area (subgroup C); or surrounded by a combination of graft material and the ePTFE membrane (subgroup D). Implants in group A were osseointegrated in both C/H and T/PD groups with similar bone-implant contact ratios (BICRs). ePTFE membrane significantly improved the BICR of the 6-months implants, whereas graft material significantly increased the BICR at 3 months and maintained the gain thereafter. The graft material and membrane combination further improved the BICR and significantly increased lamellated bone in crestal bone of all implants.

Conclusion

Authors found that a significant increase in bone volume was evident at 6 months follow-up after implant placement using concentrated growth factor bone graft.

References

1. Krebs M, Schmenger K, Neumann K, Weigl P, Moser W, Nentwig GH. Longterm evaluation of ANKYLOS® dental implants. Part 1: 20-year life table analysis of a longitudinal study of more than 12,500 implants. *Clin Implant Dent Relat Res* 2015 Jan; 17(1): 275-86.
2. Lazzara RJ. Immediate implant placement into extraction sites: Surgical and restorative advantages. *Int J Periodontics Restorative Dent* 1989; 9: 332-343.
3. Albrektsson T, Lekholm U. Osseointegration: Current state of art. *Dent Clin North Am* 1989;33(4):537-54.
4. Schwartz-Arad D, Chaushu G. The ways and wherefores of immediate placement implants into fresh extraction sites: a literature review. *J Periodontol* 1997 Oct;68(10):915-23.
5. Grunder U, Polizzi G, Geone R, et al. A 3-year prospective multicentre followup report on immediate and delayed immediate placement of implant. *Int J Oral Maxillofac Implants* 1999; 14:210-16.
6. Lanza A, Scognamiglio F, De Marco G, Di Francesco F, Femiano F, Lanza M, Itró A. Early implant placement: 3D radiographic study on the fate of buccal wall. *J Osseointegr* 2017;9(3):276-281.
7. Ericsson I, Nilson H, Lindh T, Nilner K, Randow K. Immediate functional loading of Brånemark single tooth implants. An 18-month clinical pilot follow-up study. *Clin Oral Implants Res* 2000; 11: 26-33.

8. Becker BE, Becker W, Ricci A, Geurs N. A prospective clinical trial of endosseous screw shaped implant placed at the time of tooth extraction without augmentation. *J Periodontol* 1998; 69:920-26.
9. Wilson TG, Schenk R, Cochran D. Implants placed in fresh extraction site: A report of histological and histometric analysis of human biopsies. *Int J Oral Maxillofac Implants* 1998; E3: 333-41.
10. Gelb DA. Immediate implant surgery: Three-year retro-spective evaluation of 50 consecutive case. *Int J Oral Maxillofac Implants* 1993; 8:388-99.
11. Manoj S, Punit J, Chethan H, Nivya J. A study to assess the bone formed around immediate postextraction implants grafted with Concentrated Growth Factor in the mandibular posterior region. *Journal of Osseointegration*. 2018 Nov 14;10(4):121-9.
12. Jun SH, Park CJ, Hwang SH, Lee YK, Zhou C, Jang HS, Ryu JJ. The influence of bone graft procedures on primary stability and bone change of implants placed in fresh extraction sockets. *Maxillofacial plastic and reconstructive surgery*. 2018 Dec;40(1):1-6.
13. Tehemar S, Hanes P, Sharawy M. Enhancement of osseointegration of implants placed into extraction sockets of healthy and periodontally diseased teeth by using graft material, an ePTFE membrane, or a combination. *Clinical Implant Dentistry and Related Research*. 2003 Oct;5(3):193-211.
14. Widana, I.K., Sumetri, N.W., Sutapa, I.K., Suryasa, W. (2021). Anthropometric measures for better cardiovascular and musculoskeletal health. *Computer Applications in Engineering Education*, 29(3), 550–561. <https://doi.org/10.1002/cae.22202>
15. Rinatha, K., Suryasa, W., & Kartika, L. G. S. (2018). Comparative Analysis of String Similarity on Dynamic Query Suggestions. In *2018 Electrical Power, Electronics, Communications, Controls and Informatics Seminar (EECCIS)* (pp. 399-404). IEEE.