

How to Cite:

Sivanandan, M. H., Nanthivarman, N., Jose, L., & Manoharan, A. E. (2022). Functional outcomes of distal tibia fractures treated using the minimally invasive percutaneous plate osteosynthesis technique with a locking compression plate. *International Journal of Health Sciences*, 6(S4), 4748–4756. <https://doi.org/10.53730/ijhs.v6nS4.9088>

Functional outcomes of distal tibia fractures treated using the minimally invasive percutaneous plate osteosynthesis technique with a locking compression plate

Dr. M. Hari Sivanandan

Associate Professor, Department of Orthopaedics, VMKV Medical college, salem
Corresponding author email: sivadr1983@gmail.com

Dr. Nanthivarman

Junior resident, Department of Orthopaedics, Medical college, salem
Email: nanthivarman.ksp@gmail.com

Dr. Leo Jose

Assistant professor, Department of Orthopaedics, VMKV Medical college Medical college. Salem
Email: drleo1234@gmail.com

Dr. A. E. Manoharan

Head Of Department & Professor, Department of Orthopaedics, VMKV Medical college, salem
Email: drmanobaby@gmail.com

Abstract---Background: Distal metaphysealtibia fractures are difficult to treat owing to their limited blood supply, subcutaneous location, and inadequate soft tissue blanket. Minimallyinvasive percutaneous plate Osteosynthesis (MIPPO) using alocking compression plate (LCP) is a widely used surgical treatment. It is beneficial for the management of distal tibia fractures. This study aimed to assess thefunctionaloutcomesofdistaltibiafracturestreatedwiththe MIPPO technique with an LCP. Methods: The investigators have conducted this prospective study with thirty patients who presented with distal tibia fractures over 8 months. All patients fulfilling the inclusion criteria and exclusion criteria took part in the study.All the patients were surgically managed by the MIPPO technique with LCP under spinal or general anesthesia.The functional and radiological outcomes were evaluated with the American Orthopedic Foot & Ankle Society (AOFAS) scale. Results: A sizable number of the patients were aged 40–60 years, with a mean age of 49.8 years. Most participants were

male (66.67%). The mean duration of surgery was 72.60 ± 5.35 minutes. The mean length of hospital stay was 7.22 ± 1.45 days. The mean healing time was 17.76 ± 3.88 weeks. According to the AOFAS scale, 4/30 (13.33%) patients had excellent outcomes, 20/30 (66.67%) had good outcomes, and 6/30 (20%) had acceptable outcomes. No patient had a bad outcome. The type A fractures more often had excellent and good functional outcomes than the type B fractures (P value = 0.0007). Conclusion: Distal tibia fractures can be managed by the MIPPO technique because it results in early recovery with reduced chances of malunion and deformities.

Keywords---distal tibia fracture, osteosynthesis, locking compression plate, American orthopedic foot, ankle society scale.

Introduction

The management of distal metaphyseal fractures of the tibia is arduous because of their limited blood supply, subcutaneous location, and inadequate soft tissue cover [1,2]. The incidence of distal tibia fracture, which corresponds to 1% of all lower limb fractures and 10% of all tibia fractures, is increasing both among elderly people and because of road traffic accidents [3]. Most tibia fractures are managed surgically using open reduction and internal fixation with plating or closed reduction, and percutaneous plating or external fixation. Conservative management can be applied to stable, undisplaced closed fractures. Complications reported following treatment of distal tibia fractures are malunion, shortening of the affected leg, early osteoarthritis of the ankle, and limited range of movement [4–6].

Minimally invasive percutaneous plate osteosynthesis (MIPPO) with locking compression plate (LCP) has emerged as a popular treatment option for distal tibia fractures. The widely accepted classification for distal tibia fractures is the Orthopedic Trauma Association (OTA)/Arbeitsgemeinschaft für Osteosynthesefragen (AO) combined classification, derived from the Müller AO long-bone fractures classification [7]. MIPPO is beneficial for the management of distal tibia AO/OTA type A and B fractures because the length of hospital stay is reduced, the technique is cost-effective, and the infection rate is lower [8]. The MIPPO with LCP system works as a flexible elastic fixation that promotes the formation of the callus. The fracture's primary displacement is prevented by its anatomical shape, allowing improved dispersal of axial and angular loading around the plate [9]. The periosteal blood delivery of the fracture hematoma and bone is not disturbed because it is minimally invasive. Many studies globally have investigated the management of distal tibial fractures by the MIPPO technique with an LCP, but studies in the Indian setting are lacking. This study therefore aimed to investigate the functional after-effects of distal tibia fractures treated with the MIPPO technique with an LCP in an Indian setting.

Materials and Methods

This prospective observational study included thirty patients treated between September 2021 and April 2022 at the Department of Orthopedics, Vinayaka Mission Kirupananda Variyar Medical College and Hospital and it is in Salem, Tamilnadu. Approval for the study was got from the Institutional Ethical Committee of Vinayaka Mission Kirupananda Variyar Medical College and Hospital (VMKVMC&H/IEC/21/22). All patients with distal tibial fractures who presented to the emergency department were received and recruited for the study by the universal sampling method. Patients aged > 18 years with intra- and extra-articular closed distal third tibia fractures were included in the study. Patients with poly-trauma, open fractures, and who were medically unfit for surgery were omitted from the study. Written informed consent was got from all the study participants.

The investigators evaluated the patients presented by fresh fractures with a pre-validated, pretested, semi-structured questionnaire. A detailed preoperative workup was done by the investigators. All the cases were taken for surgery as early as possible. All the patients were surgically managed by the MIPPO technique with LCP under spinal or general anesthesia. A tourniquet was used, and we made an incision at the level of the medial malleolus. A subcutaneous plane was created without disturbing the fracture hematoma. Indirect reduction of fracture was completed under C-arm guidance and then fixed with both an LCP plate and screws. Relative stability was achieved as it was an indirect reduction. After the patients' general condition improved, AP and lateral view X-rays were taken, and the fracture patterns were classified based on the AO/OTA classification of fractures in the distal tibia.

The postoperative protocol comprised limb elevation for the first 2–5 days, immediate physiotherapy with active-assisted exercise, and radiological and clinical follow-up after 1, 3, and 6 months. Based on consolidation of the fracture, partial weight-bearing was started at half a month, and full weight-bearing was usually allowed after three months. All the patients were followed up carefully for complications until the fracture healed and thereafter every month for up to six months. Assessment of functional and radiological outcomes was performed under the American Orthopedic Foot & Ankle Society (AOFAS) scale [10]. This scale comprises subjective and objective variables, i.e., pain (40 points), function alone (50 points), and alignment (10 points). The outcome scores were graded: >89 excellent; 80–89 good; 70–79 acceptable; and <79 bad.

Results

In the present prospective study, there was no loss to follow-up and assessed 30 patients at the end, so the response rate was 100%. More than three fourth of the patients (83.33%) were in the middle age group of 40-60 years followed by 03 (10%) from the age group of >60 years. The mean age the participants was 53.65 ± 13.95. More than half of the patients (66.67%) were male. Only 10 participants (33.33%) had a history of addiction. Out of 30 patients, nearly 09 (30%) had history of hypertension, 04 (13.33%) diagnosed with Diabetes mellitus (DM), 2 (6.67%) coronary heart disease (CHD) & Diabetes and Hypertension each as

comorbidity. As per AO classification, a sizable number of patients (70%) were presented with type A tibial fracture while 09 (30%) had type B fracture. (Table 1) On studying surgical details of the MIPPO technique, we have found that the median time interval between injuries to surgery was 5 days. The mean duration of surgery was 72.60 ± 5.35 minutes. After the surgical procedure, the hospital stay was 7.22 days. The mean healing time was 17.76 ± 3.88 weeks. (Table 2)

In this study, the most common complication of the MIPPO technique for the distal tibia fractures was delayed union in 04 (13.33%) patients followed by malunion in 02 (6.67%), infection & implant failure in 01 (3.33%) patients each. (Figure 1) According to the AOFAS scale, out of 30 patients, 4 (13.33%) patients had excellent outcomes, 20 (66.67%) had good & 6 (20%) had acceptable outcomes, but none had bad outcomes. (Figure 2) Among the study participants, who were aged over 60 years, about 66.7 percent have an acceptable AOFAS score when compared to other age groups which have good and excellent AOFAS score after intervention. This difference in proportion is statistically significant ($P < 0.05$) according to the Chi-square test. Similarly, among individuals diagnosed with Type A according to OTA/ AO classification, about 95 percent of them had good and excellent AOFAS score when compared to individuals diagnosed with Type B with statistical significance according to Chi-square test. These associations were shown in table 3. When respect to complications, the risk factors like gender, age group, and type of fractures had no association with complication of the intervention according to the chi-square test. These associations were shown in table 4.

Discussion

The MIPPO technique is based on the principle of biological osteosynthesis with the use of fracture hematoma and minimal destruction of soft tissue at the fracture site. In our study, the mean age of patients was 53.65 ± 13.95 years, with most of them (66.67%) being males. Nearly 70% of the patients presented with type A tibia fractures according to OTA/ AO classification. The median time interval between injuries to surgery was 5 days. These findings are consistent with Gülabi et al.[8] Khader et al.[11] and Pierre Joveniaux et al. [12].

The mean duration of surgery with the MIPPO technique was 65.60 ± 5.35 minutes. The mean length of hospital stay was 7.22 ± 1.45 days. Similarly, Gülabi et al. also noted that the mean duration (61.14 ± 5.61 min.) & mean length of hospital stay (7.64 ± 4.71 days) of MIPPO surgery was less than ORIF and concluded that the MIPPO technique is useful for the management of distal tibia AO/OTA A and B type fractures with a reduced hospital stay, cost-effectiveness, and infection rate[8]. The mean healing time was 17.76 ± 3.88 weeks. The median time interval between injuries to surgery was 5 days. The mean healing time in our study was 17.76 ± 3.88 weeks. Siddhartha Venkata Paluvadi et al.[13] in their study reported that the mean fracture healing time with the MIPPO technique was 21.4 weeks (16-32 weeks) & in the study by Khader et al.[11] it was 22 weeks.

In the present study, the most common complication of the MIPPO technique for the distal tibia fractures was delayed union in 04 (13.33%) patients followed by malunion in 2 (6.67%), infection & implant failure in 1 (3.33%) patient each. These

findings are consistent with Siddhartha Venkata Paluvadi et al.[13], who found that superficial infection befallen in 5 patients (10%); deep infection, implant failure, and malunion in 1- one patient each (2%). Xiao-kai Liu et al. noted that the MIPPO technique has lower incidences of malunion while intramedullary nailing has lower wound complications as compared to MIPPO technique[14]. In contrast to our findings, Kawalkar Abhijit Chandrakant et al., when comparing two minimally invasive techniques i.e. MIPPO & intramedullary nailing found that there was no difference in terms of time for fracture union, malunion, non-union, duration of surgery, and amount of blood loss. But there was a significant difference in terms of infection and duration of hospital stay, which was observed higher with MIPPO technique[15].

According to the AOFAS scale, out of 30 patients, 4 (13.33%) patients had excellent outcomes, 20 (66.67%) had good & 6 (20%) had acceptable outcomes, but none had a bad outcome. This finding is in line with Khader et al.[11] J.-W. Zhang et al. found excellent results for all patients[16]. The current study found that the study participants who were aged over 60 years, most of the patients have acceptable AOFAS scores when compared to other age groups which have good and excellent AOFAS scores after intervention with statistical significance. Similarly, a study done in Vietnam, in 2021, by Van Nguyen et al., observed that out of 70 patients with distal tibia fracture who underwent the MIPPO technique of intervention states that complications like wound infection, implement impingement, and screw breakage are more common in older people of age over 65 years. The same study also states that though there is a complication in the old age people, but it did not affect the rehabilitation and function of the patients[17]. Though there is statistical significance in the AOFAS score in the current study, but regarding complications, the risk factors like gender, age group, and AO classification had no association with the complication of the intervention according to the chi-square test. This discussion needs further evaluation with a large sample size.

Among the study participants who were diagnosed with Type A according to AO classification, about 95 percent of them had good and excellent AOFAS scores when compared to individuals diagnosed with Type B with statistical significance according to the Chi-square test. Similarly, a study done in Turkey, in 2020, by Baris et al., observed that out of 60 patients with distal tibia fracture who underwent the MIPPO technique of intervention found that there is a statistically significant difference in the AOFAS score after intervention between types of fracture. The type A fracture has good results than type B and Type C fractures [18]. This study also concludes that MIPPO is the most reliable technique for the management of distal tibia fractures.

Limitation and strength of the study

The current study has been conducted with a fair sample size. A multicentric study with a larger sample could yield better results. Our study has been conducted in a hospital setting which may reflect Berksonian bias, so different settings may yield different results. The current study has no attrition bias, which increases the internal validity. Among 30 study subjects, no one scores bad category according to AOFAS score and nearly six of them had developed

complication with MIPPO technique. The high success rate and the high prevalence of complication may be because of the influence of low sample size, which needs further evaluation.

Conclusion

MIPPO with the help of C arm guidance can be a helpful technique for the management of distal tibial fractures because it tends to speed recovery with reduced possibilities of malunion and deformities. Meanwhile, it offers the very smallest incision & decreases the upcoming complications as it aids in timely mobilization of ankle movement and decreases the odds of infection improving the clinical and functional outcome.

References

1. Shon O, Park C: Minimally invasive plate osteosynthesis of distal tibial fractures: a comparison of medial and lateral plating. *J Orthop Sci.* 2012, 17:562–6. 10.1007/s00776-012-0241-9
2. Tulner SAF, Strackee SD, Kloen P: Metaphyseal locking compression plate as an external fixator for the distal tibia. *Int Orthop.* 2012, 36:1923–7. 10.1007/s00264-012-1585-7
3. Li Y, Liu L, Tang X, et al.: Comparison of low, multidirectional locked nailing and plating in the treatment of distal tibial metadiaphyseal fractures. *Int Orthop.* 2012, 36:1457–62. 10.1007/s00264-012-1494-9
4. Shanmugam C, Rahmatalla A, Maffulli N: Percutaneous Fixation of Distal Tibial Fractures Using Locking Plates. *Techniques in Orthopaedics.* 2007, 22:162–6. 10.1097/BTO.0b013e318149fc3e
5. Cheng W, Li Y, Manyi W: Comparison study of two surgical options for distal tibia fracture-minimally invasive plate osteosynthesis vs. open reduction and internal fixation. *Int Orthop.* 2011, 35:737–42. 10.1007/s00264-010-1052-2
6. Kao FC, Tu YK, Hsu KY, Wu CH, Yen C-Y, Chou MC: Treatment of distal tibial fractures by minimally invasive percutaneous plate osteosynthesis of three different plates: Results and cost-effectiveness analysis. *Formosan Journal of Musculoskeletal Disorders.* 2010, 1:35–40. 10.1016/j.fjmd.2010.10.007
7. Meinberg E, Agel J, Roberts C, Karam M, Kellam J: Fracture and Dislocation Classification Compendium—2018. *Journal of Orthopaedic Trauma.* 2018, 32:S1–10. 10.1097/BOT.0000000000001063
8. Gulabi D: Surgical treatment of distal tibia fractures: Open versus MIPO? *Ulus Travma Acil Cerrahi Derg.* Published Online First: 2015. 10.5505/tjtes.2015.82026
9. Ronga M, Longo UG, Maffulli N: Minimally Invasive Locked Plating of Distal Tibia Fractures is Safe and Effective. *Clin Orthop Relat Res.* 2010, 468:975–82. 10.1007/s11999-009-0991-7
10. Cook JJ, Cook EA, Rosenblum BI, Landsman AS, Roukis TS: Validation of the American College of Foot and Ankle Surgeons Scoring Scales. *J Foot Ankle Surg.* 2011, 50:420–9. 10.1053/j.jfas.2011.03.005
11. Khader DrFA, Mohanraj DrP, B DrS: A prospective study on functional outcome of distal tibia fracture treated with minimally invasive technique

- using locking compression plate. *Int J Orthop Sci.* 2021, 7:663–6. 10.22271/ortho.2021.v7.i1k.2554
12. Joveniaux P, Ohl X, Harisboure A, et al.: Distal tibia fractures: management and complications of 101 cases. *Int Orthop.* 2010, 34:583–8. 10.1007/s00264-009-0832-z
 13. Paluvadi SV, Lal H, Mittal D, Vidyarthi K: Management of fractures of the distal third tibia by minimally invasive plate osteosynthesis - A prospective series of 50 patients. *J Clin Orthop Trauma.* 2014, 5:129–36. 10.1016/j.jcot.2014.07.010
 14. Liu X-K, Xu W-N, Xue Q-Y, Liang Q-W: Intramedullary Nailing Versus Minimally Invasive Plate Osteosynthesis for Distal Tibial Fractures: A Systematic Review and Meta-Analysis. *Orthop Surg.* 2019, 11:954–65. 10.1111/os.12575
 15. Chandrakant KA, Martand BC: Distal Tibia Metaphyseal Fractures: Which is Better, Intra-medullary Nailing or Minimally Invasive Plate Osteosynthesis? *Journal of Orthopaedics, Trauma and Rehabilitation.* 2018, 24:66–71. 10.1016/j.jotr.2017.09.004
 16. Zhang J-W, Ebraheim NA, Li M, He X-F, Schwind J, Zhu L-M, Yu Y-H: Distal tibial fracture: An ideal indication for external fixation using locking plate. *Chinese Journal of Traumatology.* 2016, 19:104–8. 10.1016/j.cjte.2015.05.006
 17. Van Nguyen L, Nguyen GN, Nguyen BL, Bui HM: Results and complications of minimally invasive medial plate osteosynthesis for distal metaphyseal tibial fractures: A prospective case series from Vietnam. *Ann Med Surg (Lond).* 2021, 70:102886. 10.1016/j.amsu.2021.102886
 18. Barış A, Çirci E, Demirci Z, Öztürkmen Y: Minimally invasive medial plate osteosynthesis in tibial pilon fractures: Longterm functional and radiological outcomes. *Acta Orthop Traumatol Turc.* 2020, 54:20–6. 10.5152/j.aott.2020.01.489
 19. Widana, I.K., Dewi, G.A.O.C., Suryasa, W. (2020). Ergonomics approach to improve student concentration on learning process of professional ethics. *Journal of Advanced Research in Dynamical and Control Systems*, 12(7), 429-445.
 20. Widana, I.K., Sumetri, N.W., Sutapa, I.K., Suryasa, W. (2021). Anthropometric measures for better cardiovascular and musculoskeletal health. *Computer Applications in Engineering Education*, 29(3), 550–561. <https://doi.org/10.1002/cae.22202>
 21. Akbarov, A. N., & Xabilov, D. N. U. (2021). The condition of the oral cavity in patients who have had a viral infection COVID-19. *International Journal of Health & Medical Sciences*, 4(4), 381-383. <https://doi.org/10.21744/ijhms.v4n4.1796>

Table 1. Distribution of patients according to baseline characteristics.

Baseline characteristic	Frequency	Percentage (%)	
Age groups (years)	<40	02	6.67
	40-60	25	83.33
	>60	03	10
Age (years)	53.65 ± 13.95 (Mean± SD)		

Gender	Male	20	66.67
	Female	10	33.33
AO classification	Type A	21	70
	Type B	09	30

Table 2. Surgical details of the MIPPO technique for the patients

Surgical detail	Score (Mean ± SD)
Time interval from injury to surgery (median)	5
Duration of surgery (min)	72.60 ± 5.35
Length of hospital stay (days)	7.22 ± 1.45
Healing time (weeks)	17.76 ± 3.88

Figure 1. Complications of the MIPPO technique for the distal tibia fractures.

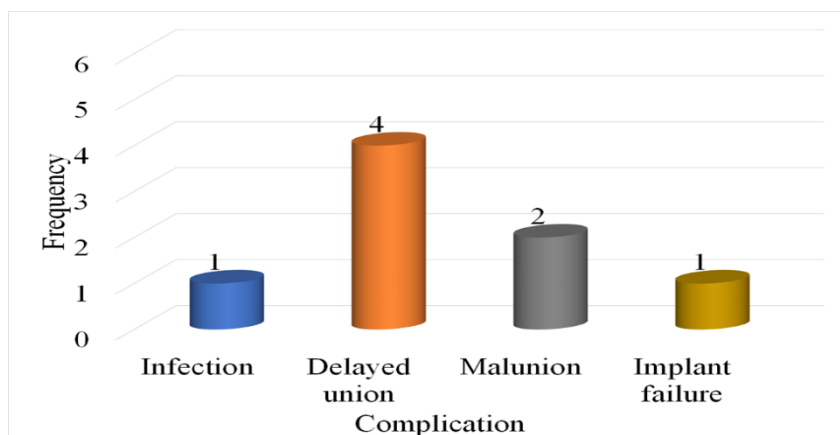


Figure 2. Outcomes as per AOFAS score associated with the MIPPO technique for the distal tibia fractures

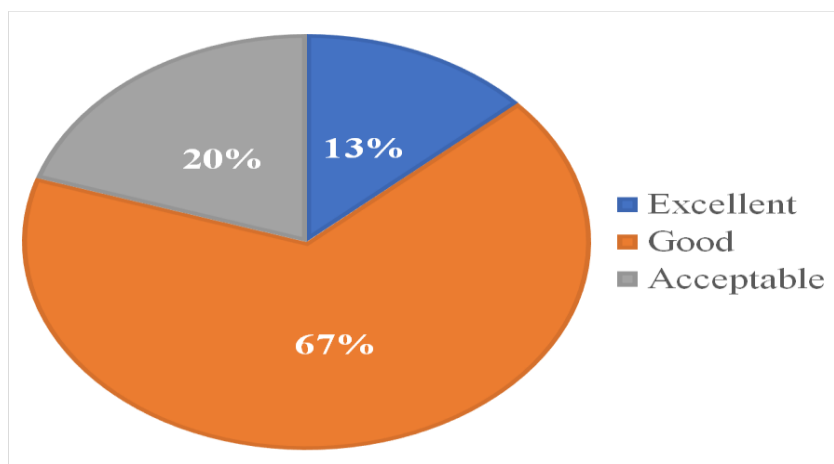


Table 3. Association between outcomes as per AOFAS score and the general characteristics of the study participants (n = 30).

S. No	Variables		AOFAS score		Total	Chi-square value	P-Value
			Good and Excellent, N (%)	Acceptable, N (%)			
1	Age	Less than 40 years	1(50)	1(50)	2	6.2083	0.034
		40 to 60 years	22(88)	3(12)	25		
		More than 60 years	1(33.3)	2(66.7)	3		
2	Gender	Male	18(90)	2(10)	20	2.109*	0.146
		Female	6(60)	4(40)	10		
3	AO	Type A	20(95)	1(5)	21	17.33*	0.007
		Type B	4(44)	5(56)	9		
		Total	24	6	30		

*Fischer exact test value

Table 4: Association between risk factors and complication of the intervention among the study participants (n = 30)

S. No	Variables		Complications		Chi-square value	P - Value
			Yes, N (%)	No, N (%)		
1	Gender	Female	2(20)	8(80)	0.093	0.760
		Male	5(25)	15(75)		
2	Age group	<40	1(50)	1(50)	4.696	0.095
		40-60	4(16)	21(84)		
		>60	2(67)	1(33)		
3	OTA/ AO classification	Type A	4(24)	17(76)	0.718	0.396
		Type B	3(33)	6(67)		