

How to Cite:

Shalini, M., Bhatnagar, A., Yadav, A., & Surendran, A. (2022). Limberg flap reconstruction-a reliable and one time solution for chronic recurrent sacrococcygeal pilonidal sinus: A retrospective study. *International Journal of Health Sciences*, 6(S5), 2221–2230.
<https://doi.org/10.53730/ijhs.v6nS5.9129>

Limberg flap reconstruction-a reliable and one time solution for chronic recurrent sacrococcygeal pilonidal sinus: A retrospective study

Dr Megha Shalini

Post Graduate Resident of Department of Surgery, Gandhi Medical College and Associated Hamidia Hospital, Bhopal

Corresponding author email: meghashalini1416@gmail.com

Arun Bhatnagar

Professor and Head of the Department, Department of Plastic Surgery, Gandhi Medical College, Bhopal.

Amber Yadav

Mch resident, Department of Plastic Surgery, Gandhi Medical College, Bhopal

Anupam Surendran

Resident doctor, Department of Surgery, Gandhi Medical College, Bhopal

Abstract--Background: Sacrococcygeal pilonidal sinus is a acquired disease of the adult age especially male, with significant morbidity and high recurrence rate. The management of the pilonidal sinus varies from incision and drainage, excision and packing dressing, excision and primary closure, marsupialization, excision and flap cover. Limberg flap technique is single stage procedure and is superior to other technique in terms of less complication and low recurrence rates thus reducing hospital stay, cost and good patient compliance. Aims & Objective: The aim of this study is to discuss feasibility and outcomes of Limberg flap reconstruction in chronic recurrent pilonodal sinus. Methodology: This is a retrospective study involving 14 patient from June 2019 to June 2020; all were men of age group 25 to 40 years with recurrent pilonodal sinus. Result: A total of 14 patients underwent Limberg flap surgery after excision of pilonodal sinus, under spinal anaesthesia. Methylene blue dye was injected in the sinus. Sinus tract with adjacent tissues were excised and beyond the sinus limit to create a rhombic defect. Inferiorly based Limberg flap was planned at the site depending on the pliability of skin. Donor area was closed primarily. Patient was nursed prone. Check dressing was

done after 48 hours. The postoperative period was uneventful and patients were discharged within 6 to 8 days with advice not to put pressure on the flap for 3 weeks. They were followed up after 2 weeks, 3 months and 6 months. We found minimal postoperative pain and no recurrence so far. All of them resumed their work within 3 weeks postoperatively. Conclusion: Limberg flap reconstruction is one time solution for chronic recurrent pilonidal sinus which is easy to perform with minimal postoperative complications and recurrence rate, thus reducing morbidity significantly with high patient satisfaction.

Keywords---Limberg flap, chronic pilonidal sinus, reconstruction.

Introduction

Chronic pilonidal sinus is a relatively common and morbid disease. It is an acquired, benign disease of young adulthood that is encountered more commonly in males than in females, rare both before puberty and after the age of 40 years [1]. The name 'pilonidal' is taken from Latin which means "nest of hair". The estimated incidence is 26/1,00,000 population [2,3]. It is most frequently seen in the sacrococcygeal region. However it has also been described in axilla, suprapubic area, periumbilical region and in between the fingers of the hand in the barbers [4,5].

It usually presents as a cyst, an abscess or one or more sinus tracts with or without discharge in the upper part of the natal cleft. Hair tufts within the sinus seen in about 60% of the cases, and is now considered important secondary outcome in the evolution of sinus [6]. The aetiology of the pilonidal sinus is controversial and unclear. Initially congenital origin was suggested that it was secondary to the remnants of an epithelial lined tract from post-coccygeal epidermal cell rests or vestigial scent cells. Now the view widely shifted toward acquired theory [7]. And is based on observations that congenital tracts don't contain hair and are lined by cuboidal epithelium. KARYDAKIS proposed three main factors causing the disease namely large quantity of hair, extreme force and vulnerability to infection [8]. The most important predisposing factors for the development of pilonidal sinus are the existence of a deep natal cleft and large amount of hair within the cleft. A deep natal cleft is a favourable environment for sweating, maceration, bacterial contamination, and penetration of hairs [9]. Thus for the treatment and prevention, these causative factors must be eliminated. Male gender, obesity, smoking, family tendency, poor body hygiene, sinus size and the surgical procedures performed, have been discussed in number of studies as contributing risk factors for the postoperative complications and recurrences [6]. Diagnosis is usually clinical and patient may present with symptoms like chronic inflammation, a sinus with persistent discharge, an abscess or multiple subcutaneous tracts.

Although pilonidal sinus can be treated using several defined conservative and surgical methods, recurrence rate is high [10]. Complete removal of the pilonidal sinus or sinuses and appropriate reconstruction can lead to successful recovery [11]. The simplest is incision and drainage, excision and laying open, excision,

excision and primary closure. The complex one includes flap techniques like BASCOM'S, KARYDAKIS, rhomboid excision with LIMBERG flap, modified LIMBERG transposition flap [12], elliptical rotational flap [13], rotation advancement fasciocutaneous flap [14]. Among different surgical modalities for treatment of sacrococcygeal pilonidal sinus, flap reconstruction technique eradicates the aetiology of the disease by flattening the intergluteal sulcus with much less hairy fasciocutaneous flaps and less perspiration [15]. Aim of this article is to highlight the outcomes and feasibility of Limberg Flap which is a fasciocutaneous flap based on the superior gluteal and sacral perforator for the management of chronic pilonidal sinus disease and comparing results using various parameters in multiple studies.

Materials and Methods

This is a retrospective study on 14 consecutive patients between June 2019-June 2020 in Plastic Surgery Department at GMC, and its associated Hamidia Hospital, Bhopal. Mean duration of diseased symptoms was 2 years. All patients were subjected to complete history taking, local examination and basic lab investigations. Patient with recurrent pilonidal sinus disease underwent this operation. Written consent was obtained from all patients after explanation of the procedure, its complications, and expected results of the flap in this area. All patients were male. The median age of patients was 31 years. All had previous history of surgical intervention.

Surgical Procedure

The natal cleft was shaved the day before the planned surgery. Prophylactic antibiotics- ceftriaxone 1 gm and metronidazole 500 mg were administered intravenously. All operation were done in spinal anaesthesia. Patients were positioned in prone with buttocks strapped apart with adhesive tape. Using a sterile skin marker, a rhomboid shape area in surrounding skin was marked centering pilonidal sinus involving all midline pits and lateral extensions if any. The long axis of the rhomboid in the midline was marked as A-C, C being adjacent to perianal skin. The line B-D transected the midpoint of A-C at the right angle and 60% of its length. It was this ratio of lengths which determined correct shape of the rhomboid. D-E: a direct continuation of the line B-D and was of equal length to the incision B-A to which it was sutured after rotation. E-F was parallel to D-C and of equal length. After rotation, it was sutured to A-D.

The rhomboid incision including the sinus and its extensions is made down to the presacral fascia. The diseased site was removed en-bloc. Flap was constructed by extending the incision laterally and down to the fascia of the gluteus maximus muscle. Flap should be exactly of the same dimensions of the defect made by the excision. Thus a rhomboid shaped fasciocutaneous flap was raised. Hemostasis was achieved and the adhesive tapes which retracted buttocks were released. The flap is transposed into the rhombic defect and was sutured without tension. Subcutaneous tissue is approximated with interrupted vicryl and skin is closed with mattress interrupted manner. Antibiotic were given for 3 days intravenously. Sutures were removed on 10th post operative day. Patients were advised not to put pressure on the flap for 3 weeks. All the patients were evaluated for flap

healing, seroma formation, edema, flap necrosis, surgical site infection, pain and length of hospital stay. The objective grading of pain was done by visual analogue scale [VAS]. The patients were followed at 2 weeks, 3 months and 6 months after the surgery.

Results

A total of 4 patients with recurrent chronic pilonidal sinus disease from Jan 2019 – Jan 2020 had undergone Limberg flap in spinal anaesthesia. All were men with median age of 31 years [range-26 yrs to 40 yrs]. Mean duration of symptoms was 2.6 years [range -1.5 yrs to 4 yrs]. Mean operative time was 59.5 minutes [range-50min-70 min]. 3 [75%] patient had full primary healing without any complication with minimal postoperative pain. 1 [25%] patient had partial gaping of wound edges. However it healed completely with dressing .The minimum length of hospital stay was 6.75 days [6 – 8 days] with pain score [VAS] range was in 2-7 with mean score of 5 . All patients had returned to work within 3 weeks.

Table 1: Demographics Of Patients

Demographic Characteristic	Percentage
Age [Years]	31 (26-40)
Gender	
Male	14
Female	-
Duration Of Symptoms [Years]	2.62 (1.5 – 4)
Operative Time [Minutes]	59.5 (50 – 70)
Pain Score [VAS]	5 (2 - 7)
Postoperative Hospital Stay [Days]	6.75 (6 - 8)

Discussion

Sacroccygeal pilonidal sinus disease is notorious due to prolonged morbidity and recurrence. The ideal treatment should ensure less pain, short hospital stay, period, low risk of complications, rapid return to normal activities, better aesthetic appearance and should have a low recurrence rate.

Excision of the infected tissue and sinus orifices are not considered a major technical problem; thus discussion generally concentrates on the method for reconstructing the defect after excision. Although the primary closure method results in rapid recovery and quick resumption of daily activities but high complication and recurrence rates have been reported [16,17].

Realizing the importance of flattening of natal cleft as well as achieving an off midline closure of the resultant defect required to prevent recurrences and minimize wound related complications [19-21], a tendency toward using flap reconstructions have been established. One of most commonly used flap techniques is Limberg flap reconstructions which is easy to design and perform

and is considered better than other flap procedures such as Bascom and Karydakis [18-21].

The importance of the post operative wound care should also be stressed. Exercise or sitting down on the wound should be avoided for 2 weeks and the patient has to return slowly to normal activities. Hair removal either by creams or shaving the surrounding area is mandatory. This has to be continued at least until complete healing, but preferably for 6 weeks [22].

The common postoperative complications encountered are total /partial flap necrosis, total/partial wound dehiscence, hematoma, seroma, wound infection in early postoperative period and recurrence, hypoesthesia at the operative site, sense of tension /pain in late postoperative period. In this study, no patient had flap necrosis. The rate of development of flap necrosis after limberg flap is 0 to 3.3% of cases [23-26]. UNALP et al [27] reported progressive ischemia and necrosis tissue in only 1 patient (1.5%) who was treated with secondary healing following debridement of the necrotic tissue in their series of 66 patients. TOPGUL et al [25] reported a partial necrosis rate of 3% (6 patients) with the development of necrosis in the upper flap in their series of 200 patients. It was not found in our study.

The rate of development of seroma after limberg flap is 0 to 14.5% of cases [16, 26- 31]. In this study, no patient had developed seroma. MENTES et al [29] reported a seroma rate of 2.2% without placing a drain and a mean duration of hospital stay of 4.51 ± 2.85 days in their series of 353 patients. KIRKIL et al [31] reported the rates of seroma development in groups with and without drains to be 10.7 and 18.5%, respectively (total 14.5%), in their series of 55 patients who were randomized for drain placement with a mean 3.2 days of hospitalization. They reported that all such patients were treated by repeated aspiration of seromas.

The rate of hematoma and wound dehiscence after Limberg Flap are 0 to 4% and 0 to 10.4% respectively [29,32-38]. In our study, no patient had developed hematoma or wound dehiscence. However it is advisable to achieve hemostasis during operation before the closure of defect. The rate of wound infection after the Limberg flap procedure varies from 0 to 8% of cases [19, 40,28,29,34,36,22,23].

The most commonly reported complication in long term studies is the recurrence rate. The reported rates of recurrence following Limberg flap vary between 0 to 9% [1,4,12-16,18- 22,24,26,27,30,31]. Two other long term observations were-hypoesthesia at the operative site and cosmetic satisfaction – that have been reported in only a few studies. In this study, no patient had any long term complication during the follow up of 1year.

The Advantages of Limberg Flap reconstructions are:

- Flattens the natal cleft with a large well vascularised pedicle that can be sutured without tension
- Midline dead space and scar is avoided
- Useful in complex sinuses with multiple pits where radical excision leaves large defect.
- Easy to perform and learn.
- Useful in recurrent pilonidal sinus disease

- Reduces hospital stay and time to resume normal activities

Conclusion

Limberg flap reconstruction in chronic recurrent pilonidal sinus is effective, reliable and one time solution with low complication rates, short hospital stay, low recurrence rate, easier technique which results in earlier healing, less scarring and subjectively high patient satisfaction.

References

- [1] Clothier PR, Haywood IR. The natural history of the post anal pilonidal sinus. *Ann R College Surg England*. 1984;6(3):201-3.
- [2] Humphries AE, James E. Evaluation and management of pilonidal disease. *Surg Clin North Am*. 2010;90(1):113-24.
- [3] Sondana K, Andersen E. Patient characteristics and symptoms of in chronic pilonidal sinus disease. *Int J Colorectal Dis*. 1995;10(1):39-42.
- [4] McCallum I, King PM, Bruce J. Healing by primary versus secondary intention after surgical treatment for pilonidal sinus. *Cochrane Database Syst Rev* 2007(4): CD006213.
- [5] Sondana K, Andersen E, Nesvik I, Soreide JA. Patient characteristics and symptoms in chronic pilonidal sinus disease. *Int J Colorectal Dis* 1995; 10(1):39-42.
- [6] Onder A, Girgin S, Kapan M, Toker M, Arikanoglu Z, Palanci Y et al. Pilonidal sinus disease: risk factors for postoperative complications and recurrence. *Int Surg*. 2012 Jul-Sep; 97(3): 224-9.
- [7] Brearley R. Pilonidal sinus: a new theory of origin. *Br J Surg*. 1955;43:62-8.
- [8] Karydakakis GE. Easy and successful treatment of pilonidal sinus after explanation of its causative process. *Aust NZJ Surg*. 1992;62:385-9.
- [9] Bascom J. Pilonidal disease: origin from follicles of hairs and results of follicle removal as treatment. *Surgery* 1980; 87:567-72.
- [10] Urhan MK, Kucukel F, Topgul K, Ozer I, Sari S. Rhomboid excision and Limberg flap for managing pilonidal sinus: results of 102 cases. *Dis Colon Rectum*. 2002;45(5):656-9.
- [11] Yildiz MK, Ozkan E, Odaba M, Kaya B, Eris C, Abuoglu HH, et al. Karydakakis flap procedure in patients with sacrococcygeal pilonidal sinus disease: experience of a single centre in Istanbul. *Scientific World J*. 2013.
- [12] Cihan A, Ucan BH, Comert M, Cesur A, Cakmak GK, Tascilar O. Superiority of asymmetric modified Limberg flap for surgical treatment of pilonidal disease. *Dis Colon Rectum*. 2006;49(2):244-9.
- [13] Nessar G, Kayaalp C, Seven C. Elliptical rotation flap for pilonidal sinus. *Am J Surg*. 2004;187:3.
- [14] Schoeller T, Wechselberger G, Otto A, Papp C. Definite surgical treatment of complicated recurrent pilonidal disease with a modified fasciocutaneous VY advancement flap. *Surg*. 1997;121(3):258-63.
- [15] Khatri VP, Espinosa MH, Amin AK. Management of recurrent pilonidal sinus by simple V-Y fasciocutaneous flap. *Dis Colon Rectum*. 1994;37:1232e-5.
- [16] Urhan M, Kucukel F, Topgul K, Ozer I, Sari S. Rhomboid excision and Limberg flap for managing pilonidal sinus: results of 102 cases. *Dis Colon Rectum* 2002;45(5):656-659

- [17] Holm J, Hulthen L. Simple primary closure for pilonidal disease. *Acta Chir Scand* 1970;136(6):537-540
- [18] Dass TA, Zaz M, Rather A, Bari S. Elliptical excision with midline primary closure versus rhomboid excision with Limberg flap reconstruction in sacrococcygeal pilonidal disease: a prospective, randomized study. *Ind J Surg* 2012; 74(4):305-308
- [19] Akca T, Colak T, Ustunsoy B, Kanik A, Aydin S. Randomized clinical trial comparing primary closure with the Limberg flap in the treatment of primary sacrococcygeal pilonidal disease. *Br J Surg* 2005;92(9):1081-1084
- [20] Ates M, Dirican A, Sarac M, Aslan A, Colak C. Short and longterm results of the Karydakias flap versus the Limberg flap for treating pilonidal sinus disease: a prospective randomized study. *Am J Surg* 2011;202(5):568-573
- [21] Katsoulis IE, Hibberts F, Carapeti EA. Outcome of treatment of primary and recurrent pilonidal sinuses with the Limberg flap. *Surgeon* 2006;4(1):7-10
- [22] Bozkurt MK, Tezel E. Management of pilonidal sinus with the Limberg flap. *Dis Colon Rectum* 1998;41(6):775-777
- [23] Daphan C, Tekelioglu MH, Sayilgan C. Limberg flap repair for pilonidal sinus disease. *Dis Colon Rectum* 2004;47(2):233-237
- [24] Menten O, Bagci M, Bilgin T, Ozgul O, Ozdemir M. Limberg flap procedure for pilonidal sinus disease: results of 353 patients. *Langenbecks Arch Surg* 2008;393(2):185-189
- [25] Topgul K, Ozdemir E, Kilic K, Gökbayir H, Ferahköse Z. Longterm results of Limberg flap procedure for treatment of pilonidal sinus: a report of 200 cases. *Dis Colon Rectum* 2003; 46(11):1545-1548
- [26] Aithal SK, Rajan CS, Reddy N. Limberg flap for sacrococcygeal pilonidal sinus a safe and sound procedure. *Ind J Surg* 2013;75(4):298-301
- [27] Unalp HR, Derici H, Kamer E, Nazli O, Onal MA. Lower recurrence rate for Limberg vs. V-Y flap for pilonidal sinus. *Dis Colon Rectum* 2007;50(9):1436-1444
- [28] Okus A, Sevinç B, Karahan O, Eryilmaz MA. Comparison of Limberg flap and tension-free primary closure during pilonidal sinus surgery. *World J Surg* 2012;36(2):431-435
- [29] Ersoy E, Devay AO, Aktimur R, Doganay B, Ozdogan M, Gundogdu RH. Comparison of the short-term results after Limberg and Karydakias procedures for pilonidal disease: randomized prospective analysis of 100 patients. *Colorectal Dis* 2009;11(7):705-710
- [30] Erdem E, Sungurtekin U, Nessar M. Are postoperative drains necessary with the Limberg flap for treatment of pilonidal sinus? *Dis Colon Rectum* 1998;41(11):1427-1431
- [31] Kirkil C, Büyük A, Bülbüller N, Aygen E, Karabulut K, Coşkun S. The effects of drainage on the rates of early wound complications and recurrences after Limberg flap reconstruction in patients with pilonidal disease. *Tech Coloproctol*. 2011 Dec;15(4):425-9.
- [32] Kapan M, Kapan S, Pekmezci S, Durgun V. Sacrococcygeal pilonidal sinus disease with Limberg flap repair. *Tech Coloproctol* 2002;6(1):27-32
- [33] Cubukcu A, Gonullu NN, Paksoy M, Alponat A, Kuru M, Ozbay O. The role of obesity on the recurrence of pilonidal sinus disease in patients, who were treated by excision and Limberg flap transposition. *Int J Colorectal Dis*. 2000;15(3):173-175
- [34] Dass TA, Zaz M, Rather A, Bari S. Elliptical excision with midline

- primary closure versus rhomboid excision with Limberg flap reconstruction in sacrococcygeal pilonidal disease: a prospective, randomized study. *Ind J Surg* 2012; 74(4):305-308
- [35] Akca T, Colak T, Ustunsoy B, Kanik A, Aydin S. Randomized clinical trial comparing primary closure with the Limberg flap in the treatment of primary sacrococcygeal pilonidal disease. *Br J Surg* 2005;92(9):1081-1084
- [36] Ates M, Dirican A, Sarac M, Aslan A, Colak C. Short and longterm results of the Karydakis flap versus the Limberg flap for treating pilonidal sinus disease: a prospective randomized study. *Am J Surg* 2011;202(5):568-573.
- [37] Katsoulis IE, Hibberts F, Carapeti EA. Outcome of treatment of primary and recurrent pilonidal sinuses with the Limberg flap. *Surgeon* 2006;4(1):7-10
- [38] Khan PS, Hayat H, Hayat G. Limberg flap versus primary closure in the treatment of primary sacrococcygeal pilonidal disease: a randomized clinical trial. *Indian J Surg* 2013;75(3): 192-194.
- [39] Ertan T, Koc M, Gocmen E, Aslar AK, Keskek M, Kilic M. Does technique alter quality of life after pilonidal sinus surgery? *Am J Surg* 2005;190(3):388-392.
- [40] Eryilmaz R, Sahin M, Alimoglu O, Dasiran F. Surgical treatment of sacrococcygeal pilonidal sinus with the Limberg transposition flap. *Surgery* 2003;134(5):745-749.
- [41] Suryasa, I. W., Rodríguez-Gámez, M., & Koldoris, T. (2022). Post-pandemic health and its sustainability: Educational situation. *International Journal of Health Sciences*, 6(1), i-v. <https://doi.org/10.53730/ijhs.v6n1.5949>

Figures

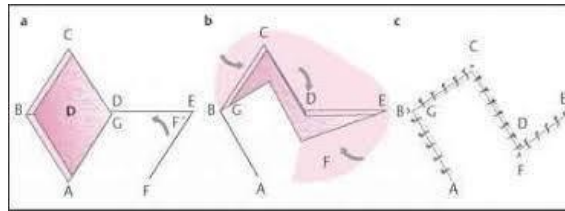


FIG 1: Planning of Limberg Flap

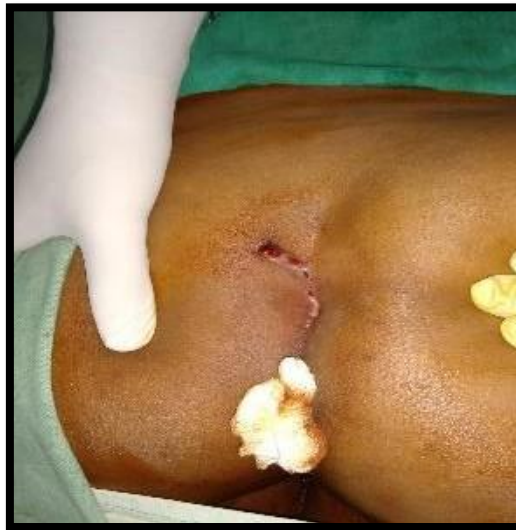

Fig 2: Preoperative picture showing Pilonidal Sinus Complex with lateral extension

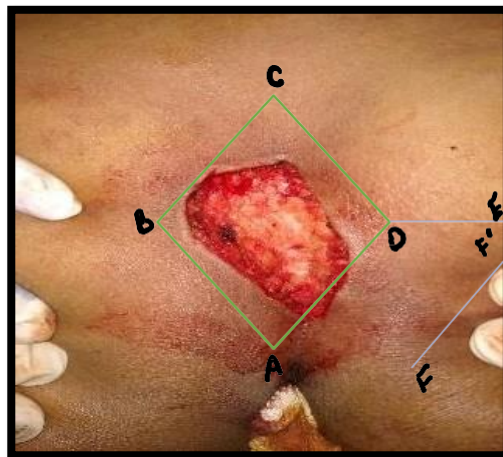


Fig 3: Excision Of Pilonidal Sinus en-bloc ,creating rhomboid defect [green: rhomboid defect, purple: planning of flap]

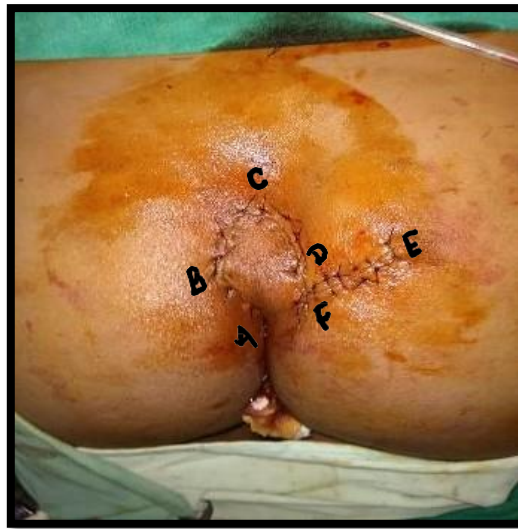
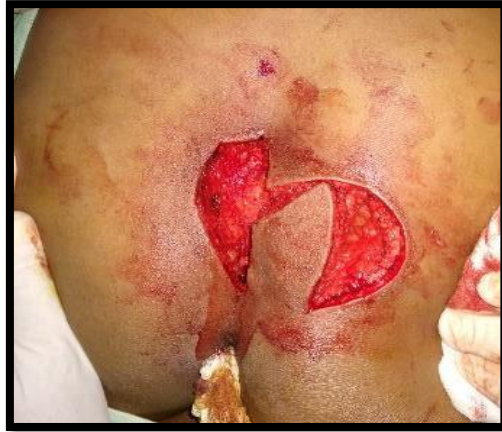
Fig 5: After skin closure in Limberg Flap Reconstructions