

How to Cite:

Al-Bakir, S. S. H. A., & Abdalshaheed, D. A. (2022). Isolation and identification of cryptococcus neoformans from local cats in Baghdad province. *International Journal of Health Sciences*, 6(S4), 5091–5098. <https://doi.org/10.53730/ijhs.v6nS4.9279>

Isolation and identification of Cryptococcus neoformans from local cats in Baghdad province

Sara Saad Hussam aldeen Al-Bakir

Department of Microbiology, College of Veterinary Medicine, University of Baghdad, Baghdad, Iraq

Email: saadsara434@gmail.com

Dalia Abdalkareem Abdalshaheed

Department of Microbiology, College of Veterinary Medicine, University of Baghdad, Baghdad, Iraq

Corresponding author email: dalia@covm.uobaghdad.edu.iq

Abstract---This study provides a brief review of approaches for detection of fungi that cause pulmonary infection in cats. The 40 samples were taken randomly from local Iraqi cats in Baghdad province to detect fungal infection that causes respiratory disease in cats, especially *Cryptococcus neoformans* that is considered one of the most important pathogens causing respiratory symptoms in cats, studied and isolated during the period of October 2021 to March 2022. Samples were taken from infected cats in a veterinary clinic in Baghdad province; all samples were cultured on Sabouraud Dextrose Agar, Bird Seed Agar and Cryptococcus Differential Agar for *Cryptococcus* spp. isolation and identification. The results showed that 40 swaps taken from the pharynx of infected cats, included: *Cryptococcus neoformans* 12 (30.0%), *Aspergillus fumigatus* 2 (5.0%), *Penicillium* spp. 6 (15.0%), *Aspergillus niger* 3 (7.5%), *Dimatiaceous* spp. 1 (2.5%), *Fusarium* spp. 1 (2.5%), *Rhizopus* spp. 2 (5.0%), *Candida* spp. 3 (7.5%), *Aspergillus* spp. 10 (25.0%) and the presence of infection in female (60%) more than male (40%). These findings indicate that there may be a risk for animal exposure to pulmonary fungal disease due to inhalation of fungal spores, contaminated environment, hormonal disturbance in female, viral infection that causes immune deficiency.

Keywords---*Cryptococcus neoformans*, fungal infection, feline respiratory infection.

Introduction

Cryptococcosis in animals is a systemic fungal infection of worldwide significance that usually initially infects the nasal cavity, paranasal tissues, or lungs. It can then disseminate, most commonly to the skin, eyes, or central nervous system, and its caused by *Cryptococcus neoformans* and *C. gattii*, which are ubiquitous, saprophytic, round, basidiomycetous yeasts (5 to 10 μm) with a large heteropolysaccharide capsule (1 to 30 μm) that does not take up common cytologic stains (1, 2). Cryptococcosis is an infection that is acquired as a result of inhalation of spores or dehydrated yeast cells from environmental sources such as plant materials or soil as well as bird excreta (3, 4). The environmental reservoir of *C. neoformans* is usually related to bird faeces, particularly pigeon droppings. However, this yeast has also been found in decaying trees, wood and plant debris, waterways and soil, all usually contaminated with bird excrement (5, 6, 7).

Cryptococcosis is the most common systemic fungal infection of cats and should be considered in the differential diagnosis of cats presenting with respiratory tract disease, subcutaneous nodules, lymphadenopathy, intraocular inflammation, fever, or disease of the central nervous system (8). The most common site of localized infections is the nasal cavity. Nasal cryptococcosis is frequently seen clinical signs including sneezing, snoring or snorting, dyspnea, nasal deformities and/ or a mucopurulent, serous or sero-sanguineous nasal discharge. Polyp-like masses sometimes protrude from one or both nostrils. Cutaneous or subcutaneous swellings and nodules may be seen on the face, particularly the bridge of the nose, side of the face, upper lip or nostril. Some of these lesions may ulcerate. In addition, the submandibular lymph nodes are often enlarged. Rhinitis in cats was reported to be caused by *C. neoformans var. neoformans* (9, 10) and with time, infections involving the nasal cavity can spread to adjacent structures and disseminate to other organs (11), including the brain (12), eyes (29), and even the skin (13). Therefore, the aims of this research were toisolation and identification of *Cryptococcus neoformans* from local cats in Baghdad province.

Material and Methods

Samples collection

A total of 40 samples were collected from infected cats in veterinary clinic in Baghdad province in period from (October 2021- March 2022). Samples were collected from cats suffering from respiratory symptoms.

Isolation and identification of *Cryptococcus neoformans*

Samples isolated and identified by take a swab from pharynx of infected cats and streaked on surface of Sabouraud Dextrose Agar, and subcultured on Bird Seed Agar and Cryptococcus Differential Agar.The isolation and identification of *Cryptococcus neoformans* depend on morphological features.

Macroscopic Appearance

Macroscopic appearance was determined by examination of the (shape, color, edges of colonies, consistency), and other apparent characteristic features of colonies of *Cryptococcus neoformans* (14, 15).

Microscopic appearance

Considered a preliminary diagnosis of fungi infection, detection of the cell shape of *Cryptococcus neoformans* was done by taking one drop of lactophenol cotton blue stain on the slide with colonies of yeast, then the slide covered with coverslip and examined on 40X lens.

Results

Forty of oropharynx swabs that grew on Sabouraud Dextrose Agar positive results for presence of fungus spp. and taken from infected cats included: *Cryptococcus neoformans* 12 (30.0%), *Aspergillus fumigatus* 2 (5.0%), *Penicillium* spp.6 (15.0%), *Aspergillus niger* 3 (7.5%), *Dematiaceous* spp. 1 (2.5%), *Fusarium* spp. 1 (2.5%), *Rhizopus* spp. 2 (5.0%), *Candida* spp. 3 (7.5%), and *Aspergillus* spp. 10 (25.0%), (Table 1).

Table (1): The number of fungi isolates from cats pharynx

Fungal spp.	Isolation No.	Percentage%
<i>Cryptococcus neoformans</i>	12	30
<i>Aspergillus fumigatus</i>	2	5
<i>Penicillium</i>	6	15
<i>Aspergillus niger</i>	3	7.5
<i>Dematiaceous</i> spp.	1	2.5
<i>Fusarium</i> spp.	1	2.5
<i>Rizopus</i> spp.	2	5.0
<i>Candida</i> spp.	3	7.5
<i>Aspergillus</i> spp.	10	25.0
Total	40	100%

The percentage of incidence of infection relative to gender show increase in female (60%) than the male (40%), (Table 2).

Table (2): The Number of fungi isolate relative to gender

No. of isolates	Species	No. Male	No. Female
12	<i>Cryptococcus neoformans</i>	4	8
2	<i>Aspergillus fumigatus</i>	2	0
6	<i>Penicillium</i> spp.	2	4
3	<i>Aspergillus niger</i>	2	1
1	<i>Dematiaceous</i> spp.	0	1

1	<i>Fusarium</i> spp.	0	1
2	<i>Rizopus</i> spp.	1	1
3	<i>Candida</i> spp.	1	2
10	<i>Aspergillus</i> spp.	4	6
Total 40		40%	60%

Isolation and identification of *Cryptococcus neoformans*

Cryptococcus neoformans were described based on morphological characteristic of culture medium, in both microscopic appearance and microscopic appearance.

Macroscopic Appearance

Sabouraud-Dextrose Agar

Cryptococcus neoformans was cultivated on Sabouraud Dextrose Agar, the colonies appeared as thin, smooth white to cream colored, mucoid, glistening, round or oval colonies at 37°C for 5 days after inoculation (Figure 1).

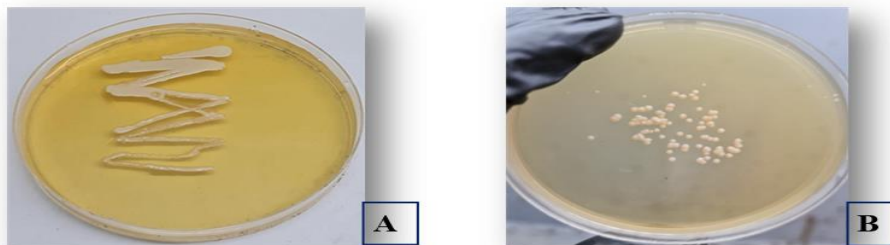


Figure (1): Macroscopic appearance of *Cryptococcus neoformans* colonies on Sabouraud Dextrose Agar (A) at 5 days at 37°C (B) at 3 days at 37°C

Bird Seed Agar medium

Cryptococcus neoformans appeared on Bird Seed Agar and produced (Brown colored) melanin pigment, after 3-5 days of incubation at 37°C (Figure 2).

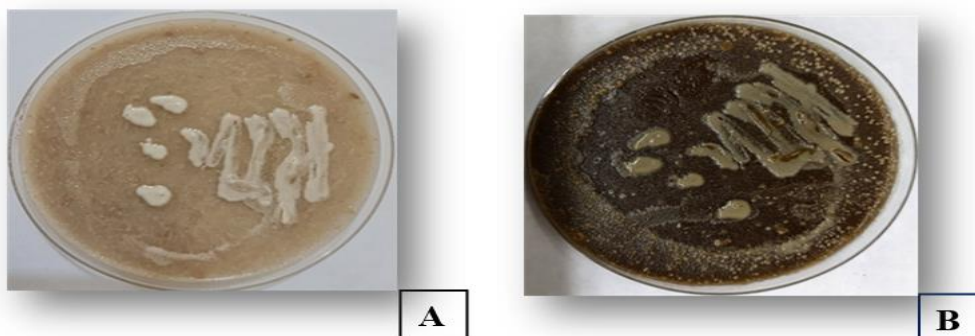


Figure (2): *Cryptococcus neoformans* colonies on Bird Seed Agar (A) 2 days after cultivation at 37°C (B) at 5 days produce melanin pigment at 37°C

Cryptococcus Differential Agar medium

Cryptococcus Differential Agar recommended for a differentiation of *Cryptococcus* species, *Cryptococcus neoformans* when grow on this media give light blue, dry colonies; when incubation at 37°C (Figure 3).

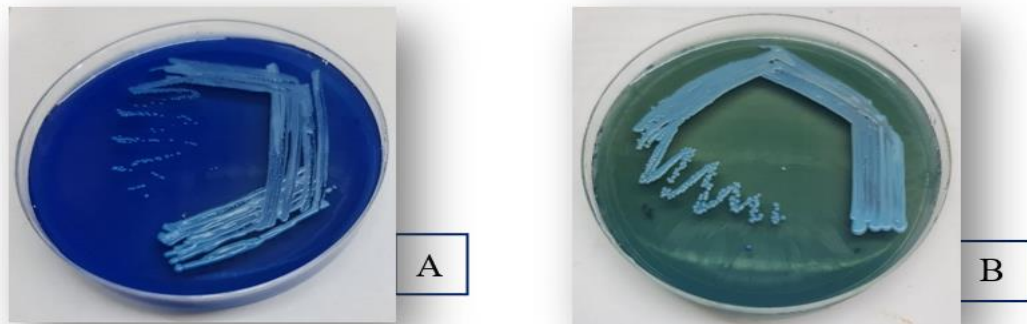


Figure (3): *Cryptococcus neoformans* colonies on Cryptococcus Differential Agar. (A) After 5 days of incubation at 37°C (B) After 14 days of incubation at 37°C

Microscopic appearance

Cryptococcus neoformans when examined under a light microscope at (40X); and stained with (lactophenol cotton Blue) stain, showed of Pseudohyphae with clusters of budding cells, round to oval cell, and when stained with (India ink) showed encapsulated budding yeast cells as in figure (4).

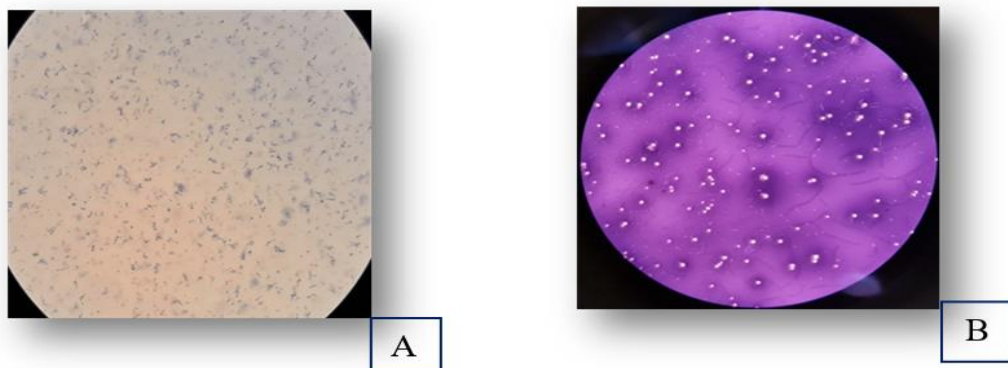


Figure (4): *Cryptococcus neoformans* at 40X (A) appear as round to oval cells with lactophenol cotton blue stain (B) show encapsulated budding yeast cells with India ink stain

Discussion

The result showed that the *Cryptococcus neoformans* which isolated from pharynx of infected cats was 12 (30.0%), this result is agreement with (16). This result may indicate that the fungal infection is primary pulmonary cryptococcosis; this

evidence agreed with definition of pulmonary cryptococcosis (17, 18). The fungal isolates from females were more than that isolated from males and this is consistent with (16, 19). The percentage of *Aspergillus* spp.; in the cat pharynx infection was 10 (25.0 %) that is agreement (20), while *penicillium* spp. was 6 (15.0%) and that is agreement with (17, 21, 22) and the percentage of *Aspergillus niger* was (7.5%) this results was agreement with (23), also *Candida* spp. was (7.5%) this results was agreement with (24, 25, 26). But the percentage of *Fusarium* spp. was (5.0%) that agreement with (27, 28). Also in *Rizopus* spp. the percentage was (5.0%) that agreement with (29). While other spp. was present in less percentage like *Dematiaceous* spp. (2.5%) it is a common soil saprophyte and an important pathogen; and has ability to surface adherence and produce protease and collagenases, and microorganism causes infection which can be locally invasive lung or disseminated to other organ (30, 31, 32). *Cryptococcus neoformans* colonies on Bird Seed Agar produces brown colored melanin pigment due to its produces enzyme phenoloxidase, which necessary in melanin synthesis and causing the formation of brown pigmented colonies (33) which considered as a positive result for melanin production and this result agreement with (3,14). While *Cryptococcus neoformans* when grow on Cryptococcus Differential Agar media give light blue, dry colonies; when incubation at 37°C, this pigment is not apparent on the first day of growth but is usually noticeable after 5 days of incubation, intensity gradually increases with time (34) due to *C. neoformans* cannot assimilate D-tryptophan (35).

Reference

1. Kwon-Chung K.J., T. Boekhout, J.W. Fell, M. Diaz. (2002). Proposal to conserve the name *Cryptococcus gattii* against *C. hondurianus* and *C. European Journal of Academic Essays*, 51 (4), 804–806
2. Kwon-Chung K.J., A. Varma. Do major species concepts support one, two or more species within *Cryptococcus neoformans*? *FEMS Yeast Res.*, 6 (4) (2006), pp. 574–587
3. Kwon-Chung, K. J. et al. *Cryptococcus neoformans* and *Cryptococcus gattii*, the etiologic agents of cryptococcosis. *Cold Spring Harb. Perspect. Med.* 4, a019760 (2014).
4. Cogliati, M. et al. Environmental distribution of *Cryptococcus neoformans* and *C. gattii* around the Mediterranean Basin. *FEMS Yeast Res.* 16, 045. <https://doi.org/10.1093/femsyr/fow045> (2016).
5. Refai, M. K., M El-Hariri, R Alarousy Monograph on *Cryptococcus* and cryptococcosis., 2014 <http://scholar.cu.edu.eg/?q=hanem/book/>
6. El-Hariri M, D. Hamza, R. Elhelw, and M. Refai, “Lovebirds and cockatiels risk reservoir of *Cryptococcus neoformans*, a potential hazard to human health,” *Journal of Veterinary Science and Medical Diagnosis*, vol. 4, no. 4, 2015.
7. El-Hariri M, Dalia Hamza, Rehab Elhelw, and Mohamed Refai, “Eucalyptus Tree: A Potential Source of *Cryptococcus neoformans* in Egyptian Environment,” *International Journal of Microbiology*, vol. 2016, Article ID 4080725, 5 pages, 2016. doi:10.1155/2016/4080725 Richard
8. Richard M. Green CE. *Cryptococcosis, Infectious Diseases of Dog and Cat*, 2006 3rd ed St. Louis, MO Saunders Elsevier (pg. 584-598) Google Scholar

9. Barrs, V., Martin, P., Nicoll, R., Beatty, J. And Malik, R. (2000), Pulmonary cryptococcosis and *Capillaria aerophila* infection in an FIVpositive cat. *Australian Veterinary Journal*, 78: 154–158.
10. Beatty , J A , V R Barrs, G R Swinney, P A Martin, R Malik . Peripheral Vestibular Disease Associated with Cryptococcosis in Three Cats. *Journal of Feline Medicine and Surgery* Volume 2, Issue 1, March 2000, Pages 29–34
11. Meng H C, Lu C H, Wang H C, Chen H L, Tsai N W, Li S H, Hsu N W, Lin W M, Kung C T and LinW C 2015: Long-Term Neuropsychological Sequelae in HIVSeronegative Cryptococcal Meningoencephalitis Patients with and without Ventriculoperitoneal Shunts: A Cine MRI Study. *Behavioural Neurology*. 2015: 1-10. <http://dx.doi.org/10.1155/2015/356476>
12. Lester , S. J. , Natalie J. Kowalewich, Karen H. Bartlett, Mark B. Krockenberger, Theyne M. Fairfax, Richard Malik, Clinicopathologic features of an unusual outbreak of cryptococcosis in dogs, cats, ferrets, and a bird: 38 cases (January to July 2003). *J Am Vet Med Assoc* 2004;225:1716–1722 .
13. Medleau L, Hall EJ, Goldschmidt MH, Irby N. Cutaneous cryptococcosis in three cats. *J Am Vet Med Assoc*. 1985 Jul 15;187(2):169-70.
14. Palkova Z, Vachova L. Life within a community: benefit to yeast long-term survival. *FEMS Microbiol Rev*. 2006;30(5):806–24. pmid:16911045.
15. Gupta G, Fries BC. Variability of phenotypic traits in *Cryptococcus* varieties and species and the resulting implications for pathogenesis. *Future Microbiol*. 2010;5(5):775–87. pmid:20441549; PubMed Central PMCID: PMC2897164.
16. Mahmood, F. A. (2015). Isolation and Identification of *Cryptococcus neoformans* from Human Skin Lesions and Application of Animal Experiment (in vivo): Mahmood FA and Alwan MJ. *The Iraqi Journal of Veterinary Medicine*, 39(1), 85-89.
17. Nadrous HF, Antonios VS, Terrell CL, et al. Pulmonary cryptococcosis in nonimmunocompromised patients. *Chest* 2003;124: 2143 –7
18. Brizendine, K. D., Baddley, J. W., and Pappas, P. G. (2011, December). Pulmonary cryptococcosis. In *Seminars in respiratory and critical care medicine* (Vol. 32, No. 06, pp. 727-734). © Thieme Medical Publishers.
19. Francisco, A; Marta, P. and Alvarez, R.(2007).Primary Cutaneous Cryptococcosis presenting as a whitlow. *Acta Dermato-Venereologica*, 87: 443-447.
20. McLellan GJ, Aquino SM, Mason DR *et al*. Use of posaconazole in the management of invasive orbital aspergillosis in a cat. *Journal of the American Animal Hospital Association* 2006; 42: 302– 307.
21. Tomsa K, Glaus TM, Zimmer C *et al* . Fungal rhinitis and sinusitis in three cats. *Journal of the American Veterinary Medical Association* 2003; 222(1380–1384): 1365.
22. Whitney BL, Broussard J, Stefanacci JD. Four cats with fungal rhinitis. *Journal of Feline Medicine and Surgery* 2005; 7: 53– 58
23. Barrs VR, Talbot JJ (2014) Feline aspergillosis. *Veterinary Clinics of North America: Small Animal Practice*, 44, 51e73.
24. Ship J.A. 2003. Diabetes and oral health: an overview. *Journal of American Dental Association* 134 (supl.): 4-10.
25. Zawirska A., Adamski Z. 2004. Systemic fungal infections – a tip of the iceberg? *Nowiny Lekarskie* 73: 479-482.

26. Belazi M., Velegraki A., Fleva A., Gidarakou I., Papanauum L., Baka D., Daniilidou N., Karamitsos D. 2005. Candidal overgrowth in diabetic patients: potential predisposing factors. *Mycoses* 48: 192-196.
27. Bulpa P, Dive A, Sibille Y. Invasive pulmonary aspergillosis in patients with chronic obstructive pulmonary disease. *Eur Respir J* 2007; 30: 782–800.
28. Al-Alawi A, Ryan CF, Flint JD, et al. Aspergillus-related lung disease. *Can Respir J* 2005; 12: 377–387
29. Kontoyiannis D. P. and Lewis R. E..2006. Invasive zygomycosis: update on pathogenesis, clinical manifestations, and management. *Infect. Dis. Clin. North Am.* 20:581–607.
30. Ozgun, G., and Borsa, B. (2012). A rare but diagnostic fungal microorganism in cervical Pap smears. *Indian Journal of Pathology and Microbiology*, 55(4), 606-606.
31. Lungran, A. Vijaya Devi, W.S. Singh, S. Damroulien, H. Mate, A. Golmei, Cryptococcosis: its prevalence and clinical presentation among HIV positive and negative patients in Rims, Manipur, IOSR J. Dent. Med. Sci. 13 (7) (2014) 38–41.
32. Gharban, H. A., and Yousif, A. A. (2020). Serological and Molecular Phylogenetic Detection of *Coxiella burnetii* in Lactating Cows, Iraq. *The Iraqi Journal of Veterinary Medicine*, 44(E0), 42-50.
33. Jarvis, J.N.T. Bicanic, A. Loyse, D. Namarika, A. Jackson, J.C. Nussbaum...K. Taseera, Determinants of mortality in a combined cohort of 501 patients with HIV-associated Cryptococcal meningitis: implications for improving outcomes, *Clin. Infect. Dis.* 58 (5) (2014) 736–745.
34. Palkova Z, Vachova L. Life within a community: benefit to yeast long-term survival. *FEMS Microbiol Rev.* 2006;30(5):806–24. pmid:16911045.
35. Chaskes,S., Frases, S., Cammer, M., Gerfen, G, and Casadevall, A. (2008).Growth and Pigment Production on D-Tryptophan Medium by *Cryptococcus gattii*, *Cryptococcus neoformans*, and *Candida albicans* . *J. Clin. Microbiol.* 46 : 255-264.
36. Baro, T., J.m. Torres-Rodriguez, M.H. De Mendoza, Y. Morera, and C.Alia. 1998 First identification of autochthonous *Cryptococcus neoformans* var. *gattii* isolated from goats with predominantly severe pulmonary disease in Spain. *J.Clin. Microbiol.* 36:458-461.
37. Suryasa, I. W., Rodríguez-Gámez, M., & Koldoris, T. (2021). The COVID-19 pandemic. *International Journal of Health Sciences*, 5(2), vi-ix. <https://doi.org/10.53730/ijhs.v5n2.2937>
38. Akbarov, A. N., & Xabilov, D. N. U. (2021). The condition of the oral cavity in patients who have had a viral infection COVID-19. *International Journal of Health & Medical Sciences*, 4(4), 381-383. <https://doi.org/10.21744/ijhms.v4n4.1796>