

**How to Cite:**

Mohammed, W. F. F., Elbarbary, H., Abdullatif, S., Mohammed, A. S., El Aziz Mahmoud, A. M. A., & Hussien, H. A. A. (2022). The use of LRS mono-lateral external fixator for the treatment of comminuted femoral fracture with bone loss. *International Journal of Health Sciences*, 6(S5), 3884–3897. <https://doi.org/10.53730/ijhs.v6nS5.9459>

# The use of LRS mono-lateral external fixator for the treatment of comminuted femoral fracture with bone loss

**Waleed Fayez Fahmy Mohammed**

Consultant of orthopaedic surgery, Military medical services, Cairo, Egypt  
Corresponding author email: [wfayezfahmy@gmail.com](mailto:wfayezfahmy@gmail.com)

**Hassan Elbarbary**

Professor of Orthopaedic Surgery, Faculty of Medicine, Cairo University, Egypt

**Sheriff Abdullatif**

Professor of Orthopaedic Surgery, Faculty of Medicine, Cairo University, Egypt

**Ahmed Samy Mohammed**

Lecturer of Orthopaedic Surgery, Faculty of Medicine, Cairo University, Egypt

**Ahmed Maher Abd El Aziz Mahmoud**

Consultant of orthopaedic surgery, Military medical services, Cairo, Egypt  
Email: [drahmaheross@gmail.com](mailto:drahmaheross@gmail.com)

**Hisham Al Ashry Hussien**

Head of orthopaedic department, Al Helmya military hospital, Military academy, Cairo, Egypt.  
Email: [mostafahesho@gmail.com](mailto:mostafahesho@gmail.com)

**Abstract--Background:** Comminuted fracture femur with bone loss is a high energy injury with variable clinical and radiological scenarios; therefore, management has been a challenge to Orthopaedic surgeons because of associated complications and absence of standard guidelines to organize the different treatment options. The aim of the work is to assess radiological and functional results of managing comminuted fracture femur with bone loss by mono lateral external fixator, study the technique of application and related complication. **Methods:** This retrospective case series study was done in May 2010 to December 2016 with mean follow up period 1.5 years and included 21 patients who were divided into two main groups, group (I) included 11 patients managed by acute shortening and distraction, and the group (II) included 10 patients managed by bone transport technique. Outcome in both groups was compared regarding time to union

(external fixator time), length gained, healing index (external fixator time/length gained), bone results and functional results according to Paley. Complications in both groups have been compared and classified according to Paley into 3 categories: problems, obstacles, and sequelae. *Results:* The mean EFI was lower in group II (mean: 52.8 days/cm; range: 32.3–70) than in group I (mean 60.8 days/cm; range: 45–76.5) ( $p = 0.118$ ) (Table 4). The mean EFT was shorter in group I (mean: 7.7 months; range: 5–9 months) than in group II (mean: 10 months; range: 7–18 months) ( $p = 0.017$ ). With respect to the bone and functional results, no difference was observed in Paley scores between the groups ( $p = 0.96$  for bone and  $p = 0.18$  for functional scores). *Conclusion:* the application of mono-lateral external fixator is an effective and reliable method to achieve satisfactory outcome in cases of comminuted fracture femur with bone loss with preference of acute compression and distraction technique to shorten the duration of treatment and limit the rate of complication.

**Keywords**--LRS, femoral bone loss, external fixation.

## Introduction

Comminuted fracture femur with bone loss is a high energy injury with variable clinical and radiological scenarios; therefore, management has been a challenge to Orthopaedic surgeons because of associated complications and absence of standard guidelines to organize the different treatment options. <sup>(1)</sup> A systematic review of 24 studies including meta-analyses of Ilizarov methods in the treatment of bone defects of tibia and femur, showed that only 6 studies included femur with limited number of cases. <sup>(2)</sup> Application of mono lateral external fixator for femoral bone transport to manage these cases has rarely been assessed in the literature with only seven studies found in the last 10 years with a limited number of cases. <sup>(3-7)</sup> This study hypothesizes that managing these injuries by mono lateral external fixator provides good to excellent radiological and functional outcomes.

## Material & Methods

The study was conducted on 21 patients sustained bone loss due to comminuted fracture femur diagnosed and treated between May 2010 to December 2016 with the criteria given in table 1:

Table (1): Eligibility criteria for the study

Inclusion criteria:	Exclusion criteria:
Fractures of femoral shaft. segmental defects more than 2 cm. Extra-articular fractures. Open fractures Gustilo III.	Pathological fractures Intra-articular fracture Vascular injury Fracture associated with neurological, metabolic, or congenital disorders.

The study was approved by the local ethics committee at Cairo university department of Orthopaedic surgery, informed consent from each patient was obtained. Demographic data of the patients were collected, including name, address, contact numbers, sex, occupation, age, affected side. 8 Cases were heavy smokers with more than 20 cigarettes per day, 4 of them were in group (1) and other 4 patients were in group (2). Three patients suffered from hypertension, otherwise there was no other problems of medical importance. Patients presented in the first 3 weeks were considered presented acutely, while those who presented later than 3 weeks were categorized under delayed presentation.

### **Acute presentation**

7 Patients in group (1) and 8 patients in group (2) who presented acutely had initial evaluation utilizing ATLS protocol to ensure good circulation to the limb, assess neurological deficits and local skin and soft tissue status. All cases had peripheral good circulation, no neurological deficits and Gustilo III open fracture femur with varying degrees of bone loss. Cephalosporin with aminoglycosides were introduced in the first hour of presentation followed later by proper antibiotics adjusted according to culture and sensitivity. Thorough single or multiple debridement have been undertaken to remove all necrotic tissues, contaminants, and non-viable bone fragments. Provisional realignment of the fracture achieved by applying mono-lateral external fixator with screws insertion sites placed reasonably to avoid site of future osteotomy and any possible plastic surgery intervention. By the end of initial assessment stage, the aim of having provisionally aligned fracture of the femur with varying degrees of bone loss and clean, soft tissue bed is reached.

Delayed presentations:

Group (1): 4 cases number 4,7,10 and 11 have delayed presentation, previous debridement surgeries with no previous metal work installed.

Group (2): 4 cases number 1, 14, 16 and 19 have delayed presentation with case 1 had previous plating and cement spacer which has been removed at the same session.

### **Clinical evaluation and outcome measures**

All patients were assessed for the following items:

**Gait:** The gait was assessed in all patients before definitive treatment. All patients were able to move aided by crutches with partial or non-weight bearing on the affected limb.

**Local skin condition:** Local skin condition was examined for signs of infection. All had closed healed wounds without visible signs of infection or inflammation.

**Limb discrepancy:** The patients in this study had shortening of the affected limb due to bone loss, amount of shortening was assessed clinically with tape method to measure the distance between the anterior superior iliac spine (ASIS) and the medial malleolus, and radiographically with CT scanogram to set the proper operative plan.

All cases in group I had shortening of the affected limb less than 6 cm.

Group (2): 4 cases in group II (1,18,19 and 17) had shortening of the affected limb more than 6 cm.

**Muscle wasting:** The patients were assessed for muscle wasting by measuring mid-quadriceps muscle circumference using tape technique. In group (1): 4 Patients suffered from muscle wasting, 2 Patients with 1 cm, and 2 patients with 2 cm wasting in comparison with the other side. In group (2): 5 patients suffered from muscle wasting, 3 patients with 2 cm, and 2 patients with 1 cm wasting in comparison with the other side.

**Joint range of movement:** All the patients have been examined for hip, knee, and ankle range of movement before the definitive surgery. In group (1) all patients have normal range of movement of hip, knee, and ankle joints. In Group (2) 3 patients (1,17 and 21) had limited knee range of movement.

**Radiologic evaluation:**

Proper anteroposterior and lateral radiographs of the femur were ordered to plan for site of osteotomy and distraction in addition to CT scanogram to calculate limb discrepancy and to identify mechanical and anatomical axes of the affected limb.

**Blood tests:**

Full blood count with differential leukocytic count, ESR and CRP was requested from all patients to screen for infection.

**Surgical technique**

Third generation cephalosporin was used 1 gram IV 12 hours before surgery and 1 gram at the start of the surgery. Mechanical and pharmacological DVT have been done in the form of TEDs on the non-operated calf muscles and Enoxaparin with dose adjusted according to body weight. Patients had nerve block before or immediately after the surgery to control post-operative pain. Caudal or general anesthesia was given in addition to regional block on case-by-case basis.

**Application of mono-lateral external fixator:**

Position of the first screw is of crucial importance in deciding the final position of the fixator, and it was implanted in all patients as the last screw in the proximal clamp just below the equator of lesser trochanter and perpendicular to the femoral diaphysis, perpendicular to the anatomical axis of the femoral bone. Screw insertion technique started with skin incision, blunt dissection, trocar palpation through screw guide, drilling across first cortex the diameter of the bone then second cortex and manual insertion of the screw.

Care is taken to leave 3 cm distance between the 2 clamps for doing the planned osteotomy, positioning of second screw in the most distal place in the distal clamp comes next following the same technique. Rest of screws are inserted keeping 3 screws in each clamp on either side of osteotomy, with trial to achieve optimal spread of the screws by placing it in the first, third, and fifth seats thereby increasing control over the segment of the femur. Hydroxyapatite coated screws has been used in 3 cases of group (1) and 8 cases in group (2).

All patients had the same technique regardless of the site, through a 2 cm skin and fascia lata incision, blunt dissection is carried out down to bone without elevation of periosteum, then 4.5 multiple drill passes are made across the diameter of the bone in evenly spaced directions. 10 mm osteotome is introduced through the lateral cortex to complete the cut through till the medial side, then by twisting the osteotomy 90 degrees an osteoclasia results and confirmed by twisting the 2 segments away and orthogonal intra-operative X-ray.

### **Technique of distraction:**

Latency period of 7-10 days with full weight bearing was allowed as tolerated with the aid of 2 crutches from the first post-operative day with no distraction to allow healing of surgical wounds and proliferation of cells at osteotomy site. After having a wound check in outpatient clinic, patient is taught to use a provided Allen key to distract at a rate of .25 mm every 6 hours, subsequent clinic appointment is booked with orthogonal X-ray views on arrival firstly at 2 weeks mark to ensure the segment movement then monthly. Immediately at the end of each procedure, vascular status of affected limb was checked by palpation of dorsalis pedis and posterior tibial artery pulsation. After complete recovery from anesthesia the neurological status of affected limb was checked and documented.

Pain is controlled immediately after surgery by nerve block and patient-controlled analgesia, then paracetamol is prescribed orally if needed. Instructions regarding caring of pins are given to the patient to be carried out with help of their families and supervised fortnightly in the first month then monthly. Once the planned length is reached in group (1) or the docking takes place in group (2), distraction is halted, and fixator is locked to provide stability required for consolidation of regenerate.

If no change detected on monthly follow up x-rays, bone marrow injection was given in the regenerate to enhance consolidation. This was needed in 3 cases of group (1) and 9 cases of group (2).

Bone grafting of docking site was performed in all cases of group (2) and none of the cases of group (1).

Fixator is unlocked, and full weight bearing is allowed once maturation of callus is evident clinically and on orthogonal radiographs, to increase bone thickening and eliminate stresses gradually off the fixator pins prior to removal.

Removal of fixator is planned on a day case surgery basis once the patient can fully weight bear unaided on the affected limb and bone consolidation is evident on orthogonal radiographs,

The primary outcome of this study was assessment of radiological bone union on orthogonal radiographs, and assessment of functional results using criteria of Paley et al. <sup>(8)</sup>

Complications in both groups were grouped into problems, obstacles, and sequelae, Problems represented difficulties that required no operative intervention to resolve, while obstacles represented difficulties that required an operative intervention and all problems during limb lengthening that were not resolved before the end of treatment were considered sequelae. <sup>(8)</sup> in group I, 12 problems were observed, including superficial pin-track infection (n: 9) that were treated by daily dressing and oral antibiotics in nine patients and angulation at the

regenerate site (n: 3) in three. One patient developed one obstacle, which comprised grade-III pin-track infection, led to premature pin removal.

In group II, 26 problems were encountered, comprising superficial pin-track infection (n: 14) in 10 patients, a transient knee flexion contracture (n: 2) in two patients and delayed maturation of the regenerate site (n: 10) in all patients. Besides, two patients experienced obstacles, which were a grade-III pin-track infection (n: 3) in two patients and delayed union (n: 4) at the docking site in one patient. Delayed union was managed by autogenous bone grafting; grade-III pin-track infection managed by pin removal. Moreover, five patients from group II developed sequelae, which involved a valgus deformity of  $15^\circ$  (n: 1) in one patient, varus deformity of  $10^\circ$  (n: 1) in one patient, and a knee flexion contracture of  $15^\circ$  (n: 3) in three patients. While the patient with a flexion contracture was mobilized under general anesthesia, others with sequelae denied the suggestion to correct their malalignment.

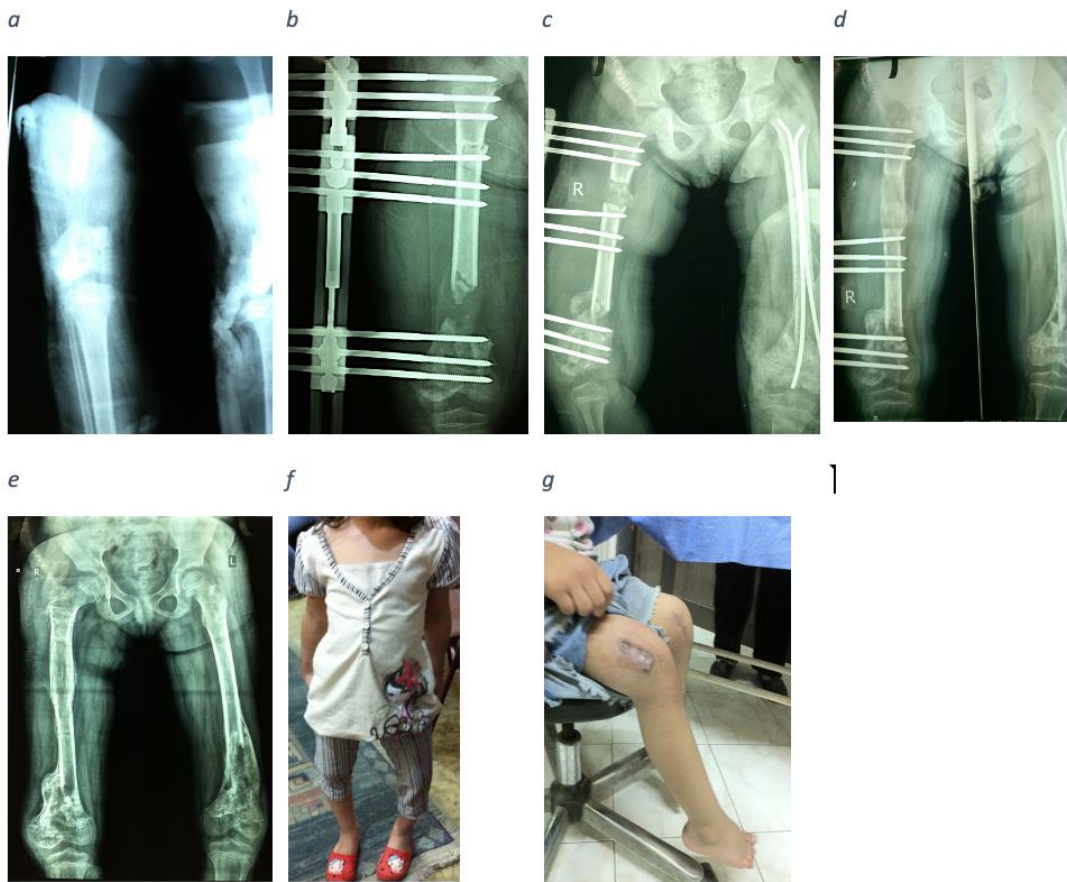


Fig. 1. Follow-up radiographs and clinical views of a 6 years old female patient, presented acutely who underwent the segment transport with LRS. The X-ray demonstrates with comminute fracture left femur associated with bone loss, with contralateral distal transverse fracture femur (a). AP and lateral X-rays illustrate osteotomy and transport (b-c-d). The final radiographs (e) and clinical image (f-g)

show the patient with full weight bearing and 90 degrees knee flexion. after the end of treatment.

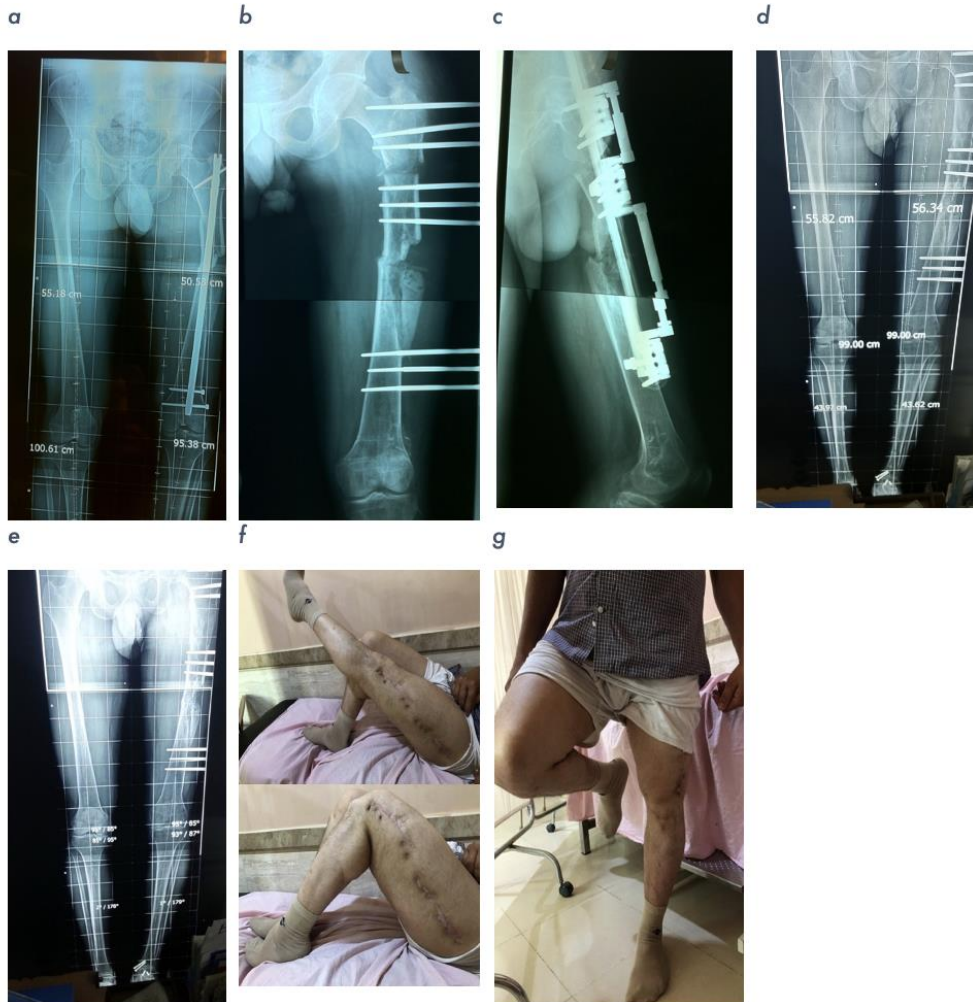

Fig. 2. Follow-up radiographs and clinical views of 46 years old male patient, sustained comminuted fracture left femur, which had been treated previously by debridement, open reduction and internal fixation using IMN, with about 5 cm shortening (A). AP and lateral X-rays illustrate removal of nail, osteotomy and application of LRS (B-C). The Final scanogram (D-G). and clinical image (f-g-h) show the patient with restored length and alignment with excellent function after the end of treatment.

## Results

The summary of the results of the study is presented in Tables 2 and 3.

Table (2) shows demographic characteristics and outcomes in acute shortening and distraction group

Case	Age	Sex	Time of presentation	DEFECT SIZE	Level of osteotomy	Time to union (EFT)	Healing index (EFI)	Distraction	Radiological results	Functional results
2	23	M	ACUTE	5 CM	Supracondylar	9 M	54	5	Excellent	full
5	37	M	ACUTE	4 CM	Supracondylar	8 M	60	4	Excellent	full
6	30	M	ACUTE	3 CM	subtrochanteric	7 M	70	3	Excellent	full
8	45	M	ACUTE	3 CM	Supracondylar	5 M	50	3	GOOD	full
9	34	M	ACUTE	5 CM	subtrochanteric	9 M	45	6	GOOD	full
10	43	M	LATE	3 CM	subtrochanteric	7 M	70	3	GOOD	full
11	26	F	LATE	4 CM	Supracondylar	8 M	60	4	GOOD	full
3	35	M	ACUTE	4 CM	Supracondylar	8 M	67,5	4	GOOD	full
4	28	M	LATE	3 CM	Supracondylar	7 M	70	3	EXCELLENT	full
7	46	M	LATE	5 CM	Supracondylar	9 M	54	5	GOOD	full
20	24	F	ACUTE	4 CM	Supracondylar	8 M	60	4	EXCELLENT	full

Table (3) Shows demographic characteristics and outcomes in bone transport group

Case	Age	Sex	Time of presentation	DEFECT SIZE	Level of osteotomy	Time to union (EFT)	Healing index (EFI)	Distraction length	Radiological results	FUNCTIONAL RESULTS
13	6	M	ACUTE	5 CM	subtrochanteric	8 M	48	5	EXCELLENT	FULL
1	42	M	LATE	7 CM	subtrochanteric	10 M	42.5	7	GOOD	GOOD
12	21	F	ACUTE	4 CM	supracondylar	7 M	52.5	4	GOOD	FULL
14	33	M	LATE	3 CM	supracondylar	7 M	70	3	EXCELLENT	FULL
15	42	F	ACUTE	4 CM	subtrochanteric	10 M	75	4	GOOD	FULL
16	33	M	LATE	3 CM	supracondylar	7 M	70	3	GOOD	FULL
17	44	M	ACUTE	13 CM	subtrochanteric	18 M	41.2	10	FAIR	GOOD
18	38	M	ACUTE	5 CM	subtrochanteric	9 M	54	5	GOOD	FULL
19	27	M	LATE	7 CM	subtrochanteric	10 M	42.8	7	GOOD	FULL
21	26	M	ACUTE	13 CM	subtrochanteric	14 M	32.3	13	FAIR	GOOD

The mean EFI was lower in group II (mean: 52.8 days/cm; range: 32.3–70) than in group I (mean 60.8 days/cm; range: 45–76.5) ( $p = 0.118$ ) (Table 4). The mean EFT was shorter in group I (mean: 7.7 months; range: 5–9 months) than in group II (mean: 10 months; range: 7–18 months) ( $p = 0.017$ ). With respect to the bone and functional results, no difference was observed in Paley scores between the groups ( $p = 0.96$  for bone and  $p = 0.18$  for functional scores). In group I, bone scores were excellent in 5 patients, good in six patients and functional scores were excellent in all 11 patients. In group II, bone scores were excellent in two patients, good in six, and fair in two. Functional scores in group II were excellent in seven patients, good in three patients. Details of the complications (according to the classification system of Paley) encountered during the treatment period are summarized in Table 4.

Table (4): Comparison between Group (I): Acute Shortening and Distraction and Group (II): Bone Transport according to complications rate. Using: Fisher's Exact Test;  $p\text{-value} > 0.05$  NS;  $*p\text{-value} < 0.05$ .

Complications		Number of patients with complications		Number of complications in all patients		Complication's rate (%)		Fisher's Exact Test
		Group I (n=11)	Group II (n=10)	Group I (n=11)	Group II (n=10)	Group I (n=11)	Group II (n=10)	p-value
Problems	Grade II pin tract infection	9	10	9	14	81%	140%	0.67
	Translation/angulation at regenerate site	0	2	0	2	0	20%	0.962
	Delayed maturation at regenerate site	3	10	3	10	27%	100%	1.000
	Transient loss of knee movement	0	0	0	0	0	0	--
	Transient loss of ankle movement	0	0	0	0	0	0	--
	Total	12	22	12	26	109%	206%	0.80
Obstacles	Grade III pin tract infection	1	2	1	4	9%	40%	0.699
	Soft tissue invagination	0	0	0	0	0	0	--
	Equinus deformity	0	0	0	0	0	0	--
	Total	1	2	1	4	9%	40%	0.068
Sequelae	Malalignment $>5^\circ$	0	2	0	2	0	20%	0.353
	Knee contracture $>5^\circ$	0	3	0	3	0	30%	0.746
	total	0	5	0	5	0	50%	0.881

Deformity analysis was carried out based on the malalignment test and malorientation test, as described by Paley and it shows mechanical axis deviation > 10 mm in three patients in group II. The number of problems per patient was higher in group B than group A (2.6 per patient in group II versus 1 per patient in group I,  $p = 0.8$ ). According to the classification system of Paley. There was no statistically significant difference between groups according to their bone results and functional results.

## **Discussion**

In the present study we assessed the management of comminuted fracture femur with bone loss by mono lateral external fixator in 21 patients who were divided into two main groups, one group was managed by acute shortening and distraction, and the other group was managed by bone transport technique. We aimed primarily to retrospectively report the outcomes of those patients regarding bone union and functional level. yields excellent to good results, and Furthermore, a comparison was made between acute shortening and distraction and segment bone transport to clarify which of the technique has statistically significant impact on improvement of radiological and functional results and reduction of incidence of complications. This study results suggested that application of mono-lateral fixator achieves good to excellent bone results and significantly improves function results, with acute shortening and distraction technique has statistically significant better bone results and less complication rate.

## **This study included**

Statistical analysis confirmed the homogeneity of all patients in both group as there were no significant differences in terms of patient age, sex, presentation time, or defect size. In this study we have done comparison between both groups concerning level of osteotomy, time to union (external fixator time), healing index (external fixator index), need for other procedures, radiological results and functional results. Complications were classified according to the classification system of Paley, then comparison between the two groups have been made in regard to complication rate, number of patients with complication and number of complications in all patients.

In group I successful bone union was achieved in all cases within an average time of 7.7 months, with 45.5% excellent bone results and 54.5% good results. In group II successful bone union was achieved in all cases within an average time of 10 months with 20% excellent results, 60% good results, 20% fair results. The increased time till union and increased mean of distraction length in group II was statistically significant when p-value was 0.017, 0.024 respectively. However, one should bear in mind that this is due to the fact that mean defect size in group II was larger than Group I implicating more time needed to union in bone transport group. Eventually healing index showed no statistically significant difference between two groups which indicates that bone transport was used effectively when larger distraction length is required, This means that in line with the hypothesis, mono-lateral external fixator successfully achieved the primary target outcome of bone results and functional results, with superiority of acute

shortening and distraction technique in the quality of bone results and shorter duration of treatment.

The study demonstrates a correlation between both longer distraction length and longer time till union and need to perform additional procedures to enhance biology required for healing such as bone grafting, and this was accompanied by higher incidence of complications such as grade II pin tract infection, which was higher in group II than in group I. Statistical analysis in this study showed that functional results was achieved fully in all acute shortening and distraction patients and in 70% of bone transport group patients with 30% had limitations to knee range of movement, with no statistically significant differences between the two groups regarding healing index, suggesting that shorter duration of treatment is linked to lower complication rate and better functional outcome.

Pin tract infection which was dealt with according to severity either by antibiotics and daily dressings around pins and crust removal or by premature pin removal. Deviation of mechanical axis of lower limb  $>5^\circ$  in two patients after removal of external fixator. Knee flexion limitation in three patients after removal of the fixator. The use of mono-lateral external fixator is an effective treatment option in managing comminuted fracture femur with bone loss with simple application, lower cost, lower incidence of complications and reflectively higher patient satisfaction. Yin et al. in 2015 systematically reviewed 24 studies and conducted meta-analysis of Ilizarov methods in the treatment of infected non-union of tibia and femur and stated that there is limited number of studies reviewed management of bone loss in comminuted fracture femur as most studies involved tibia non-union. <sup>(2)</sup>

De Bastiani, Aldegheri and Renzi Brivio, in 1984 treated 16 femora non-union with mono-lateral external fixator and reported a healing rate of 94% with minimal complications. <sup>(9)</sup> Hashmi, Ali and Saleh, in 2001 reported the results of treatment of 38 femora segmental fractures with non-union with a mono-lateral external fixator, the mean time till union was 12.6 months, the mean healing time in the bone lengthening group was 14 months, the success rate in terms of clinical and radiological healing was 90%, the mean length gained was 4.5 cm. <sup>(10)</sup> Saleh and Rees, in 1995 set out a study to compare external fixator time between bone transport and compression distraction method in the treatment of bone loss, they observed shorter treatment time and lower rate of complications in the compression distraction technique, which is in line with this study results. However, their study was heterogeneous in terms of patient's population, fixator type and inclusion of femoral and tibial cases. <sup>(11)</sup>

Iacobellis, Berizzi and Aldegheri, in 2010 reviewed results of treatment of 26 femora by bone transport comparing use of Ilizarov ring fixator and mono-lateral fixator and demonstrated the superiority of mono-lateral external fixator in aspects of easier use and less cumbersome and more easily manipulated and explained to patients. <sup>(12)</sup> Arora S et al., in 2012 reviewed records of 19 months follow up for 15 patients who underwent distraction osteogenesis to manage their femoral shaft bone loss, they reported mean bone defect of 7.9 cm with mean treatment duration 7.3 months, their stated obtaining excellent and good functional outcomes in all patients except 2 with fair outcome and 100% bone

union, they affirmed the efficacy of mono-lateral external fixator to manage these cases with less financial burden for most patient in developing countries.<sup>(13)</sup> Seenappa, Shukla and Narasimhaiah, in 2013 conducted a study on case series of 10 femora fracture with bone loss managed by mono-lateral fixator, they reported union rates of 89.2% without using bone graft and pin tract infection was eradicated in 91.66% of patients without re-activation of infection on one year follow up. In context with our study, they had better bone results than functional results, they explained it by clarifying those functional results depends primarily on soft tissues and to lesser extent on bones.<sup>(14)</sup>

Harshwal et al, in 2014 evaluated the results of managing bone loss in 7 femora and found that when bone defect is less than 5 cm, acute compression followed by callus distraction was better to obviate need for bone grafting at docking site and decreases the mean duration of treatment. In addition, they encountered pin tract infection as the most common complication (11.7%).<sup>(6)</sup> Jonathan et al., in 2015 used bone transport technique to manage bone loss in 7 femora and reported range of knee flexion between 20 to 90 with full extension could be achieved in all patients, which agrees with the results from (Krishnan, Pamecha and Patwa, 2006)<sup>(53)</sup> and our results in that mobility of the knee will be affected in this technique.<sup>(15)</sup> Agrawal et al., in 2016 evaluated the complications occurred during and after distraction osteogenesis with mono-lateral external fixator in 30 femora and had 26.67% knee mobility affection and 86.67% pin tract infection which approximately matches our results.<sup>(16)</sup> Zhang et al., in 2017 retrospectively analyzed 41 patients with segmental femoral bone loss ranged from 6 cm to 17 cm managed by mono-lateral external fixator, and reported 100% fracture healing rate, and functional rates of good/excellent were achieved by 73.2% of patients similarly to the results from this current study. They had lower incidence (56.1%) of pin tract infection compared to the present study explaining that to better patient education and more stable fixation. They stated that second common complication was knee joint stiffness, suggesting managing that by circular external fixation at a later stage.<sup>(17)</sup>

Sen C et al., in 2019 retrospectively compared acute shortening and distraction technique over intramedullary nail with bone transport concluding that adding intramedullary nail shortens the external fixator time and confers greater patient satisfaction, however they stated the possibility of deep infection spreading to the intramedullary nail from the unavoidable pin tract infection which can be a devastating problem.<sup>(18)</sup>

## **Conclusion**

In conclusion, it appears that the application of mono-lateral external fixator is an effective and reliable method to achieve satisfactory outcome in cases of comminuted fracture femur with bone loss with preference of acute compression and distraction technique to shorten the duration of treatment and limit the rate of complication.

**Funding:** “This research did not receive any specific grant from funding agencies in the public, commercial, or not-for-profit sectors.”

**Conflict of Interest:** The authors have no proprietary, financial, or other personal interest of any nature or kind in any product, service, and/or company that is presented in this article.

## References

1. S.E. Mitchell, J.F. Keating, C.M. Robinson. The treatment of open femoral fractures with bone loss. <https://doi.org/10.1302/0301-620X92B1225190> [Internet]. 2010;92-B (12):1678–84. Available from: [http:// online.boneandjoint.org.uk/ doi/10.1302/0301-620X.92B12.25190](http://online.boneandjoint.org.uk/doi/10.1302/0301-620X.92B12.25190) (2010).
2. Yin P, Ji Q, Li T, Li J, Li Z, Liu J, et al. A Systematic Review and Meta-Analysis of Ilizarov Methods in the Treatment of Infected Non-union of Tibia and Femur. 2015 Nov 3;10(11): e0141973. Available from: <https://doi.org/10.1371/journal.pone.0141973> (2015).
3. Said GZ, Farouk OA, Said HG. Two-stage surgical treatment for non-union of a shortened osteoporotic femur. *Trauma Mon* [Internet]. 2013;18(1):32–6. Available from: <http://www.ncbi.nlm.nih.gov/pubmed/24350147> (2013).
4. Agarwal A, Yogendra Raj R, Shanker M. Clinic radiological outcomes following single-stage treatment using external fixator, copious bone grafting and high dose antibiotics for infected post-osteomyelitic non-union of femoral shaft. *J Pediatr Orthop B* [Internet]. 2019; Available from: [http:// www. ncbi. nlm. nih. gov/pubmed/31821272](http://www.ncbi.nlm.nih.gov/pubmed/31821272) (2019).
5. Arora S, Batra S, Gupta, V, Goyal A. Distraction osteogenesis using a mono lateral external fixator for infected non-union of the femur with bone loss. *J Orthop Surg (Hong Kong)* [Internet]. 2012;20(2):185–90. Available from: <http://www.ncbi.nlm.nih.gov/pubmed/22933676> (2012).
6. Raj Kumar Harshwal, Sohan Singh Sankhala. Management of non-union of lower-extremity long bones using mono-lateral external fixator--report of 37 cases. *Injury* [Internet]. 2014;45(3):560–7. Available from: [https:// linkinghub. elsevier. com/ retrieve/pii/S0020138313005548](https://linkinghub.elsevier.com/retrieve/pii/S0020138313005548) (2014).
7. Sen C, Demirel M, Saglam Y, Balci H.I. Acute shortening versus bone transport for the treatment of infected femur non-unions with bone defects. *Injury* [Internet]. 2019;50(11):2075–83. Available from: <https://linkinghub.elsevier.com/retrieve/pii/S0020138319304942> (2019).
8. PALEY, D. Problems, Obstacles, and Complications of Limb Lengthening by the Ilizarov Technique. *Clin. Orthop. Relat. Res.* 250, (1990).
9. De Bastiani, G., Aldegheri, R. & Renzi Brivio, L. The treatment of fractures with a dynamic axial fixator. *J. Bone Joint Surg. Br.* 66, 538–545 (1984).
10. Lascombes, P., Popkov, D., Huber, H., Haumont, T. & Journeau, P. Classification of complications after progressive long bone lengthening: Proposal for a new classification. *Orthop. Traumatol. Surg. Res.* 98, 629–637 (2012).
11. Saleh, M. & Rees, A. Bifocal surgery for deformity and bone loss after lower-limb fractures. Comparison of bone-transport and compression-distraction methods. *J. Bone Joint Surg. Br.* 77, 429–434 (1995).
12. Sayfullaevich, P. S. (2021). Clinical and pathogenetic approaches to early rehabilitation of ischaemic stroke patients. *International Journal of Health & Medical Sciences*, 4(4), 373-380. <https://doi.org/10.21744/ijhms.v4n4.1788>

13. Iacobellis, C., Berizzi, A. & Aldegheri, R. Bone transport using the Ilizarov method: a review of complications in 100 consecutive cases. *Strateg. trauma limb Reconstr.* 5, 17–22 (2010).
14. Suryasa, I. W., Rodríguez-Gámez, M., & Koldoris, T. (2022). Post-pandemic health and its sustainability: Educational situation. *International Journal of Health Sciences*, 6(1), i-v. <https://doi.org/10.53730/ijhs.v6n1.5949>
15. S, A., S, B., V, G. & A, G. Distraction osteogenesis using a monolateral external fixator for infected non-union of the femur with bone loss. *J. Orthop. Surg. (Hong Kong)* 20, 185–90 (2012).
16. Seenappa, H. K., Shukla, M. K. & Narasimhaiah, M. Management of complex long bone nonunions using limb reconstruction system. *Indian J. Orthop.* 47, 602–607 (2013).
17. Wright, J., Bates, P., Heidari, N. & Vris, A. All internal bone transport: Use of a lengthening nail and double plating for management of femoral bone loss. *Strateg. Trauma Limb Reconstr.* 14, 94–101 (2019).
18. Agrawal, H. K. et al. Management of complex femoral nonunion with monorail external fixator: A prospective study. *J. Clin. Orthop. trauma* 7, 191–200 (2016).
19. Zhang, Q. et al. Femoral nonunion with segmental bone defect treated by distraction osteogenesis with monolateral external fixation. *J. Orthop. Surg. Res.* 12, 183 (2017).
20. C, S. et al. Acute shortening versus bone transport for the treatment of infected femur non-unions with bone defects. *Injury* 50, 2075–2083 (2019).