

How to Cite:

Sultan, S. R., & Al-Mola, E. D. H. (2022). Laboratory techniques for diagnosing Giardia parasite in dogs in Mosul City, Iraq. *International Journal of Health Sciences*, 6(S3), 10467–10473. <https://doi.org/10.53730/ijhs.v6nS3.9495>

Laboratory techniques for diagnosing Giardia parasite in dogs in Mosul City, Iraq

Saif Rafea Sultan

Department of Internal and Preventative Medicine, College of Veterinary Medicine, University of Mosul, Mosul, Iraq

Eman Daham Hadi Al-Mola

Department of Internal and Preventative Medicine, College of Veterinary Medicine, University of Mosul, Mosul, Iraq

Abstract--The results of the current study showed that the different techniques of microscopic examination recorded the highest rate of infection and diagnosis of Giardia in dogs with significant differences at the level of probability $p < 0.05$ It reached 73.4%, followed by the rapid test technique and indirect enzyme linked immunosorbent assay (ELISA) with a rate of 14.2% and 12.2% respectively. With regard to determining the sensitivity and specificity of the rapid test and microscopic examination, a sensitivity of 19% and a specificity of 100% were recorded. The results, using the indirect ELISA showed an infection rate of 12.2% of the total samples. The results showed that the number of positive samples with this technique amounted to 12 samples positive for Giardia lamblia out of the total samples positive for microscopic examination. To confirm the diagnosis of giardiasis, the results using the direct immunofluorescence technique using acridine orange fluorochrome showed the appearance of a glowing brilliance, as the cysts appeared oval green glowing and the trophozoites appeared glowing green pear.

Keywords---laboratory, diagnosing, parasite.

Introduction

Giardia is known as beaver fever or Giardiasis in dogs. It is also called Giardia lamblia. And it is also known as Giardia intestinalis and Giardia duodenalis (Rajurkar *et al.*, 2012; Decock *et al.*, 2003). They colonize and reproduce in the small intestine of many mammals, amphibians, birds, and reptiles. (Ali and Israa, 2017) . In diagnosing giardiasis many techniques were adopted including microscopic techniques for rapid detection of cysts and trophozoites (Rajurkar *et al.*, 2012). Several microscopic techniques were used to study the morphological

characteristics of Giardia by using centrifugal concentration-deposition and flotation technique with zinc sulfate has a better sensitivity than the flotation method (Hassan,2021). Relying on microscopic techniques does not meet the sufficient need to detect cysts and trophozoites, so recent studies have tended to use modern and advanced techniques with high sensitivity and specificity, in addition to microscopy technology, including the rapid test technique, which is easy to perform and can increase the efficiency of the laboratory by reducing time and cost (Simeonidou *et al.*,2020) ,While other studies for the detection of cysts and trophozoites relied on the use of the direct ELISA (Rahman *et al.*,2014) . (Uiternijk *et al.*, 2018) was able to use of an enzyme-linked immunosorbent assay technique for the detection of Giardia antigen in dog feces. In addition to molecular techniques (PCR) to discover and identify the genetic patterns and types of Giardia.

Materials and Methods

The study was conducted on 98 dogs of different ages from one month and above, of both sexes. It was selected from different areas on both sides of Mosul city for the period from October 2021 until April 2022. Stool samples were collected from dogs and placed in plastic containers with a capacity of 50 milliliters and were immersed in 10% formalin solution to preserve the cysts and trophozoites of the Giardia parasite from decomposition and kept in the refrigerator at 4 C° For the purpose of conducting microscopic examinations, including direct technique, flotation technique and concentration-deposition and flotation technique with zinc sulfate. Rectal swabs were also collected using sterile cotton swabs and placed in tubes containing the dilution solution of the rapid test for the purpose of conducting the rapid test. Stool samples were also used to make smears for the purpose of conducting the direct immunofluorescence technique. Blood samples were collected from the cephalic vein after shaving the area and sterilizing it with ethyl alcohol, the blood was placed in gel tubes for the purpose of separating the blood serum to be used with the indirect ELISA technique.

Results

The results showed through the use of different techniques, that dogs were infected with cysts and trophozoites . Table (1) indicates that there are significant differences at the level of probability $p < 0.05$ to determine the rate of infection with Giardia parasite using different laboratory techniques. It was clear from the results that the different techniques of microscopic examination recorded the highest rate of infection and diagnosis of cysts and trophozoites of the Giardia, which amounted to 73.4%, while the lowest rate of infection with the indirect ELISA and the rapid test was 12.2%, 14.2%, respectively.

Table 1
The rate of infection in dogs using different techniques of of the total samples

Number of samples examined	Tech type	Number of positive samples	%
98	Microscopic techniques	72 a	73.4

	Indirect ELISA	12 b	12.2
	Rapid test	14 b	14.2

Table (2) indicates that there are significant differences in the rate of infection with *Giardia* parasite using laboratory techniques for microscopic examination. It was clear from the results that the concentration-deposition and flotation technique with zinc sulfate recorded the highest infection rate of 44.5%, followed by the flotation technique–Sodium chloride and flotation technique – sugar solution with a percentage of 19.4% and 25%, respectively, while the lowest percentage of infection with direct swab technique was 11.1% .

Table 2
The rate of infection with *Giardia* parasite using laboratory microscopic techniques for positive samples

No	Technique/Microscopy	The number of positive samples	%
1	Direct method	8	11.1 a
2	Concentration-deposition and flotation technique with zinc sulfate	32	44.5 b
3	Flotation technique – sugar solution	18	25 a
4	Flotation technique – Sodium chloride	14	19.4 a
	Total	72	

The results, using the indirect ELISA test, showed a diagnosis rate of 12.2%. Of the total samples, the number of positive samples with this technique was 12 samples of the type *Giardia lamblia* from the total positive samples by microscopic examination, Figure (1).

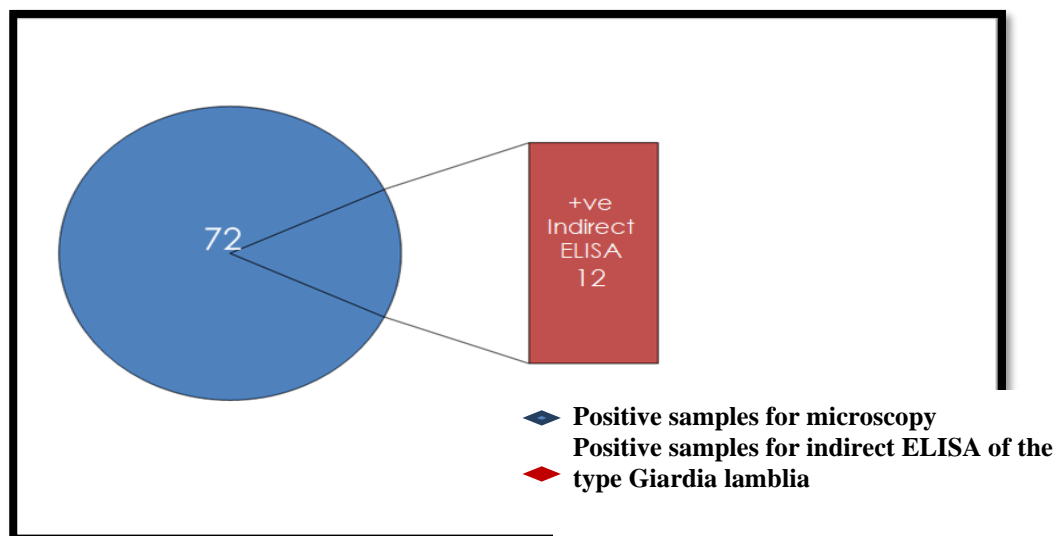


Figure 1. Shows the number of samples positive for the indirect ELISA test for *G. lamblia* from the total positive samples by microscopy. The results showed with regard to determining the sensitivity and specificity of the microscopic examination and the rapid test of dogs infected with *Giardia* parasite, where the sensitivity of the rapid test reached 19%, while the specificity of the rapid test reached 100%, Table (3).

		Microscopy		
		Infected	Uninfected	Total number
Rapid test	Infected	14	*0	14
	Uninfected	**58	26	84
	Total number	72	26	98

* False positive, which means it is positive in the microscopy test and negative in the rapid test.

** False negative, which means negative in a microscopy test and positive in a rapid test.

The results, by using the direct immunofluorescence technique to diagnose *Giardia*, showed glowing fluorescence, oval green cysts and glowing green pear-shaped trophozoites, Images (1,2,3,4).




Image 1. shows *Giardia* cyst using acridine orange fluorochrome, fluorescent microscope, 1000 X

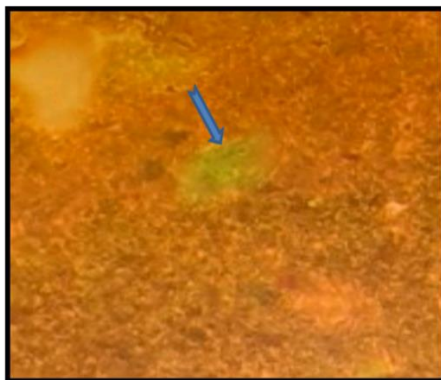


Image 2. Shows Giardia trophozoite using acridine orange fluorochrome, fluorescent microscope, 1000 X

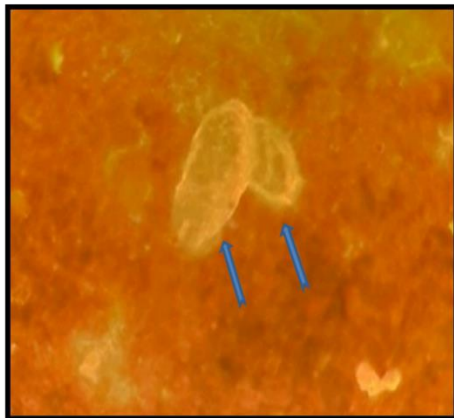


Image 3. Shows Giardia mature cysts using acridine orange fluorochrome, fluorescent microscope, 1000 X

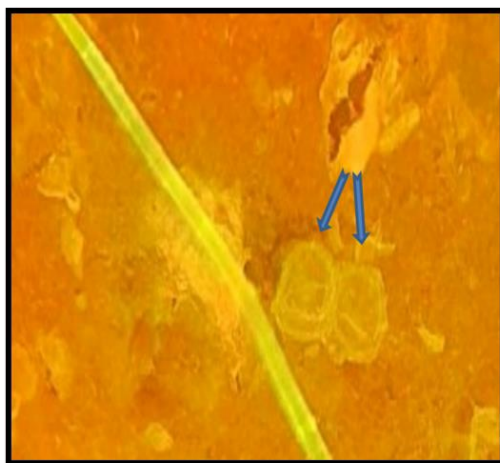


Image 4. Shows Giardia cysts using acridine orange fluorochrome, fluorescent microscope, 1000 X

Discussion

The results of the examination of different laboratory techniques for microscopy showed that the concentration-deposition and flotation technique with zinc sulfate showed the highest diagnosis rate for Giardia cysts and trophozoites, which amounted to 44.4%, and this technique was adopted as a gold standard for other techniques, including direct wet technique and flotation technique–Sodium chloride and flotation technique –sucrose. The results of the study also agreed with what was reported by (Hassan,2021) as he was able to diagnose the cysts and trophozoites of the Giardia by centrifugal–sedimentation and flotation technique. The reason is that the direct wet technique and flotation technique–Sodium chloride and sucrose flotation technique give false negative results due to the collapse of the parasite cysts and trophozoites by flotation and shrinkage and

also decomposition by flotation with sodium chloride, while the concentration-deposition and flotation technique with zinc sulfate is more sensitive because it maintains the survival of parasite cysts and trophozoites for a long time. In the current study, it was based on fixing fecal samples with 10% formalin solution.

The results of the current study agreed with what was reported (Uchôa *et al.*,2017) They confirmed that the use of formalin 10% works to preserve cysts and trophozoites of Giardia and provides protection for its effectiveness against microbes. (Hooshyar *et al.*,2019) confirmed that failure to fix fecal samples with preservative solutions such as formalin leads to the dissolution of cysts and trophozoites of the Giardia parasite. The results of the current study using the indirect ELISA showed a diagnosis rate of Giardia parasite amounted to 12.2%, while the number of positive samples using the indirect ELISA test reached 12 samples of the type of Giardia lamblia out of the total positive samples by microscopic examination. And it turned out that the parasite diagnosed with this technique and study is close to the type of Giardia lamblia, which is the most common and found in dogs. The results of the current study are in agreement with the findings of (Olson *et al.*, 2010) They confirmed that the ELISA technique recorded a diagnosis rate of the giardia parasite amounting to 13.0% in dogs and 4.1% in cats, which is a percentage close to what the results of the current study found. (Alves and Santos,2016) Showed through a comparative study between the zinc sulfate flotation centrifugation technique and the ELISA test, the diagnostic rate was 10.2% and 12.2%, respectively.

It was found through the current results that the rapid immune test technique (Rapid test) recorded a diagnosis rate of the Giardia parasite amounted to 14.2%. The results of the current study agreed with what was reported by (Alharbi *et al.*,2020;Symeonidou *et al.*,2020) They confirmed that the rapid test technique is easy to perform to detect Giardia infection and increases the efficiency of laboratory diagnostic techniques in addition to reducing time. The results of the current study to determine the sensitivity and specificity of the rapid test and microscopic examination of dogs infected with Giardia parasite showed a sensitivity rate of 19% and a specificity of 100%. The results of the current study did not agree with what was reached by (Symeonidou *et al.*,2020) They confirmed that the results of the microscopic examination and the rapid test gave a sensitivity rate of 58.6% and 86.2, respectively, and a specificity of 100%. The reason for the difference may be due to the intermittent shedding of cysts from infected dogs ranging from one to three days, so the examination of samples must be repeated at least three times. To evaluate and confirm the diagnostic tests used to diagnose the Giardia parasite in this study, the Giardia parasite was detected by direct immunofluorescence technique or the so-called immunofluorescence. The results of the current study are in agreement with other studies (Rahman *et al.*,2014; Barbecho *et al.*,2018; Saleh *et al.*,2019) They emphasized that the immunofluorescence technique is considered a cheap alternative to a group of enzyme linked immunosorbent assay techniques, in addition to being a quick technique and giving positive results compared to other techniques.

References

1. Decock, C., Cadiergues, M. C., Larcher, M., Vermot, S., and Franc, M. (2003). Comparison of two techniques for diagnosis of giardiasis in dogs. *Parasite*, 10(1), 69-72.
2. Rajurkar, M. N., Lall, N., Basak, S., and Mallick, S. K. (2012). A simple method for demonstrating the *Giardia lamblia* trophozoite. *Journal of Clinical and Diagnostic Research: JCDR*, 6(9), 1492.
3. Ali, N., and Israa, A.W., 2017. Detection of *Giardia* infection in dogs of Basrah city., Basrah. *Journal .Veterinary. Research*,16(2):159-171.
4. Hassan, Z. I. (2021). Prevalence and Molecular Identification of Giardiasis Isolates from Stray Dogs in Erbil Province, Kurdistan Region, Iraq. *Polytechnic Journal*, 11(1), 7-12.
5. Symeonidou, I., Gelasakis, A. I., Miliotou, A. N., Angelou, A., Arsenopoulos, K. V., Loukeri, S., and Papadopoulos, E. (2020). Rapid on-site diagnosis of canine giardiasis: time versus performance. *Parasites and Vectors*, 13(1), 1-10.
6. Rahman, M. M., Hossain, M. A., Paul, S. K., Ahmed, S., Islam, A., Ehsan, M. A., and Sarkar, S. R. (2014). Detection of *Giardia lamblia* and *Cryptosporidium parvum* by direct immunofluorescence assay in stool specimen. *Mymensingh Medical Journal: MMJ*, 23(3), 426-429.
7. Uiterwijk, M., Nijse, R., Kooyman, F. N., Wagenaar, J. A., Mughini-Gras, L., Koop, G., and Ploeger, H. W. (2018). Comparing four diagnostic tests for *Giardia duodenalis* in dogs using latent class analysis. *Parasites and Vectors*, 11(1), 1-8.
8. Uchôa, F. F. D. M., Sudré, A. P., Macieira, D. D. B., and Almosny, N. R. P. (2017). The influence of serial fecal sampling on the diagnosis of giardiasis in humans, dogs, and cats. *Revista do Instituto de Medicina Tropical de São Paulo*, 59.
9. Hooshyar, H., Rostamkhani, P., Arbabi, M., and Delavari, M. (2019). *Giardia lamblia* infection: review of current diagnostic strategies. *Gastroenterology and Hepatology from Bed to Bench*, 12(1), 3.
10. Olson, M. E., Leonard, N. J., and Strout, J. (2010). Prevalence and diagnosis of *Giardia* infection in dogs and cats using a fecal antigen test and fecal smear. *The Canadian Veterinary Journal*, 51(6), 640.
11. Alves, J., and Santos, A. (2016). Prevalence of *Giardia* spp. in young dogs using a combination of two diagnostic methods. *Acta Parasitologica*, 61(2), 261-266.
12. Alharbi, A., Toulah, F. H., Wakid, M. H., Azhar, E., Farraj, S., and Mirza, A. A. (2020). Detection of *Giardia lamblia* by microscopic examination, rapid chromatographic immunoassay test, and molecular technique. *Cureus*, 12(9).
13. Barbecho, J. M., Bowman, D. D., and Liotta, J. L. (2018). Comparative performance of reference laboratory tests and in-clinic tests for *Giardia* in canine feces. *Parasites & vectors*, 11(1), 1-4.
14. Saleh, M. N., Heptinstall, J. R., Johnson, E. M., Ballweber, L. R., Lindsay, D. S., Werre, S., and Zajac, A. M. (2019). Comparison of diagnostic techniques for detection of *Giardia duodenalis* in dogs and cats. *Journal of Veterinary Internal Medicine*, 33(3), 1272-1277.