

How to Cite:

Qaragholi, Z. M., Abu-Raghif, A. R., & Kadhim, E. J. (2022). Anti-aging herbs for skin: Experimental study on mice. *International Journal of Health Sciences*, 6(S3), 12457–12465. <https://doi.org/10.53730/ijhs.v6nS3.9506>

Anti-aging herbs for skin: Experimental study on mice

Zena M. Qaragholi

Lecturer-Department of pharmacognosy and medicinal plants-College of pharmacy- University of Baghdad

*Corresponding author email: zenaqaragholi@yahoo.com

Ahmed Rahmah Abu-Raghif

Prof. Department of pharmacology- College of medicine- University of Nahrain

Enas Jawad Kadhim

Prof. Department of pharmacognosy and medicinal plants-College of pharmacy- University of Baghdad

Abstract---Herbal remedy has been used for beauty and health purposes in the traditional and modern medicine. The range of using herbs has been escalating in the past few years. However, there are not enough scientific based evidence in this aspect, as herbs contain a wide range of phytochemicals that has to be studied in meticulous details to understand its effect on the body. In this study, three plants were chosen from the local Iraqi market and extracted, then a pharmacological study was conducted on mice. Histopathological changes were studied on all the study groups. It was concluded that the three herbal aqueous extracts of (*APIUM GRAVEOLENS*, *CARTHAMUS TINCTORIOS* AND *PUNICA GRANATUM*) gave an antiaging effect and was able to reverse aging induced by D-Galactose. *PUNICA GRANATUM* (Pomegranate) gave the best result in reversing aging signs on mouse skin.

Keywords---aging, *apium graveolens*, *carthamus tinctorios* and *punica granatum*.

Introduction

Aging refers to arrest of a single cell division in an organism. In humans, it is the accumulation of a series of changes in the skin, muscles, brain and other organs over time. Everyone is made up of cells, thirteen trillion of which are cells. Each of the human organ is a collection of cell unit made up of various natural materials made by cells. From the time of conceiving, of the cells, and thus the tissues and

body parts, also start the aging procedure. Of course, we are still growing early in life, increasing the cells number that people have. Cells age, but unfortunately, they are not visible to the human eye only the body grow and develop. (Afzal et al., 2015). Celery (*Apium graveolens* L) is a plant of the Umbelliferon family and is one of the annual or perennial plant life that grow within the tropical and subtropical areas of Europe, Africa and Asia. (Liu, 1999). The parts used in this plant consist of seeds, leaves and critical oils. a number of the celery phytochemicals, phenols consisting of carbohydrates, flavonoids, alkaloids and steroids can be stated. (Dolati et al., 2018).

The presence of compounds which includes limonene, serine, floc Marin glycosides, flavonoids, vitamins A and C is why celery is the maximum broadly used plant in traditional remedy. (Chonpathompikunlert et al., 2018). Celery can control cardiovascular disease, jaundice, liver and deposits, urinary tract obstruction, gout and rheumatic sicknesses. Research on rats have shown that ethanol extracts from celery leaves growth spermatogenesis and enhance their transport. Celery can decrease glucose, blood lipids, blood stress and reinforce the heart. Research studies have proven that *Apium* is antifungal and anti-inflammatory (Zhang et al., 2016). Safflower (*CARTHAMUS TINCTORIOSUS*) or fake saffron, *Carthamus inctorius* L. belongs to the Asteraceae or Asteraceae circle of relatives. This thistle-like species normally breeds in dry climates: South Asia, China, India, Iran and Egypt. Six species can be visible in Iran. It became brought in Western international locations consisting of Italy, France, Spain and the U.S in the fifth and 14th centuries.

(Kooti et al., 2014). Concerning the phytochemistry of this plant, studies has recognized many active components recognized from exclusive elements of the plant, which includes flavonoids, phenylethanoid glycosides, coumarins, fatty acids, and steroids. (Zeng et al., 2020) Safflower has been cautioned to be powerful towards different disorders affecting the neurotrophic, cardiac orientation, hematopoietic and sweating systems (Kodeeswaran et al., 2010) (Delshad et al., 2018). *Pomegranate (PUNICA GRANATUM)* Oxidized strains (OS) produce toxic metabolites that can explain and sell most cancers. Ingestion of polyphenols and flavonoids is beneficial in preventing cardiovascular, inflammation, and various diseases by stopping OS, which induces lipid peroxidation of arterial macrophages and 4,444 lipoproteins (Jafari et al., 2006) (Fadavi, A. (2005).

Materials and Methods

Experimental animals

Wistar mice weighing 250-300g in the age of twelve weeks were used and kept at 25 ± 3 ° C. under standard ambient conditions (12 hours / 12 hours light and dark). They were given standard rat pellets and water. (Fui et al., 2015).. Standard laboratory conditions of 22 ° C \pm 3 ° C ambient temperature, 50% humidity.

Induction of aging

0.3 μmL of galactose (500 μmg / kg) is subcutaneously injected once daily for 8 weeks to induce aging in mouse models and observe signs of aging in negative and positive control and treatment groups. There is evidence that mitochondrial dysfunction and oxidative stress play important roles in aging. Administration of Dgalactose has been reported to cause cognitive and motor loss similar to the symptoms of aging and is therefore considered to be a model for accelerated aging (Floegel et al., 2011). Elevated D-galactose levels form reactive oxygen species, reduce antioxidant enzyme activity in the brain, and cause cognitive dysfunction, brain aging, decreased motor function, shortened lifespan, and natural rodents.

Plant extraction

The three plants (*Apium graveolens*, *Carthamus tinctorious* and *Punica granatum*) were collected at a local market in Baghdad, washed with tap water, air-dried in the shade, ground and extracted with water. Maceration technique was used using a shaking incubator Si-600R. The air dried herbs were grinded using a mechanical grinder then mixed with water then the water solution was incubated for two days. After that, the extract was purified with a whatman paper. The solvent was dried using a spray dryer Bochi Mrs B-200 (table 1) as sprayed as a liquid fine mist into a hot-air chamber then falls to the bottom as a dry powder, it was used instead of the rotary evaporator as the period of heating is very brief to avoid the nutritional and phytochemical damage (Finetti, 2011).

Table 1
Conditions for the Spray drying

Dried material	T1 °C	T2 °C	m1 Kg/h	m0 Kg/h	mp g/h	$\Delta h/\Delta Y$ kJ/kg	m1/m0
Pomegranate extract	150	65	260	5.28	350	7450	52
Celery	146	54	264	4.20	374	8250	55
Safflower	156	66	266	4.80	260	8100	58

The abbreviations mean the following:

T1: The temperature of the air entering the spray dryer

T2: The temperature of the air leaving the spray dryer

m1: The mass flow of the air used for drying

m0: The mass flow of the solution fed into the spray dryer

mp: The mass flow of the dry powder leaving the spray dryer

$\Delta h/\Delta Y$: The specific drying air consumption for the inlet solution

Vortex Assisted DLLME Process

The three herbal aqueous extracts were injected into a 10 mL conical centrifuge tube (pH 5.1). The tube was shaken for 60 s with a vortex mixer. A cloudy, turbid

solution was rapidly obtained in the tube. Then the tube was centrifuged for 5 min at 3800 rpm. The upper aqueous phase was removed and the residual was placed in a new centrifuge tube using a micro-syringe and evaporated to dryness under a stream of nitrogen at 45 °C. Finally, 5 μ L was injected into the HPLC and GC-MS system for analysis . The remaining powder of the three samples was stored in closed in plastic containers in a drying chamber at 60°C, to prevent proliferation of fungus, until later pharmacological studies. (Rui Zhang et al., 2019).



Figure 1. Vortex used in the research

Pharmacological study

50 mice were randomly divided into 5 groups (10 mice in each group). Except for the control group, which was injected subcutaneously with 0.3 μ l saline, the other groups were injected with the same amount of D-galactose (500 μ g / kg) once daily for 8 weeks. Treatment was orally administered for 6 weeks as follows (Fernando and Soysa 2015):

- **Group 1:** (Healthy control): Normal saline was orally administered once daily for 6 weeks. In the remaining 60 rats, aging was induced and divided.
- **Group 2:** (negative control): Age-inducing group, normal saline was orally administered once daily for 6 weeks.
- **Group 5:** Mice were intragastrical administered pomegranate at a dose of 800 mg / kg for 6 weeks.
- **Group 6:** Mice were intragastrical administered of celery extract at a dose of 3.0 g / kg for 6 weeks.
- **Group :** Mice were intragastrical administered safflower at a dose of 200 mg / kg for 6 weeks. To obtain tissue samples, animals were euthanized by anaesthesia with diethyl ether. For histopathological evaluation, parts of the brain, kidneys, and skin were removed and embedded in paraffin.

Histopathological examination

Brain, skin and kidney tissues were compared with positive controls for aging and different treatments with polyhedral preparations. The evaluation was done by comparing the treatment group with the positive and negative groups. In short, the histopathological slide turned into detached and dealt with methanol containing three% hydrogen peroxide to block endogenous peroxidase. Histopathological assessment changed into measured by using microscopic exam. The slides had been captured and displayed the use of an Olympus BX51 microscope and a software DP controller. (Embuskado, 2015).

Results and Discussion

Histopathology results

Histopathology exam of rodent skin was analysed for the seven groups (Collins et al., 2006). The most prominent epidermal changes found in the aging induced group with D- Galactose (negative control) that was administrated with normal saline daily for 6 weeks: Are flattening of the dermal-epidermal junction, that gave us a flattened appearance and atrophy. The Langerhans cells decrease in number. The most important dermal changes are the reduction in the number and diameter of elastic fibers in the papillary dermis, and increase in number and thickness of the same fibers in the reticular dermis, and an increase in density of the collagen network. In the treated group we can notice most features were almost back to normal. The group treated with Pomegranate gave the best results, this comes along with its antioxidant activity in defeating free radicals (Jafari et al., 2006). As shown in figure 2-6.

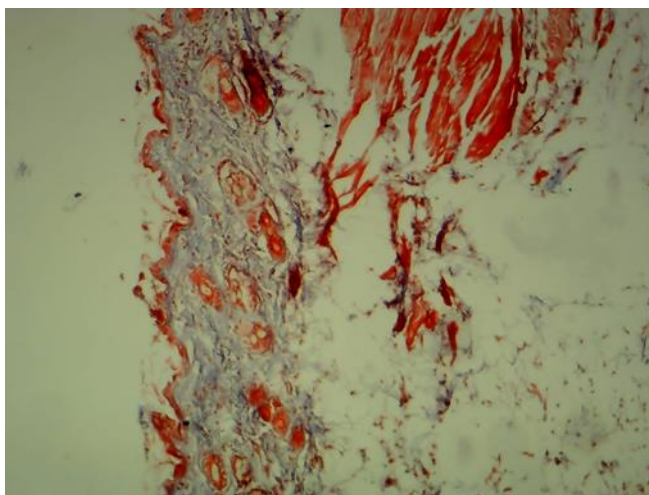


Figure 2. Normal skin (group 1)

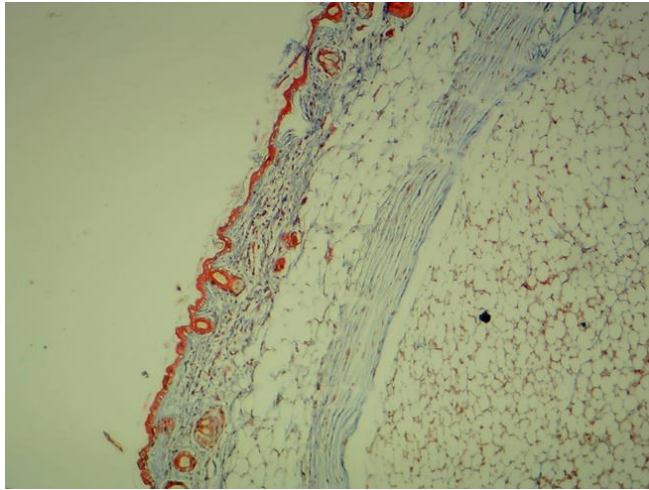


Figure 3. Aging skin induced with D- Galactose with no treatment

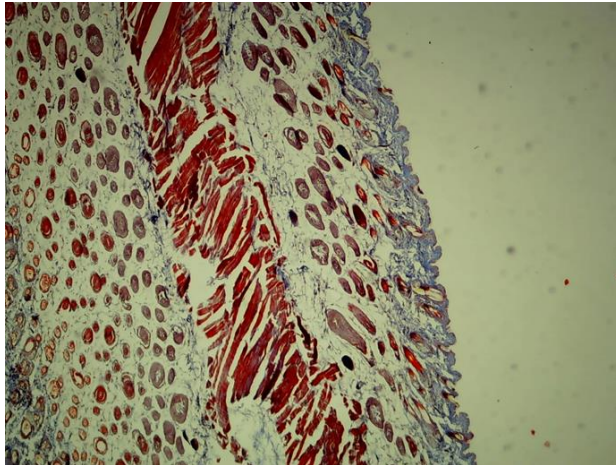


Figure 4. Histopathology of the group treated with pomegranate

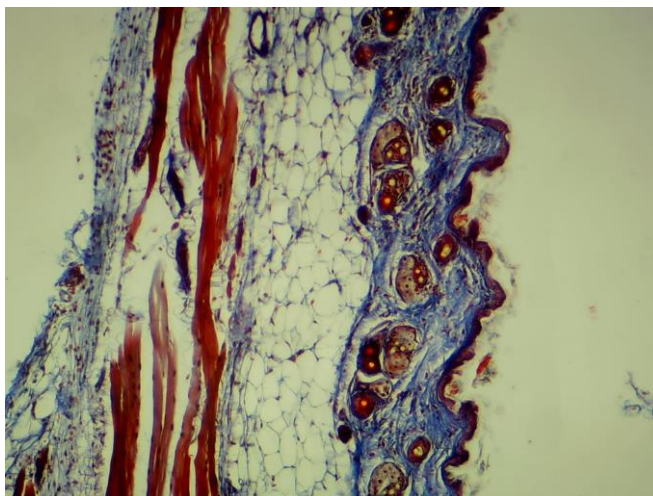


Figure 5. Histopathology of the group treated with celery

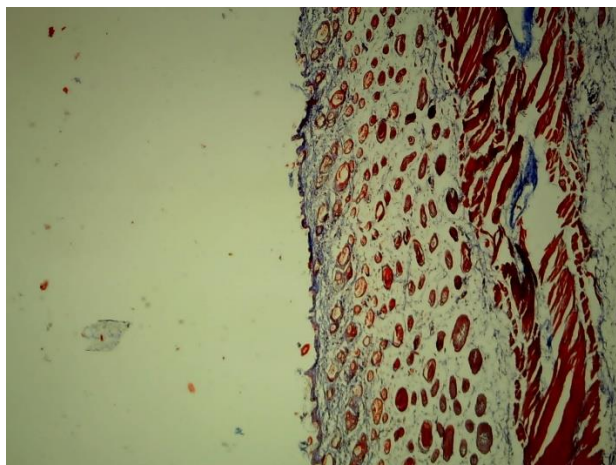


Figure 6. Histopathology of the group treated with pomegranate

Conclusion

It can be concluded that the three herbal aqueous extracts of (*APIUM GRAVEOLENS*, *CARTHAMUS TINCTORIOUS* AND *PUNICA GRANATUM*) gave an antiaging effect and was able to reverse aging induced by D- Galactose. *PUNICA GRANATUM* (Pomegranate) gave the best result in reversing aging signs on mouse skin.

References

Afzal, K., Uzair, Muhammad., Chaudhary, B. A., Ahmad, A., Afzal, S. A. M. I. N. A. and Saadullah, M. (2015). Genus *Ruellia*: Pharmacological and phytochemical importance in ethnopharmacology. *Acta Poloniae Pharmaceutica-Drug Research*, 72(5), 821-7.

- Liu^{1,4}, Qingxia Wei^{2,5}, Junjun She², Huaixing Cang^{1*} and Rui Xue Zhang Dose Effects of Orally Administered Spirulina Suspension on Colonic Microbiota in Healthy Mice. *Front. Cell. Infect. Microbiol.*, 05 July 2019
- Zhang, L. L., Tian, K., Tang, Z. H., Chen, X. J., Bian, Z. X., Wang, Y. T., & Lu, J. J. (2016). Phytochemistry and Pharmacology of *Carthamus tinctorius* L. *The American journal of Chinese medicine*, 44(02), 197-226.
- Delshad, E., Yousefi, M., Sasannezhad, P., Rakhshandeh, H., & Ayati, Z. (2018). Medical uses of *Carthamus tinctorius* L.(Safflower): a comprehensive review from traditional medicine to modern medicine. *Electronic physician*, 10(4), 6672.
- Chonpathompikunlert, P., Boonruamkaew, P., Sukketsiri, W., Hutamekalin, P., & Sroyraya, M. (2018). The antioxidant and neurochemical activity of *Apium graveolens* L. and its ameliorative effect on MPTP-induced Parkinson-like symptoms in mice. *BMC Complementary and Alternative Medicine*, 18(1), 1-12.
- Kooti, W., Mansori, E., Ghasemiboroon, M., Harizi, M., & Amirzarga, A. (2014). Protective effects of celery (*Apium Graveolens*) on testis and cauda epididymal spermatozoa in rat. *International Journal of Reproductive BioMedicine*, 12(5), 365-0.
- Kooti, W., Mansouri, E., Ghasemiboroon, M., Harizi, M., Ashtary-Larky, D., & Afrisham, R. (2014). The Effects of hydroalcoholic extract of *apium graveolens* leaf on the number of sexual cells and testicular structure in rat. *Jundishapur journal of natural pharmaceutical products*, 9(4).
- Zeng, X., Guo, F., & Ouyang, D. (2020). A review of the pharmacology and toxicology of aucubin. *Fitoterapia*, 140, 104443.
- Dolati, K., Rakhshandeh, H., Golestani, M., Forouzanfar, F., Sadeghnia, R., & Sadeghnia, H. R. (2018). Inhibitory effects of *Apium graveolens* on xanthine oxidase activity and serum uric acid levels in hyperuricemic mice. *Preventive Nutrition and Food Science*, 23(2), 127.
- Kodeeswaran Parameshwaran,¹ Michael H. Irwin,¹ Kosta Steliou,² and Carl A. Pinkert. D-Galactose Effectiveness in Modeling Aging and Therapeutic Antioxidant Treatment in Mice. 2010 Dec; 13(6): 729–735.
- Jafari, M., & Rose, M. R. (2006). Rules for the use of model organisms in antiaging pharmacology. *Aging cell*, 5(1), 17-22.
- Jafari, M., Long, A. D., Mueller, L. D., & Rose, M. R. (2006). The pharmacology of ageing in *Drosophila*. *Current Drug Targets*, 7(11), 1479-1483.
- Floegel, A., Kim, D. O., Chung, S. J., Koo, S. I., & Chun, O. K. (2011). Comparison of ABTS/DPPH Assays to Measure Antioxidant Capacity in Popular Antioxidant-Rich US Foods. *Journal of Food Composition and Analysis*, 24(7), 1043–1048.
- Finetti, C. (2011). Traditional Knowledge and the Patent System: Two Worlds Apart?. *World Patent Information*, 33 (1), 58–66.
- Rui Zhang,Zhen-Chao Tan, Ke-Cheng Huang, Yan Wen, Xiang-Ying Li, Jun-Long Zhao,and Cheng-Lan Liu (2019). A Vortex-Assisted Dispersive Liquid-Liquid Microextraction Followed by UPLC-MS/MS for Simultaneous Determination of Pesticides and Aflatoxins in Herbal TeaMolecules. 2019 Mar; 24(6): 1029.
- Fernando, C. D., & Soysa, P. (2015). Extraction Kinetics of phytochemicals and antioxidant activity during black tea (*Camellia sinensis* L.) brewing. *Nutr J*. 2015 Jul 31;14:74

- Fadavi, A. (2005). Physicochemical composition of ten pomegranate cultivars (*Punica granatum* L.) grown in Iran. *Revista de Agaroquimicay Tecnologia de Alimentos*, 11(2): p. 113-119.
- Embuscado, M. E. (2015). Spices and Herbs: Natural Sources of Antioxidants – A Mini Review. *Journal of Functional Foods*, 18, 811–819.
- Collins, J. J., Evason, K., & Kornfeld, K. (2006). Pharmacology of delayed aging and extended lifespan of *Caenorhabditis elegans*. *Experimental gerontology*, 41(10), 1032-1039.
- Suryasa, I. W., Rodríguez-Gámez, M., & Koldoris, T. (2022). Post-pandemic health and its sustainability: Educational situation. *International Journal of Health Sciences*, 6(1), i-v. <https://doi.org/10.53730/ijhs.v6n1.5949>
- Suryasa, I.W., Sudipa, I.N., Puspani, I.A.M., Netra, I.M. (2019). Translation procedure of happy emotion of english into indonesian in kṛṣṇa text. *Journal of Language Teaching and Research*, 10(4), 738–746
- Gandamay, I. B. M., Antari, N. W. S., & Strisanti, I. A. S. (2022). The level of community compliance in implementing health protocols to prevent the spread of COVID-19. *International Journal of Health & Medical Sciences*, 5(2), 177-182. <https://doi.org/10.21744/ijhms.v5n2.1897>