

**How to Cite:**

Pooja, M., Sunil, P., Sabita, P., & Seshdev, P. (2022). Multidetector computed tomography (MDCT): Evaluation of anatomical variations of nose and paranasal sinuses in chronic rhinosinusitis. *International Journal of Health Sciences*, 6(S5), 3612–3621. <https://doi.org/10.53730/ijhs.v6nS5.9564>

## **Multidetector computed tomography (MDCT): Evaluation of anatomical variations of nose and paranasal sinuses in chronic rhinosinusitis**

**Misra Pooja**

Associate Professor, Department of Radiodiagnosis, Shriram Chandra Medical College, Cuttack

**Pradhan Sunil**

Senior Residents, Department of Radiodiagnosis, PRM, MCH, Baripadda, Mayurbhanj, Odisha

**Palai Sabita**

Associate Professor, Transfusion Medicine, Maharaja Krushna Chandra Gajapati Medical College, Berhampur

**Panigrahi Seshdev\***

Associate Professor Maharaja Krsuhan Chandra Gajapati Medical College and Hospital Berhampur

\*Corresponding author

**Abstract**--The aim of this study was to (1) detect the prevalence of anatomical variations of nose and paranasal sinuses in Chronic Rhinosinusitis (CRS) on 'Nasal Endoscopy and Computed Tomography', (2) study association of anatomical variations of nose and paranasal sinuses in Chronic Rhinosinusitis. This hospital based cross sectional study was performed during the period from January 2020 to October 2022 on patient between 20 to 60 yrs. of age referred to the department of Radiodiagnosis for evaluation of MDCT PNS from Dept. of ENT, S.C.B medical college and hospital Cuttack. Diagnostic Nasal Endoscopy and Computed Tomography of nose and Paranasal Sinuses of 80 patients of chronic rhinosinusitis were studied and results were. Maximum patients included in study population was 20-25 years with male predominance. Deviated Nasal Septum was the most common anatomical variation, which was detected in 70(87.5%) patients on Diagnostic Nasal Endoscopy and Agger nasii cells were observed in 60(75%) patients on Computed Tomography. The other anatomical variations like Concha bullosa 56(70%) were diagnosed both by Diagnostic Nasal Endoscopy. Anatomical variations like deviated nasal septum, agger nasi cells, medialised uncinated process,

large concha bullosa were associated with chronic rhinosinusitis. Diagnostic nasal endoscopy and CT scan are complimentary in diagnosis of anatomical variations of nose and paranasal sinuses. Some anatomical variations of osteomeatal complex play important role in pathogenesis of chronic rhinosinusitis.

**Keywords**--Anatomical variations, chronic rhinosinusitis, computed tomography, diagnostic nasal endoscopy.

## **Introduction**

Chronic Rhinosinusitis (CRS) is chronic inflammation of nose and paranasal sinuses. Its pathophysiology is poorly described and seems to be multifactorial. With the arrival of Functional Endoscopic Sinus Surgery, the approach to the patient with CRS has been changed. Certain anatomical variations of lateral wall of nose are important as they contribute in blockage of osteomeatal complex, ventilation and drainage of paranasal sinuses. Preoperative evaluation of these variants is also important being a part of surgical safety.[1] Para nasal sinuses (PNS) are the air containing spaces in the skull. They lighten the skull, humidify air and provide resonance to voice.[2] There are four pairs of sinus cavities: the maxillary, ethmoid, frontal, and sphenoid sinuses. Anatomical variations of nose and para nasal sinuses are common.[3] These anatomical variants can cause impair in free air flow and can leads to chronic rhinosinusitis (CRS). Anatomical variants can lead to intracranial and intraorbital complications during the procedure like functional endoscopic sinus surgery (FESS), consider as gold standard in treatment of chronic rhinosinusitis. [4]The complexity of nose and para nasal sinuses anatomy as well as its variants may create technical difficulties during surgery. Hence the knowledge of normal anatomy and various variants of para nasal sinus are helpful in avoiding surgical complications and may contribute to improved surgical outcome. Multidetector Computed tomography (MDCT) is the imaging modality of choice and gold standard in the study of detail anatomical structure of PNS.[5]

Several studies have been carried out to find out the relationship between anatomical variations and chronic rhinosinusitis on CT scan. But very few studies have been found reported comparing Diagnostic Nasal Endoscopy and CT scan in diagnosing anatomical variations of nose and paranasal sinuses in chronic rhinosinusitis. [6]We conducted this study with the aim to study the prevalence of anatomical variations of nose and paranasal sinuses in Chronic Rhinosinusitis (CRS) on Nasal Endoscopy and CT Scan, correlate between the two investigation modalities and study association of anatomical variations of nose and paranasal sinuses in Chronic Rhinosinusitis.[7]

## **Materials and Methods**

This hospital based cross sectional study was performed during the period from January 2020 to October 2022 on patient between 20 to 60 yrs. of age referred to the department of Radiodiagnosis for evaluation of MDCT PNS from Dept. of ENT, S.C.B medical college and hospital Cuttack. This study included 80 patients,

provisionally diagnosed as chronic rhinosinusitis. All the subjects were properly informed and written informed consent was taken. The study was performed on GE Bright speed 16slice MDCT scan machine. [1,2] Both direct coronal and axial scanning was performed. In the axial scan, Scanning extends from upper margin of frontal sinus to the level of hard palate below and in the coronal scan scanning extended from anterior wall of frontal sinus to posterior margin of sphenoid sinus. Images in axial, coronal and sagittal plane were obtained. 140kv, 200mA, .625mm section thickness, 0.625 mm interval, 10 mm beam collimation, spiral pitch factor of 0.5625.

## Results

This hospital based cross-sectional study includes 80 chronic rhinosinusitis patients (CRS) who were referred from dept. of ENT S.C.B MCH, to our dept. of Radiology S.C.B MCH CUTTACK for MDCT PNS. In our study the demographic profile shows the most common age group affected to be between 20-25yrs. Out of 80 patients 22 patients (27.5%) were between age group 20-25 years, 15 patients (18.7%) were between age group 26-30 years, 12 patients (15%) were between age group 31-35 years, 4 patients (5%) were between age group 46-50 years, 5 patients (6.2%) were between age group 51-55 years, 7 patients (8.7%) were between age group 56-60 years.

In our study most of the patients had more than one anatomical variation. Out of 80patients studied, 76 (95%) of patients had more than one anatomical variation, of these 50 (65.78%) were males and 26 (34.21%) were females. Only minor group of patients presented with one anatomical variation 4 (5%). In our study all the patients had at least one anatomical variation. All the anatomical variations recorded in this study were depicted in Table no.1 shown below.

In this study the most common anatomical variation noted in our study was deviated nasal septum, shown in fig 1. It was noted in 70(87.5%) patients. Out Of which 49 patients were male and 21 patients were female. Right side deviation was common noted in 44 patients and left side deviation in 26 patients. The second most common anatomical variant noted in our study was agger nasi cell, noted in 60(75%) patients. Of which, unilateral presentation was in 40 (66.6%) and bilateral presentation was in 20 (33.3%) patients. Of the unilateral presentation right side was more common in 22 patients and left side in 18 patients. A next common anatomical variant noted in our study was Concha bullosa, noted in 56(70%). Of which unilateral presentation were in 43 patients. Of this, unilateral presentation on left side was more common, noted in 32 patients and 11 patients noted on right side. Bilateral presentation of concha bullosa noted in 13 patients.

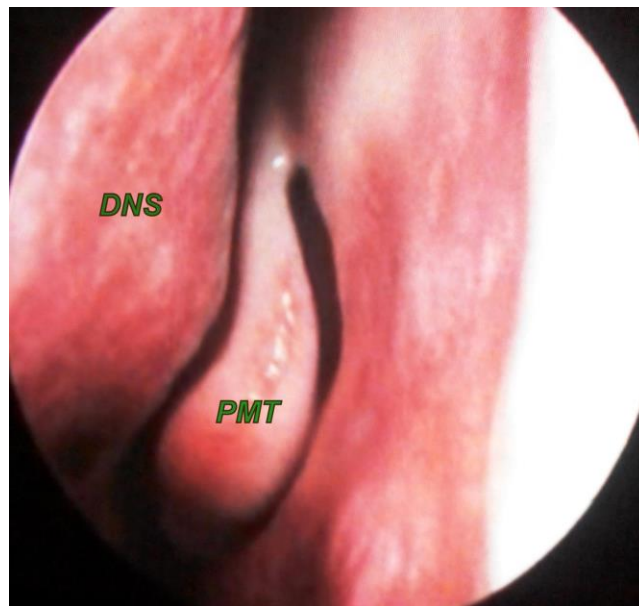


Fig. 1-Deviated Nasal Septum to left with Paradoxical Middle Turbinate (PMT) on Left side on DNE

Table no. 1- Distribution of various anatomical variations in nose and pns in patients with crs

Sl. no.	Anatomical variation	Male			Female			Total no. of cases
		Rt	Lt	Bi lat	Rt	Lt	Bi lat	
1	DNS	34	15		10	11		70(87.5%)
2	Agger nasi cell	17	12	11	5	6	9	60(75%)
3	Concha bullosa	4	25	10	7	7	3	56(70%)
4	Prominent bulla ethmoidalis	13	7	10	9	5	4	48(60%)
5	Paradoxical middle turbinate	3	7	2	6	1	4	23(28.7%)
6	Medialized uncinat process	5	3	3	3	2	2	18(22.7%)
7	Onodi cell	2	5	4	0	0	3	14(17.5%)
8	Frontal cell	1	1	5	5	3	1	16(20%)
9	Haller cell	3	2	1	1	1	2	10(12.5%)
10	Pneumatized uncinat process	0	1	1	3	0	1	6(7.5%)
11	Supra orbital cells	0	1	3	0	0	2	6(7.5%)

The next common anatomical variant noted was prominent bulla ethmoidalis, seen in 48 patients (60%). Of which unilateral presentation was common in 34 patients and bilateral presentation in 14 patients. Of the unilateral presentation, right side in 22 patients and left side in 12 patients. Paradoxical middle turbinate

was noted in 23 patients (28.75%), of which unilateral in 17 and bilateral in 6 patients. Out of 17 unilateral patients, right side paradoxical middle turbinate was observed in 9 patients and left side in 8 patients. Medialized uncinate process presented in 18 (22.5%) patients. Of which unilateral presentation was more common 13 (72.2%). Of which 8 were on right side and 5 were on left side. Bilateral presentation was in 5 patients. Onodi cell presented in 14 (17.5%) patients, of which 7 patients presented with bilateral presentation and 7 patients with unilateral presentation. Left side Onodi cell noted in 5 patients and right side Onodi cell noted in 2 patients. Frontal cell presented in 16 patients (20%), of which unilateral presentation was more common noted in 10 patients. Out of which right side in 6 patients and 4 patients on left side. Bilateral frontal cell noted in 6 patients. Haller cells were noted in 10 patients (12.5%), of which unilateral presentation was common noted in 7 patients and bilateral presentation in 3 patients. Out of 7 unilateral cases, 4 cases on right and 3 cases on left side. Pneumatized uncinate process was found in 6 patients. Unilateral presentation noted in 4 patients, of which right side in 3 patients and left side in 1 patient. Bilateral presentation noted in 2 patients. Supra orbital cells noted in 6 patients (7.5%). Of which bilateral presentation was common, noted in 5 patients. Left sided supra orbital cell was noted in 1 patient.

## **Discussion**

The anatomy of nose and PNS is very complicated and their anatomical variants are very frequent [3]. To evaluate the normal anatomy, its variant and to diagnose the disease at this region, physical examination and conventional radiographic examinations are not always able to provide sufficient information [4]. MDCT PNS on coronal plane is main methods used to demonstrate the CRS preoperatively. The advantage of this approach for FESS is that; it can provide anatomical and pathological image with same perspective to the surgeon [5].

In our study the demographic profile, Table 1 shows the most common age group affected to be between 20-25yrs. Out of 80 CRS patients, 27.5% were between age group 20-25 years and 18.7% were between age group 26-30 years. Among 80 patients enrolled in our study, 65% were male and 35% were female. Similar results were reported in a study by Surapaneni et al [6]. In our study the prevalence of various anatomical variants of nose and PNS noted were in order as follows DNS 87.5%, Agger nasi cell 75%, Concha bullosa 70%, Prominent bulla ethmoidalis 60% Paradoxical middle turbinate 28.7%, Medialized uncinate process 22.7%, Onodi cell 17.5%, Frontal cell 20%, Haller cell 12.5% Pneumatized uncinate process 7.5% Pneumatization of septum 3.75%, Intumescencia septi nasi anterior 27.5% Supra orbital cells 7.5% Pneumatization of superior turbinate 3.75%.

DNS with or without bony spur causes a decrease in the critical area of the osteomeatal unit predispose to obstruction and related complications. It was found in 70 out of 80 patients, the maximum anatomical variation in our study in 87.5 % patients. Right side deviation was common noted in 44 patients and left side deviation noted in 26 patients. Shokri A, Faradmal MJ et al. noted prevalence of DNS in 90% patients [7] comparable to our study. Luo et al. [8] reported prevalence of septal variations between 40% and 96.9% due to varying

morphological features and the extent of deviation. In our study second most common anatomical variant was agger nasi cell, noted in 75 %. Agger nasi cells may cause obstruction to nasofrontal duct (frontal sinus drainage pathway) and predispose to chronic frontal sinus disease. Yadav R et al. reported that, Agger nasi cell is the commonest anatomical variation in 75.8% patients [9], finding was in concordance with our study.

Concha bullosa has been implicated as a possible aetiological factor in the causation of CRS. It is due to its negative influence on para nasal sinus ventilation and mucociliary clearance in the middle meatus region. The incidence of concha bullosa in our study was 70% of which unilateral presentation were in 43 patients. Of this, unilateral presentation on left side was more common, noted in 32 patients and 11 patients noted on right side. Bilateral presentation of concha bullosa noted in 13 patients. Incidence of concha bullosa noted in our study was higher as compared to the reported incidence of 53.6% by Bolger et al [10], 42.6% by Maru et al. [11]. This discrepancy could be due to the varying definitions of concha bullosa used for diagnosis. In our study we defined any degree of pneumatization, regardless of size or location, as consistent with concha bullosa. Other studies restricted concha bullosa to specific locations on the turbinates and/or to a minimum size of pneumatization [10,12].

The next common anatomical variant noted in our study was prominent bulla ethmoidalis, seen in 48 (60%) patients. Of which unilateral presentation was common in 34 patients. Fadda et al. reported a high incidence of enlarged ethmoid bulla in 89% of cases [13,14] and Ahmed M. et al. detected large ethmoid bulla in 10% [15]. This difference in prevalence could be due to the varying definitions of prominent ethmoidal bulla. Ethmoidal bulla is the largest and most consistent anterior ethmoidal air cells. Extensive Pneumatization (prominent ethmoidal bulla) may obstruct the omu. Elongated ethmoid bullae are usually the result of pneumatization that extends in a superior to inferior direction rather than in an anterior to posterior direction are relatively unlikely to obstruct the osteomeatal complex [16]. In our study we included the prominent ethmoidal bulla.

The paradoxical middle turbinate may lead to impingement of the middle meatus and predisposed to chronic rhinosinusitis. It was found in 28.75 % in our study. Of which unilateral in 17 and bilateral in 6 patients. Out of 17 unilateral patients, right side paradoxical middle turbinate was observed in 9 in patients. This finding was in concordance with Bolger et al. noted in 27% [17] and Bhargava D et al. noted in 24% cases [18]. Zinreich [19,20] first observed that the uncinate process may be curved or bent. It can impair sinus ventilation especially in the anterior ethmoid, frontal recess and infundibulum regions. The medialized uncinate was found in 22 % patients in our study. A similar incidence of medialized uncinate process was noted by I.P. Tuli et al., in 24% cases [13].

Frontal cells, along with the agger nasi cell, constitute the anterior group of frontal recess cells. In our study frontal cell excluding agger nasi cell noted in 16 patients (20%), of which unilateral in 10 patients and bilateral in 6 patients . Del Gaudio et al. noted a similar prevalence of frontal cells, in 20%–33% cases[21]. Onodi cells are posterior ethmoid cells that extend posteriorly, laterally and

sometimes superior to sphenoid sinus, lying medial to the optic nerve. The chances of injury of optic nerve are increased when the bony canal of the nerve is lying dehiscient. It was found in 17.5 % patients in our study. Nearly similar incidence of 12% was found by Arslan et al. and 24% cases by John Earwarker [22]. Haller cells are ethmoid air cells that project beyond the limits of the ethmoid labyrinth into the maxillary sinus. They are considered as ethmoid cells that grow into the floor of orbit and may narrow the adjacent ostium of the maxillary sinus especially if they become infected. The prevalence of Haller cells in our study was 12.5% (10 patients), of which unilateral in 7 patients. Nearly similar incidence was found in 11.2% by Ahmed M. et al. [15], 10% by Zinreich S et al. and in 14% by Mathew R et al. [23].

Next anatomical variant noted in our study was Supra orbital cells, in 6 patients (7.5%) of which bilateral presentation was common, noted in 5 patients. Left sided supra orbital cell was noted in 1 patient. In concordance with our study, Mallikarjun et al. noted incidence of supra orbital cells in 4% cases in their study [24]. In our study pneumatized unciniate process was found in 6 patients (7.5%). Unilateral presentation noted in 4 patients, of which right side in 3 patients and left side in 1 patient. Bilateral presentation noted in 2 patients. I.P. Tuli et al. noted a pneumatized unciniate process or unciniate bulla in 4% cases comparable to our study [13].

In our study more than one sinus involvement was noted in about 55% patients. The most common individual sinus involved was maxillary sinus, noted in 60% patients, followed by anterior ethmoid sinus in 33.7%, frontal sinus in 31.25%, posterior ethmoid sinus in 13.7 %, sphenoid sinus in 20%. In a study by Zinreich [20,21], noted involvement of maxillary sinus in 65 %, frontal sinus in 34%, ethmoid sinus in 40%, and sphenoid in 29%. Bolger [25] reported maxillary sinus involvement in 77.7 %, ethmoid sinuses in 38.6 %, frontal sinus in 36.6 %, and sphenoid sinus in 25.4 %. The extent of sinus involvement noted in our study was nearly similar to these studies. Jamie S. Stallman et al. [13] found that there was a significant relationship between the presence of concha bullosa and deviation of the nasal septum to the contralateral side. In our study we found that left sided CB in 32 patients, right sided DNS in 44 patients, and right sided CB in 11 patients, left sided DNS in 26 patients. The Calculated chi square value in our study was 14.793, which is greater than tabular chi square value (3.84) with significance level =0.05, shows a significance correlation between the presence of concha bullosa and deviation of the nasal septum to the contralateral side. Yousem et al. (24) found that when the middle meatus was opacified, the maxillary and ethmoid sinuses showed inflammatory changes in 84% and 82% respectively. Thus these findings support the contention that the anatomical variation in nose and para nasal sinuses will lead to obstruction of the narrow drainage pathways, which in turn lead to subsequent sinus inflammation (chronic rhinosinusitis).

## **Conclusion**

Computed Tomography of the para nasal sinuses has improved the visualization of para nasal sinus anatomy and has allowed greater accuracy in evaluating para nasal sinus diseases. It evaluates the osteomeatal complex anatomy which is not

possible to such an extent with plain radiographs. Anatomical variations studied on Computed Tomography Scan are found to block the drainage pathway, leading to impaired drainage of para nasal sinuses, thus causing chronic sinusitis. Our present cross-sectional study “MDCT evaluation of anatomical variants of nose and para nasal sinus in patients with chronic rhinosinusitis” reveals many parameters: 1. in patients with chronic rhinosinusitis, a combination of anatomical variations is more commonly found. 2. Of the anatomical variations in patients with chronic sinusitis, nasal septal deviation is the commonest abnormality noted in 87.5% patients. 3. Other common anatomical variations in patients with chronic rhinosinusitis noted are agger nasi 75 % and concha bullosa 70 %. 4. According to the results, nasal septal deviation is the most common anatomic variation and the pneumatized superior turbinate and pneumatized septum are the rarest one noted in our study. 5. Also, there is a strong correlation between the unilateral Concha bullosa and contra lateral septal deviation, which was evident based on the studies. Moreover, more than 90% of anatomic variations are nasal septal deviation, agger nasi cell and concha bullosa.

## References

1. Benninger MS, Ferguson BJ, Hadley JA, Hamilos DL, Jacobs M, Kennedy DW et al. Adult chronic rhinosinusitis: Definitions, diagnosis, epidemiology, and pathophysiology. *Otolaryngol Head Neck Surg* 2003;129(3 Suppl):S1-32.
2. Hopkins C, Brown JP, Slack R, Lund V, Brown P. The Lund-Mackay staging system for chronic
3. rhinosinusitis: How is it used and what does it predict? *Otolaryngol Head Neck Surg* 2007;137(4):555-61.
4. Ahmed M, Alsowey, GhadaAbdulmonaem, Ahmed Elsamak, Yasser FouadPol *J Radiol*. 2017; 82: 713–725. PMID: PMC5894030
5. Delbort a b, jocyline l m mutsuhisa f, kook s o, lionel w. radiological imaging in otorhinolaryngology. *Pediatric clinics of north America* 1981;28(4)
6. Dalgorf DM, Harvey RJ. Chapter 1: Sinonasal anatomy and function. *Am J Rhinol Allergy*. 2013;27(Suppl 1):S3–S6
7. 6. Surapaneni H Sisodia SS. Aetiology, diagnosis and treatment of chronic rhinosinusitis: a study in a teaching hospital in Telangana. *Int J Otorhinolaryngol Heah Neck Surg* 2016;2:14-7
8. Shokri A, Faradmal Mj, Hekmat B. correlations between anatomical variations of the nasal cavity and ethmoidal sinuses on cone-beam computed tomography scans. *Imaging Sci Dent*. 2019 jun;49(2):103-113.
9. Luo X, Liang C, Xu K, et al. [Influence of nasal septal deviation on incidence of bilateral sinusitis.] *Lin Chung Er Bi Yan Hou Tou Jing Wai Ke Za Zhi*. 2012;26(17):777–80.
10. Yadav RR, Ansari MA, Humagain M, Mishra D. Assessment of anatomical variations of nose and paranasal sinuses in multidetector computed tomography. *J Inst Med* 2017; 39: 49-54.

11. Bolger WE, Butzin CA, Parsons DS. Paranasal sinus Bony anatomic variation and mucosal abnormalities: CT analysis for endoscopic sinus surgery *Laryngoscope* 1991;101:56-65.
12. Maru Y K, Gupta V. Anatomic variations of the bone in sinonasal CT. *Indian J of Otolaryngology and Head and Neck Surgery* 2001;53(2):123-128.
13. Jamie S. Stallman, Joao N. Lobo and Peter M. Som *American Journal of Neuroradiology* October 2004, 25 (9) 1613-1618.
14. I.P. Tuli. S. Sengupta. S. P. Kesari. S. Chakraborty. Anatomical variations of uncinat process observed in chronic sinusitis *2013;65(2):157-161*.
15. Fadda GL, Rosso S, Aversa S, et al. Multiparametric statistical correlations between paranasal sinus anatomic variations and chronic rhinosinusitis. *Acta Otorhinolaryngol Ital.* 2012;32(4):244-51.
16. Suryasa, I. W., Rodríguez-Gómez, M., & Koldoris, T. (2021). The COVID-19 pandemic. *International Journal of Health Sciences*, 5(2), vi-ix. <https://doi.org/10.53730/ijhs.v5n2.2937>
17. Ahmed M. Alsowey, Ghada Abdulmonaem, Ahmed Elsammak, Yasser Fouad *Pol J Radiol.* 2017; 82: 713-725. PMID: PMC5894030
18. Ethmoidal bulla (radiopaedia.org) X. Mohammad Javed Ali. *Principles and Practice of Lacrimal Surgery.* (2018) p.55 ISBN: 9789811054426.
19. Bolger WE, Butzin CA, Parsons DS. Paranasal sinus Bony anatomic variation and mucosal abnormalities: CT analysis for endoscopic sinus surgery *Laryngoscope* 1991;101:56-65.
20. Bhargava D, Bhargava K, Al-Abri A, et al. Non allergic rhinitis: Prevalence, clinical profile and knowledge gaps in literature. *Oman Med J.* 2011;26(6):416-20.
21. Zinreich S. Paranasal sinus imaging. *Otolaryngol Head Neck Surg* 1990;103:863-868.
22. Ananda, A., Baso, Y. S., Hidayanty, H., Syarif, S., Aminuddin, A., & Bahar, B. (2022). Providing education chronic energy deficiency (CED) uses web-based she smart to improve knowledge, attitudes, and practice in adolescent girls. *International Journal of Health & Medical Sciences*, 5(1), 56-62. <https://doi.org/10.21744/ijhms.v5n1.1833>
23. Zinreich S. Imaging of inflammatory sinus disease. *Otolaryngol Clinical North Am* 1993;26:535-547.
24. DelGaudio JM, Hudgins PA, Venkatraman G, Beningfield A. Multiplanar computed tomographic analysis of frontal recess cells: effect on frontal isthmus size and frontal sinusitis. *Arch Otolaryngol Head Neck Surg* 2005;131(3):230-235.
25. Earwaker J. Anatomic variants in sinonasal CT. *Radiographics.* 1993;13(2):381-415.
26. Mathew R, Omami G, Hand A, et al. Cone beam CT analysis of Haller cells: Prevalence and clinical significance. *Dentomaxillofac Radiol.* 2013; 42:44-55.
27. Mallikarjun M. Devareddy, Shilpa Devakar *International Journal of Contemporary Medicine Surgery and Radiology.* 2019;4(3):C146-C151.

28. Anatomy of Orofacial Structures - Enhanced 7th Edition: A Comprehensive Approach, 7e (Anatomy of Orofacial Structures (Brand)). Mosby. ISBN: 0323227848.