

How to Cite:

Mahayani, I. A. M., & Rusmiatik, R. (2022). Papaya leaf (*Carica papaya* L.) ethanol extract to the histopathological description of the testimony in in the house mouse (*Mus Musculus*). *International Journal of Health Sciences*, 6(S4), 6288–6298.
<https://doi.org/10.53730/ijhs.v6nS4.9589>

Papaya leaf (*Carica papaya* L.) ethanol extract to the histopathological description of the testimony in in the house mouse (*Mus Musculus*)

Ida Ayu Made Mahayani

Faculty of Medicine, Universitas Islam Al-Azhar, Indonesia

Rusmiatik

Faculty of Medicine, Universitas Islam Al-Azhar, Indonesia

Abstract---The development of contraceptive methods is more focused on female contraception than men is still lacking. Papaya leaves are thought to have an antifertility effect due to the content of secondary metabolites, namely flavonoids, alkaloids, saponins, tannins and papain enzymes that have estrogenic effects that can disrupt hormone regulation in the hypothalamic-pituitary-gonadal axis. This study aimed to prove the administration of ethanol extract of papaya leaves (*Carica papaya* L.) on the histopathological features of the testicles of young adult mice (*Mus musculus*). Subjects and Method: This research uses an experimental study with a post-test only control group design. The samples used were male Swiss Webster strain mice (*Mus musculus*) 2-3 months old with a bodyweight of 20-30 grams as many as 36 individuals were divided into 2 groups. The control group (P0) was given 0.5 ml of Tween 3% and the treatment group (P1) was given ethanol extract of Papaya Leaf (*Carica papaya* L.) 0.21 mg/gram BW as much as 0.5 ml for 36 days orally. The data obtained were analyzed using the Independent Sample T-test. Result: A total of 11 articles from Asia continent (India, Bangladesh, Philipina, and Nepal). The data collected showed that kangaroo mother care increased growth (length gain) of LBW infants 0.21 times and was statistically significant (SMD= 0.21; CI 95%= 0.19 hingga 0.22; $p < 0.001$). Conclusion: Kangaroo mother care increases length gain in LBW babies.

Keywords---kangaroo mother care, growth, length gain, LBW.

Introduction

The increasing population has an impact on quite important problems for developing countries, one of which is Indonesia (Wijayanti et al., 2016). This increase in population will affect the welfare of the population (Hasanah and Sukarjati, 2016). This population problem must be handled by the government with a program from the National Population and Family Planning Agency (BKKBN), namely Family Planning (KB) (Dewanti et al., 2020).

The family planning program service itself is one of the strategies to regulate and plan birth spacing. Family planning programs through contraceptive methods used in an effort to provide services to the community have been widely offered by the government, both contraception for women and men (Delfita, 2014). The development of contraceptive methods is more focused on female contraception while contraceptive methods for men are still lacking (Kasmeri and Putri, 2020). Contraceptives for men currently available are condoms, interrupted sex, and vasectomy, which still have shortcomings (Ratri and Andriani, 2020). So it is necessary to develop contraception quickly to achieve azoospermia and is reversible, does not interfere with libido, and has minimal side effects (Hasanah and Sukarjati, 2016).

Many attempts have been made to develop contraception for men by using herbal plants that are predicted to have antifertility properties (Fatmawati, 2016). The Indonesian people themselves have long known medicinal plants, one of which comes from papaya leaves (A'yun and Laily, 2015). Papaya (*Carica papaya* L.) is a flowering plant and belongs to the Caricaceae family which is predicted to have antifertility properties (Syamsuddin et al., 2021). Papaya is a plant that grows a lot in every area in Indonesia and has an economical price and is much liked by the community (Ardiansyah, 2020). Papaya leaves contain secondary metabolites: flavonoids, alkaloids, triterpenoids, and saponins (Fauzi'ah and Wakidah, 2019). These metabolites are thought to have the potential to have an antifertility effect (Dewanti et al., 2020).

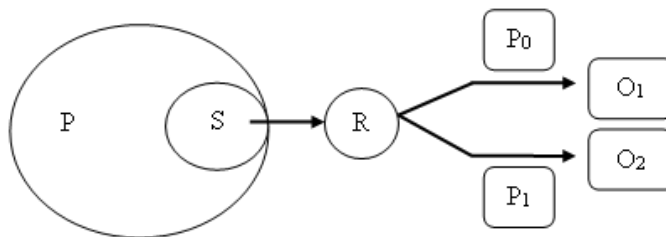
The flavonoid compounds contained in papaya leaves are predicted to have antifertility by inhibiting the function of the hypothalamic-pituitary-gonadal axis so that spermatogenesis can be disrupted because it can be phytoestrogen (Ashfahani et al., 2010). In addition, papaya leaves contain the papain enzyme which can cause the breaking of chemical bonds in protein molecules as a synthesis of reproductive hormones, causing a decrease in reproductive hormones (Syamsuddin, 2021). Scientific research related to papaya plants as antifertility has been carried out. Satriyasa's research in 2010 showed a decrease in the appearance of spermatogonia of male mice in both the hexane fraction and the methanol fraction from the Young Papaya Seed extract for 36 days. Research conducted by Laili in 2018 showed a significant decrease in the movement or motility of spermatozoa in rats given Papaya Leaf ethanol extract for 20 days. Based on the above review related to the lack of male participation in using contraception, the limited availability of male contraceptives, and the chemical content of Papaya Leaves as potential antifertility agents, a study was conducted on administering ethanol extract of Papaya Leaf (*Carica papaya* L.) to the

histopathological description of the testes in mice (*Carica papaya* L.) *Mus musculus*) young adults

Subjects and Method

Study Design

This study uses a true experimental research design using a post-test only control group design (Rinaldi and Mujianto, 2017). The scheme in this study is described as follows:



Population and Sample

The target population for this experimental study was all male (*Mus musculus*) mice with Swiss Webster strain. The affordable population in this study were male *Mus musculus* with Swiss Webster strain with bodyweight between 20-30 grams and mice aged 2-3 months. In this study, samples were taken from mice (*Mus musculus*) that met the inclusion and exclusion criteria with the following conditions:

Inclusion Criteria

- 1) Mice (*Mus musculus*) with Swiss Webster strain
- 2) 2-3 months old
- 3) Weight 20-30 grams
- 4) Healthy

Exclusion Criteria

- 1) Don't want to eat and drink
- 2) There are congenital abnormalities or abnormalities

Research Variable

The research variables to be measured are the independent variable and the dependent (dependent) variable. Independent variable: Ethanol Extract of Papaya Leaves (*Carica papaya* L.) Dependent variable: Histopathology of Mice Testis (*Mus Musculus*).

Operational Definition of Variables

Ethanol Extract of Papaya Leaves (*Carica Papaya L.*) is Papaya Leaf Ethanol Extract (*Carica papaya L.*) is an extract derived from Papaya Leaf (*Carica papaya L.*) which is then extracted from the maceration using 96% ethanol solvent for 24 hours at room temperature. The dose of Papaya Leaf Extract (*Carica papaya L.*) used was 0.21 mg/g BW mg per mouse, this dose was obtained from referring to the study before dose conversion was carried out and given to experimental animals orally

Mice (*Mus musculus*) is the mice (*Mus musculus*) used in this study were male mice (*Mus musculus*) with Swiss Webster strain 2-3 months old as evidenced by a certificate given by the seller. The weight of the mice (*Mus musculus*) used was 20-30 grams which was determined by digital weighing.

Histology of the testes is The examination was carried out on the seminiferous tubules of mice which saw spermatogonia cells, spermatids, spermatocytes and Leydig cells viewed at 400 times magnification under a light microscope and observed 3 times and then averaged.

Study Instruments

In this study the research instrument as follows:

Weighing of mice was measured using a digital scale

Making extract using ethanol solvent and evaporator

Histopathological observations using a microscope

Summary of Research Flow

This study uses a purely experimental research design using a post-test only control group design. Papaya leaves (*Carica papaya L.*) are cleaned by washing then the leaves are separated from other parts and cut into small pieces. After that, it is dried by aerating. Dried Papaya leaves crushed / blended until smooth until it forms a powder. Maceration was done by soaking Papaya Leaf powder in 96% ethanol solvent. After that it was evaporated using a rotary evaporator at a temperature of 68°C, the remaining alcohol solvent was then evaporated in a water bath to produce a thick extract. In this study, a dose of 0.21 mg/g BW was used. In this study, a phytochemical screening test will also be carried out on papaya leaf extract.

The test animals used in this study were male Swiss Webster (*Mus musculus*) mice 2-3 months old and weighing 20-30 grams. The test animals were given ad libitum animal feed and adapted for 7 days. A total of 36 tails were divided into 2 groups. The control group (P0) was given 0.5 ml of Tween 3% and the treatment group (P1) was given ethanol extract of Papaya Leaf (*Carica papaya L.*) 0.21 mg/gram BW as much as 0.5 ml for 36 days orally. On the 37th day of treatment, all mice were anesthetized using Ket-A and Xyla. After the unconscious mice were surgically removed, the cauda epididymis was taken to be examined for the concentration, morphology, motility, and viability of spermatozoa.

Histopathological observations were taken on the testicles of mice by staining using Hematoxylin and eosin (H&E). Then the histopathological picture of testicular tissue was observed under a microscope with 400 times magnification in 3 fields of view. Primary data in the form of histopathological examination results in the control group and the treatment group Search for studies or articles based on eligibility criteria, namely inclusion and exclusion criteria. The inclusion criteria in this research are: a) full-text article; b) Kriteria inklusi dalam penelitian ini adalah a) artikel full text; b) the article uses Indonesian and English; c) population: low birth weight babies; d) intervention: kangaroo mother care; e) comparison: conventional method care; f) outcome: length gain; g) randomized controlled trial design; h) the size of the relationship used is Mean and SD. The exclusion criteria are articles published in languages other than English and Indonesian, articles before 2008, and articles that are not free access.

Data Analysis

In this study, data analysis was obtained and analyzed using statistical product and service solutions (SPSS) software application with version 21.0 through the following steps:

a. Descriptive analysis

All data will be analyzed descriptively to determine the characteristics of the data held in this study. The data analysis is a univariate analysis to describe the characteristics of the basic data of the variables used, namely the mean, median, standard deviation, minimum and maximum values in the histopathological description of the mice testes.

b. Normality analysis

The data in this study will be tested by testing the normality of the data using the Shaphiro-Wilk test where the sample in this study is 50 (sample 36). The data is said to be normally distributed if the results of the Shaphiro-Wilk test are $p > 0.05$

c. Homogeneity test

In this study, the homogeneity of the data was tested using the Levene's test, the results of this test will show a homogeneous data variance if $p > 0.05$

d. Comparative analysis

In comparative analysis, if the data is normally distributed and homogeneous ($p \geq 0.05$) then the comparison test used is the Independent T-test, if the data is not normally distributed then the data transformation is carried out using a non-parametric test, namely Mann Whitney.

Research Ethics

Research ethical issues, including consent, anonymity, and confidentiality, were handled with care throughout the research process. The research ethics permit approval letter was obtained from the Animal Ethics Committee, Faculty of Veterinary Medicine, Udayana University, Indonesia, No. B/164/UN14.2.9/PT.01.04/2021, on August 16, 2021.

Results

Sample Characteristics

The results of descriptive research data in this study are presented in Table 1.1 which consists of spermatogonia cells, spermatocytes, spermatids and Leydig cells from spermatozoa to obtain results from the mean value, standard deviation, minimum value and maximum value of the data obtained.

Table 1.1
Sperm Quality Descriptive Analysis Results

Variable	Group	N	Mean	SD	median	min	max
Spermatogonia	Control	18	41,79	3,13	41,0	37	49
	Treatment	18	26,67	3,69	26,50	22	33
Spermatosit	Control	18	64,44	2,64	65,00	59	69
	Treatment	18	41,69	2,15	42,50	38	45
Spermatid	Control	18	90,83	6,45	91,00	79	99
	Treatment	18	68,89	7,20	68,00	56	83
Sel Leydig	Control	18	18,67	3,23	18,00	13	24
	Treatment	18	11,22	1,66	11,00	8	14

Bivariate Analysis

The comparability test was used to determine the comparison of the mean between groups of spermatozoa histopathological variables in the control group and the treatment group where the data were normally distributed and then tested using the Independent Sample T-test, namely the histopathological picture can be seen in Table 2.1.

Table 2.1
Results Independent Sample T-test Histopathology of the testes of mice

Variable	Mean	p-value (p)	CI 95%		Standard Error (SE)
			Upper limit	Limit Lower	
Spermatogonia	15,11	,000	17,43	12,79	1,14
Spermatosit	22,50	,000	24,13	20,87	0,80
Spermatid	21,94	,000	26,57	17,31	2,28
Sel Leydig	7,44	,000	9,18	5,70	0,85

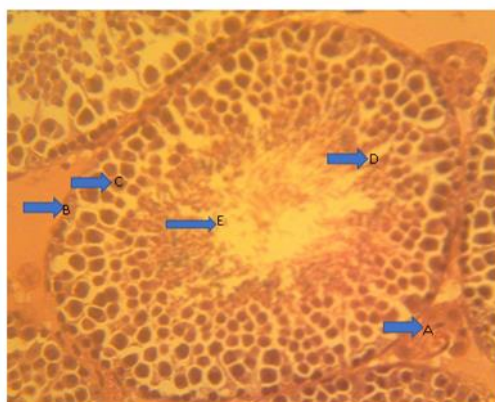


Figure 1. Histopathological appearance of abnormal seminiferous tubules.
Description: A. A. Leydig Cells, B. Spermatogonia Cells, C. Spermatocytes, D. Spermatid Cells, E. Spermatozoa Cells

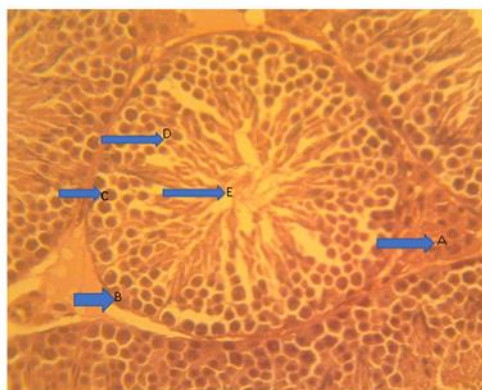


Figure 2. Histopathological appearance of normal seminiferous tubules.
Description: A. A. Leydig Cells, B. Spermatogonia Cells, C. Spermatocytes, D. Spermatid Cells, E. Spermatozoa Cells

Discussion

In the results of this study, by administering Papaya Leaf Ethanol Extract (*Carica papaya* L.) to young adult mice (*Mus musculus*), it was found that there was an effect on the histopathological picture. Histopathology in this study showed that the mean results of spermatogonia, spermatocytes, spermatids and Leydig cells in the control group were higher than in the treatment group. The statistical test showed a significant difference in the mean results of spermatogonia, spermatocytes, spermatids and Leydig cells in the two groups. The results of the phytochemical screening test in this study obtained secondary metabolites contained in papaya leaves, namely flavonoids, alkaloids, saponins, tannins, steroids and triterpenoids. This study is in line with that conducted by Widyanjaya et al., 2020 using papaya seeds on the histopathological features of mice. It is predicted that the secretion of LH in the anterior pituitary which stimulates the growth of Leydig cells is inhibited. Decreased testosterone causes the seminiferous tubules to atrophy. These results can be seen in the treatment

group the diameter of the lumen of the seminiferous tubules in the treatment group is reduced.

Research conducted by Airaodion et al., (2019) using papaya leaves (*Carica papaya* L.) can increase spermatozoa abnormalities (spermatozoa morphology) in Wistar rats due to the content of papain and chymopapain enzymes in papaya leaves which can hydrolyze semen protein which will cause damage to spermatozoa. Papain and chymopapain enzymes can damage Sertoli cells so that the formation and maturation of spermatogenesis can be disrupted resulting in abnormal morphological abnormalities in spermatozoa cells. In addition, the alkaloid content is predicted to have an estrogenic effect by interfering with the mechanism of testosterone formation. The high increase in testosterone causes negative feedback to the hypothalamus causing the synthesis of testosterone hormone in Leydig cells to decrease which results in the diameter of the seminiferous tubules and germ cells being disrupted (Widiastuti et al., 2016). In addition, the decrease in spermatid cells is thought to be caused by secondary metabolites, namely alkaloids and flavonoids that can suppress the secretion of reproductive hormones, namely testosterone. which can cause the spermatogenesis process to be disrupted, where the hormone testosterone itself is needed in the process of spermatogenesis in the seminiferous tubules (Amilah et al., 2019).

In addition, the content of flavonoids which can be estrogenic can occupy estrogen receptors in the body and cause an estrogen-like effect, causing inhibition of LH and FSH secretion. As a result of disrupted LH secretion, it causes the growth and number of Leydig cells to decrease so that the production of the hormone testosterone decreases (Carolin et al., 2019).

The content of alkaloids in papaya leaves can cause a decrease in the motility of spermatozoa due to disruption of the process of spermatogenesis, spermatogonia in the process of mitosis and meiosis. Normally this process begins with type A spermatogonia undergoing mitosis resulting in stem cell renewal and type B spermatogonia continuing to differentiate. Furthermore, type B spermatogonia form haploid round spermatids through the process of meiosis. haploid round spermatids become motile and mature spermatozoa. Spermiogenesis will occur condensation formation, acrosome nucleus and cellular reorganization which includes the development of the tail of the spermatozoa. Sertoli cells mediate the process of spermiation, namely the cytoplasm is released from the spermatids and mature sperm is released into the lumen of the seminiferous tubules, this process is also influenced by endocrine hormone regulation. This alkaloid content can interfere with this process because it is estrogenic which can interfere with the spermiogenesis process (Wiryawan et al. 2016). Based on the above review, it can be concluded that the ethanol extract of papaya leaves (*Carica papaya* L.) can affect the histopathological picture of the testicles of young adult mice (*Mus musculus*).

Funding and Sponsorship

This research was supported by the Faculty of Medicine, Al-Azhar Islamic University which provided funding for this research.

Acknowledgement

We would like to thank the medical faculty of Al-Azhar Islamic University for providing grants to researchers to conduct this research.

Conflict of Interest

There is no conflict of interest and funding support without any commercial or financial relationship can be construed as a potential conflict of interest.

Author Contribution

In this study, Ida Ayu Made Mahayani contributed to the creation of ideas, Mr. Angga helped the research process and Mrs. Sukma assisted in reading histology slides.

References

- 1) Airaodion, A.I., Okoroukwu, V.N., Ogbuagu, E.O., Ekenjoku, J.A., Ogbuagu U., and Airaodion, E.O. (2019). Antifertility Effect of Ethanolic Leaf Extract of *Carica papaya* in Male Wistar Rats. *Merit Research Journal of Medicine and Medical Sciences*. [Online] 7(10), 374-381. Tersedia di: <http://www.meritresearchjournals.org/mms/index.htm> [Diunduh: 21 Januari 2022].
- 2) Amilah, S., Sukarjati, Rachmatin, D.P., and Masruroh. (2019). Leaf and Petiolle Extract of *Centella asiatica* Are Potensial for Antifertility and Antimicrobial Material. *Fol Med Indones*, [Online] 55(3), 188-197. Tersedia di <https://dx.doi.org/10.20473/fim.v55i3.15498> [Diunduh: 21 Januari 2022].
- 3) Ardiansyah, M. (2020). Keuntungan Usaha Budidaya Pepaya Calina IPB 9 di Kecamatan Panyabungan Barat Kabupaten Mandailing Natal Provinsi Sumatera Utara. *Jurnal Inovasi Penelitian*, [Online] 1(4), 799-812. Tersedia di : <https://doi.org/10.47492/jip.v1i4.149> [Diunduh: 3 Februari 2022].
- 4) Ashfahani, E.D., Wiratmini, N.I., and Sukmaningsih, A.A.S.A. (2010). Motilitas dan Viabilitas Spermatozoa Mencit (*Mus Musculus*) setelah Pemberian Ekstrak Temu Putih (*Curcuma zedoaria* (Breg.) Roscoe). *Jurnal Biologi*, [Online] 14(1), 20-23. Tersedia di: <http://doi: 10.24843/-jbiounu14105292> [Diunduh: 3 Februari 2022].
- 5) A'yun, Q., and Laily, A. N. (2015). Analisis Fitokimia Daun Pepaya (*Carica Papaya L.*) di Balai Penelitian Tanaman Aneka Kacang dan Umbi, Kendalpayak, Malang. *Prosiding Konservasi dan Pemanfaatan Sumber Daya Alam*. [Online] 134-137. Tersedia di : <https://media.neliti.com/media/publications/169805> [Diunduh: 17 Oktober 2020].
- 6) Carolin, B.T., Salni, and Nita, S. (2019). Pengaruh Ekstrak Bunga Kembang Sepatu (*Hibiscus Rosa-Sinensis* Linn.) terhadap Epididimis, Prostat dan Vesika Seminalis. *Biomedical Journal of Indonesia*, [Online] 1(5), 1-10. Tersedia di: <https://doi.org/10.32539/BJI.V511.7972> [Diunduh: 3 Februari 2022].
- 7) Delfita, R. (2014). Potensi Antifertilitas Ekstrak Teh Hitam Pada Mencit (*Mus musculus L.*) Jantan. *Jurnal Sainstek IAIN Batusangkar*, [Online] 6(2), 181-188. Tersedia di : <https://ojs.iainbatusangkar.ac.id>. [Diunduh: 19 Oktober 2022].

- 2020].
- 8) Dewanti, E., Viviandhari, D., Lonica, N., and Mutia Isnarningtyas, S. (2020). Efek Antifertilitas dari Ekstrak Daun Pepaya (*Carica Papaya L.*) pada Tikus Putih Jantan Galur Sprague Dawley. *Jurnal Jamu Indonesia*, [Online] 5(1), 9–15. Tersedia di: <https://doi.org/10.29244/jji.v5i1.182> [Diunduh: 19 Oktober 2020].
 - 9) Fatmawati, D., Isradji, I., and Yusuf, I. (2016). Kualitas Spermatozoa Mencit Balb / C Jantan Setelah Pemberian Ekstrak Buah Kepel (*S telechocarpus Burahol*) Sperm Quality of Male Balb / C Mice after Kepel (*Stelechocarpus burahol*) Fruit Extract Administration. *Jurnal Biologi*, [Online] 48(3), 155–159. Tersedia di: <https://journal.fk.unpad.ac.id> [Diunduh: 31 Oktober 2020].
 - 10) Fauzi'ah, L., and Wakidah, M. (2019). Extraction of Papaya Leaves (*Carica papaya L.*) Using Ultrasonic Cleaner. *Jurnal Ilmu-ilmu MIPA*, [Online] 19(1), 35–45. Tersedia di: <http://doi.org/10.20885/eksata.vol19.iss1.art4> [Diunduh: 2 Januari 2021].
 - 11) Hasanah, W., and Sukarjati. (2016). Pengaruh Pemberian Ekstrak Biji Pepaya (*Carica Papaya L.*) Dan Ekstrak Daun Mimba (*Azadirachta Indica A. Juss*) Dan Campuran Ekstrak Biji Pepaya Dan Ekstrak Daun Mimba Terhadap Kualitas Spermatozoa Mencit (*Mus Musculus*). Wahana. [Online] 67(2), 59–69. Tersedia di: <http://jurnal.unispabsy.ac.id> [Diunduh: 2 Januari 2021].
 - 12) Laili, N. (2018). Penurunan Pergerakan Spermatozoa Tikus Putih Jantan (*Rattus Norvegicus*) yang Diinduksi Ekstrak Etanol Daun Pepaya (*Carica Papaya L.*). *Jurnal Kesehatan Bakti Tunas Husada: Jurnal Ilmu-Ilmu Keperawatan, Analis Kesehatan Dan Farmasi*, [Online] 17(2), 390. Tersedia di: <https://doi.org/10.36465/jkbth.v17i2.265> [Diunduh: 03 Oktober 2020].
 - 13) Kasmeri, R., and Putri, A. (2020). Pengaruh Ekstrak Pedada Merah (*Sonneratia Careolaris L.*) Terhadap Jumlah Dan Morfologi Spermatozoa Mencit (*Mus Musculus L.*). *Jurnal Bioconcetta*. [Online] 6(1), 7-13. Tersedia di: <http://ejurnal.stikip-pgri-sumbar.ac.id> [Diunduh: 2 Januari 2021].
 - 14) Panuluh, S. M., Pradana, K. A., Duarsa, A. B. S., Muhajir, A., & Mubarak, A. S. (2022). STUDI LITERATUR: EFEKTIVITAS KANGORO MOTHER CARE (KMC) TERHADAP KENAIKAN DAN KESTABILAN SUHU TUBUH PADA BAYI BBLR. *Avicenna: Journal of Health Research*, 5(1).
 - 15) Ratri, P.R., and Andriani, M. (2020). Prospek Kontrasepsi Pria dalam Pengendalian Pertumbuhan Penduduk Melalui Pendekatan Molekuler. *Arteri: Jurnal Ilmu Kesehatan*. [Online] 1(2), 147–153. Tersedia di : <http://doi.org/10.37148/arteri.V1i2.53> [Diunduh: 10 November 2021].
 - 16) Syamsuddin, M.I., Turalaki, G.L.A., and Tendean, L.E.N. (2021). Pengaruh Pemberian Ekstrak Biji Pepaya (*Carica papaya L.*) terhadap Kualitas Sperma. *eBiomedik*, [Online] 9(1), 26-37. Tersedia di: <https://doi.org/10.35790/ebm.9.1.2021.31755> [Diunduh: 10 Oktober 2021].
 - 17) Wijayanti, D.N., Muslichah, S., Puspitasari, E. (2016). Pengaruh Ekstrak Metanol Biji Pepaya Tua dan Ekstrak Metanol Biji Pepaya Muda (*Carica Papaya Lin.*) Terhadap Kualitas dan Kuantitas Spermatozoa Tikus Jantan (*Rattus nervegicus*). *e-Jurnal Pustaka Kesehatan*, [Online] 4(3), 495-500. Tersedia di: <http://jurnal.unej.ac.id>. [Diunduh: 03 Maret 2022].
 - 18) Widiastuti, R., Sudiman, J., Tyagita, Syamsunarno, M.R.A.A., and Sumarsono, S.H. (2018). Oral Administration of Cogongrass (*Imperata cylindrica L.*) Root Ethanol-Extract cause Mouse Epididymal Sperm

- Abdnormality. *Jurnal Veteriner*, [Online] 19(3), 351-358. Tersedia di: <http://ojs.unud.ac.id/index.php/jvet> [Diunduh: 3 Februari 2022].
- 19) Widiyanto, A., Atmojo, J. T., & Handayani, R. T. (2021). Trend Analysis of the Mobile Health COVID-19 Application As A Preventive Strategy in the Era of COVID-19 Pandemic in Surakarta. *Journal of Health Promotion and Behavior*, 6(02), 104-111.
 - 20) Widiyanto, A., Murti, B., & Soemanto, R. B. (2018). Multilevel analysis on the Socio-Cultural, lifestyle factors, and school environment on the risk of overweight in adolescents, Karanganyar district, central Java. *Journal of Epidemiology and Public Health*, 3(1), 94-104.
 - 21) Widnyanjaya, A.A.G.F., Satyarsa, A.B.S., Dharmadi, N.L.G.A.C., Sari, M.M.M., Laveda, X., and Satriyasa, B.K. (2020). Efek Pemberian Biji Pepaya (*Carica papaya* Linn) Terhadap Gambaran Histopatologi Testis pada Mencit (*Mus musculus*) Jantan. *Essence of Scientific Medical Journal*, [Online] 18(2), 11-15. Tersedia di: <http://ojs.unud.ac.id/index.php/essential/index> [Diunduh: 3 Februari 2022].
 - 22) Wiryawan, R. A., I'tishom, R. and Purwaningsih, S. 2016. Papaya Seed Extract Lowers Sperm Concentrations, Motility and Viability in Male Mice. *Folia Medica Indonesiana*. [Online] (4), 252. Tersedia di: doi: 10.20473/fmi.v5i1i4.2855. [Diunduh: 1 September 2021].
 - 23) Wikayanti, R.A., and Panjaitan, A.P. (2019). Pengaruh Pemberian Kedelai Terhadap Reproduksi. *Jurnal Perawatan Penelitian Profesional*. [Online] 1(1), 240-247. Tersedia di: <https://doi.org/10.37287/jppp.v1i1.18> [Diunduh: 21 Januari 2022].
 - 24) Damayanti, I. A. M., Indrayoni, P., Antari, N. W. S., & Padmiswari, A. A. I. M. (2021). Effectiveness of Averrhoa bilimbi leaf extract on spermatogenic cells of mice (*Mus Musculus* L.) hyperglycemia. *International Journal of Health & Medical Sciences*, 4(2), 273-279. <https://doi.org/10.21744/ijhms.v4n2.1747>
 - 25) Suryasa, I. W., Rodríguez-Gámez, M., & Koldoris, T. (2022). Post-pandemic health and its sustainability: Educational situation. *International Journal of Health Sciences*, 6(1), i-v. <https://doi.org/10.53730/ijhs.v6n1.5949>